

## Yolk Sac Tumor in Pregnancy: A Case Report

Dr Mutum Matouleibi Chanu<sup>1</sup> Dr Bandana Pradhan<sup>2</sup> Dr Nuonenuo Teherse<sup>3</sup>

Dr L.Trinity Meitei<sup>4</sup> Prof N.Nabakishore Singh<sup>5</sup>

<sup>1,2,3</sup>, Pgt, Senior Resident<sup>4</sup>, Hod And Professor<sup>5</sup>.

---

**Abstract:** Yolk sac tumor amounts to 2-4% of cancer in women of reproductive age. These arise from germ cell of ovary, which is rare when compared to other germ cell tumor, but are highly malignant. When associated with pregnancy which is very rare, leads significant mortality and morbidity to both mother and baby due to limited investigation and therapeutic options. Here we present one such case where a 20-year-old lady with 30weeks pregnancy was diagnosed with yolk sac tumour and managed successfully.

---

### I. Introduction

Yolk sac tumor, previously known as endodermal sinus tumor is a malignant tumor arising from germ cell of ovary, which shows differentiation into primitive endodermal structures. It constitutes 1-2% of all ovarian malignancies and third most common type of ovarian malignancies. Before introduction of combination chemotherapy, mortality rate was very high, reaching up to 100% within three years of diagnosis. Introduction of vincristine, dactinomycin and cyclophosphamide regimen has increased the survival rate up to 94%. But when this tumor is encountered in pregnancy, mortality and morbidity of both mother and baby increases due to technical, ethical and religious reasons.

### II. Case Report

A 20-year-old primigravida with 30week pregnancy presented to obstetric OPD with complaint of shortness of breath and cough for 2weeks. On examination she was afebrile with no dehydration, no cyanosis and no pallor. Bilateral pitting pedal edema was noted. Decreased breath sounds on right basal region of chest also noted. Pulse rate was 110/min with blood pressure of 120/80mm of Hg. Abdomen was tense with full flanks. Fluid thrill and shifting dullness were positive. Abdominal girth was 100cm at the umbilicus and symphysis fundal height was 34.

On pervaginal examination, OS was closed with high and pulled up cervix. Mobility of cervix was restricted in all direction. A mass with smooth surface and firm to hard consistency was occupying the pouch of Douglas, which was non-tender with no involvement of vaginal mucosa. The same mass was felt in per rectal examination with similar features.

Complete blood count showed total leucocyte count of 14,400 with neutrophilia (84 %), hypoproteinemia with hypoalbuminemia was found in liver function test. Other parameters of liver function tests including enzymes and kidney function test were normal.

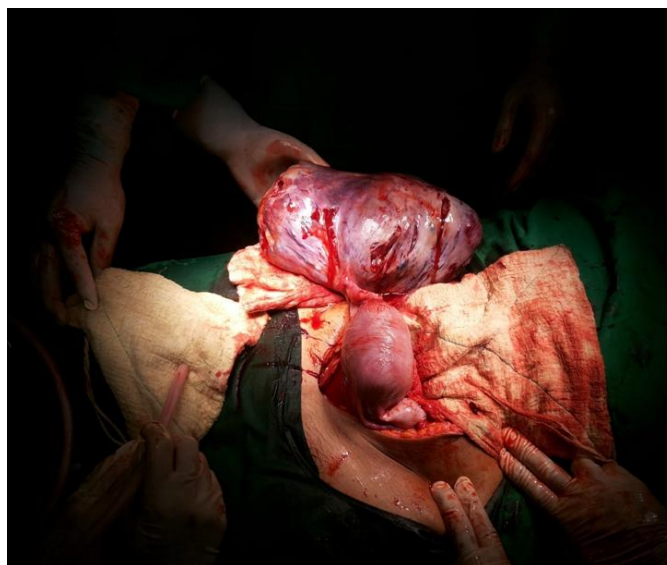
A single live fetus with 27-week pregnancy in cephalic presentation was found on ultrasonography. Fetal heart sounds were 136 per minute and placenta was posterior in location. Amniotic fluid was adequate in volume. A large heterogeneous mass measuring 20X10 cm was noticed in posterior wall of lower segment of uterus with multiple cystic lesion and increased vascularity.

MRI showed preterm pregnancy with large complex right adnexal cystic mass (19X12cm in size) suggestive of right ovarian cystic neoplasm. Hepatomegaly, ascites and right pleural effusion also noted.

Serum tumor markers were ordered, LDH was increased – 1087U/L (normal range 300-680) and AFP was also increased – 694 IU/L. Beta HCG was normal.

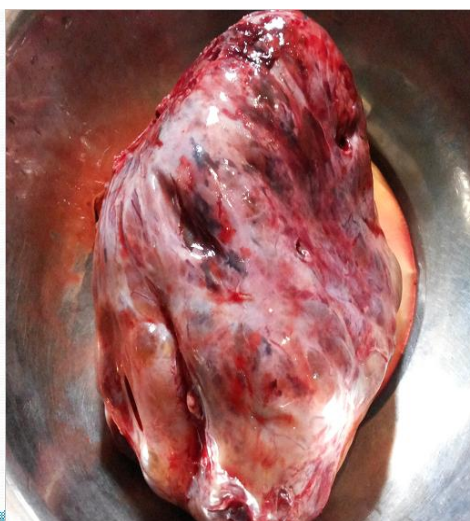After thorough discussion with the patient and her relatives, exploratory laparotomy and lower segment cesarean section with right salphingo oophorectomy was planned at 32weeks of gestation. 2 dose of steroid was given at 24-hour interval. A healthy female baby weighing 1.9 kg was delivered and admitted to NICU. The tumor excised showed multiple cystic and firm solid lesion with no exfoliative growth (figure 1,2). The histopathology of the specimen showed yolk sac tumor of right ovary with schiller duval body (figure 3). Sample sent from left ovary, omentum and ascetic fluid were normal.

The mother was transferred to oncology department where she received 4 cycles of chemotherapy with Bleomycin, Etoposide and Cisplatin after 21 days. The general condition of the patient improved with repeat serum tumor marker coming back to normal range. Both baby and mother are under regular follow-up and healthy after 18 months of surgery.



### Gross appearance

-multiple cystic and firm solid areas  
No exfoliative growth present on surface  
no rupture of cyst



### III. Discussion

Yolk sac tumour, a malignant tumour arising from the germ cells of ovary are more commonly seen in children and young adults, median age being 19 years. These are rarely seen in women after menopause. The mode of presentation being abdominal distention, pain abdomen and sometimes mass per abdomen. Most of the times these tumors are detected late in pregnant women as the symptoms are obscured due to physiological changes of pregnancy. The diagnosis of yolk cell tumor during pregnancy requires high degree of suspicion. Increased serum tumor marker like alpha feto-protein, beta HCG and LDH will help in making diagnosis and assessing recurrence after treatment.

Ultrasound and Magnetic Resonance Imaging are the radiological investigations available to diagnose and stage the tumour during pregnancy. Once diagnosed treatment is challenging and depends upon multi factors like parity, duration of pregnancy, stage of tumor, general condition of patient, it is often possible to continue the pregnancy by debulking surgeries where tumor is resected completely. Since more than 50% of stage1 tumor have micro-metastasis, tumor must be resected as much as possible. Prior to the availability of combination chemotherapy, mortality was very high even for stage 1 disease. Introduction of combination chemotherapy with vincristine, dactinomycin and cyclophosphamide radically changed the mortality rate. Recently introduced protocol like Bleomycin, Etoposide and Cysplatin, have further increased the survival rate.

Since incidence of yolk sac tumour during pregnancy is very rare, no literature of properly conducted studies is available. Very few case reports could be found on internet where tumour was diagnosed in 3<sup>rd</sup> trimester and baby was delivered normally and tumour treated later. Luciano Souza Viana et al. published a case where yolk sac tumor was diagnosed in 20-year-old lady with 14week pregnancy; pregnancy was preserved with

3 cycles of chemotherapy given with Cisplatin and Etoposide omitting Bleomycin. It is advisable to wait for a minimum of 21 days after chemotherapy to deliver a baby to avoid cytopenia in baby.

#### **IV. Conclusion**

Yolk sac tumour is a rare tumor encountered in day today practice even rarer when associated with pregnancy. Management of such cases is a challenge for the surgeon due to limited diagnostic and therapeutic tools and lack of well-accepted protocol for management of such cases. Religious, ethical and economic factor should be considered along with thorough discussion with the patient and her relatives regarding the risks and hazards of the disease, investigations and the treatment options available.

**Consent:** Well-informed written consent was taken from the patient for publication of her case as a case report.

#### **References**

- [1]. Successful management of endodermal sinus tumor of the ovary associated with pregnancy. Shimizu Y, Komiyama S, Kobayashi T, Nakata K, Iida T. Department of Obstetrics and Gynecology, Saiseikai-Utsunomiya Hospital, Utsunomiya-shi, Tochigi, Japan.
- [2]. Jung SE, Lee JM, Rha SE et-al. CT and MR imaging of ovarian tumors with emphasis on differential diagnosis. *Radiographics*. 22 (6): 1305-25. doi:10.1148/rg.226025033 - Pubmed citation
- [3]. Yamaoka T, Togashi K, Koyama T et-al. Yolk sac tumor of the ovary: radiologic-pathologic correlation in four cases. *J Comput Assist Tomogr*. 24(4): 605-9. *J Comput Assist Tomogr (link)* - Pubmed citation
- [4]. Sustained complete remission in a patient with platinum-resistant ovarian yolk sac tumor. Jeyakumar A, Chalas E, Hindenburg A. Oncology/Hematology Division, Department of Medicine, Winthrop University Hospital, Mineola, New York 11501, USA.
- [5]. Prognostic factors of patients with yolk sac tumors of the ovary. Nawa A, Obata N, Kikkawa F, Kawai M, Nagasaka T, Goto S, Nishimori K, Nakashima N. Department of Obstetrics and Gynecology, Nagoya University School of Medicine, Japan.