

## Giant Porokeratosis of Mibelli with Squamous Cell Carcinomas

Vani. T, Ramamohan. Ch, Nageswaramma. S, Swarnakumari. G, V

Sivaramakrishna. T , Rajunaidu. D.S, Swapna K, Ramadas N

Department of Dermatology Venereology Leprology, Department of Radiotherapy  
Guntur medical college, Guntur.

**Abstract:** Porokeratosis is a specific disorder of keratinization that has five major clinical types and shows a characteristic cornoid lamella on histopathology. Giant porokeratosis is considered to be a morphological variant of porokeratosis of mibelli. Malignant degeneration has been described in all forms of porokeratosis but highest risk is associated with linear and giant porokeratosis . We report a case of giant porokeratosis with squamous cell carcinomas in 55yr old female patient. To the best of our knowledge this is the largest giant porokeratosis ever reported measuring 62×48cm with two large squamous cell carcinomas.

**Keywords:** Cornoid lamellae, Giant porokeratosis of Mibelli, Malignant degeneration, Squamous cell carcinoma, Ultraviolet Radiation.

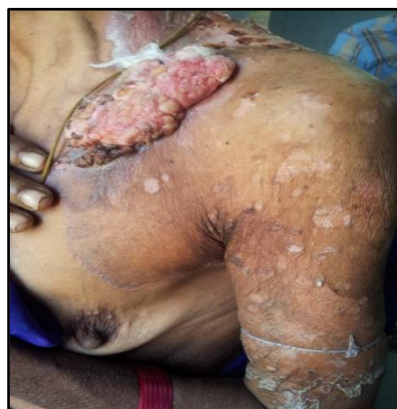### I. Introduction

Porokeratosis is a rare clonal disorder of keratinization, characterized clinically by atrophic patches with a distinct ridge like border. The border has a histologic hall mark in the form of cornoid lamella - a parakeratotic column. Various morphologic forms of porokeratosis have been described. Five major variants among them are Porokeratosis of Mibelli(PM), Disseminated superficial actinic porokeratosis(DSAP), Linear porokeratosis(LP), Porokeratosis Palmaris et plantaris disseminate(PPPD), & Punctate porokeratosis(PP). There are other variants like giant porokeratosis, hyperkeratotic, verrucous, nodular, punched out & reticulate type.<sup>10</sup> Malignant transformation into squamous, bowenoid or basal cell carcinoma has been described in all forms of porokeratosis with the highest risk for the linear form followed by giant porokeratosis. Giant porokeratosis is considered to be a morphological variant of porokeratosis of Mibelli with a diameter of upto 20cm.

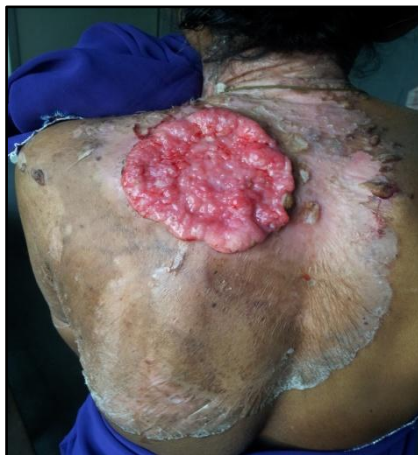### II. Case Report

A 55 year old female from a remote village of Andhra Pradesh, India presented with hypo and hyperpigmented plaque on left side of the trunk (chest and back) and shoulder of 30 years duration. She is an agriculture worker. The lesion started as a papule on upper back which was asymptomatic. The lesion gradually increased in size and extended on to the left shoulder and chest. There is no history of taking any treatment.

She developed two ulcerated growths (cauliflower like as described by patient), one on the back of two years duration and the other on the chest of one year duration on previously existing lesion. Patient developed mild irritation and pain for which she took some symptomatic treatment. There is no similar complaint in the family. Cutaneous examination revealed a plaque of size 62×48 cms on the back extending up to the lower end of the rib cage on left side crossing the midline, in front extending on to the breast and left arm up to the elbow with central atrophy and well demarcated hyperkeratotic border with a groove in centre. Two ulcerated masses are present of size 12×6 cms on left side of chest and 14×10 cms in upper back . [“Fig.” 1,2]



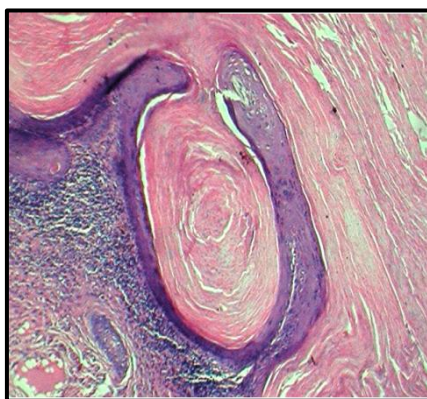
“Fig” 1 : annular plaque with keratotic border and atrophic centre with squamous cell carcinoma on chest and upper arm



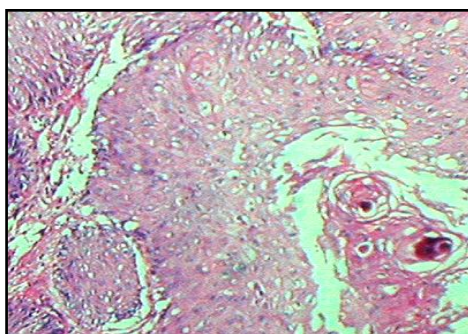
**“Fig” 2:** cauliflower like growth on the back on large atrophic plaque with hyperkeratotic border

Routine blood tests, X-ray chest and ultrasound abdomen were unremarkable. Elisa test for HIV was non reactive.

Histopathology from the border of plaque showed hyperkeratosis and a column of parakeratotic cells - characteristic cornoid lamellae in epidermal invagination and absent granular layer below it which is consistent with porokeratosis of Mibelli. [“Fig” 3] Upper dermis showed chronic inflammatory cell infiltrate. Histopathology of ulcerated masses revealed well differentiated squamous cell carcinoma with characteristic malignant pearls. [“Fig” 4]



**“fig” 3:** hyperkeratosis, parakeratosis, cornoid lamella in the epidermal invagination and absent granular layer below the cornoid lamella



**“Fig” 4:** well differentiated horn pearls

After confirming the diagnosis of giant porokeratosis with squamous cell carcinoma patient was referred to radiotherapy department for the management of squamous cell carcinoma.

### **III. Discussion**

Porokeratosis is a rare disorder of keratinization with autosomal dominant mode of inheritance with sporadic cases known to occur frequently. There is a predilection for the male sex. Various risk factors involved in the development of porokeratosis include genetic inheritance,<sup>11</sup> immunosuppression,<sup>(11,12)</sup> UV radiation and

sun exposure.<sup>11</sup> It was first described by Mibelli in 1893 based on the assumption that the columns of parakeratosis emerge from the ostia of eccrine ducts.<sup>2</sup> Porokeratosis is clinically characterized by asymptomatic or mild pruritic keratotic papules surrounded by a raised keratotic border. Among the five classical clinical variants, Porokeratosis of Mibelli has the characteristic morphological features as annular plaques with central atrophy and elevated keratotic borders containing a longitudinal furrow. Giant porokeratosis is considered to be a morphological variant of porokeratosis of Mibelli by some authors while others consider it as a distinct entity. The lesions may vary from 10 to 20cm in diameter & the hyperkeratotic walls raised greater than 1cm.<sup>4</sup> Malignancy although rare, has been reported in almost all forms of porokeratosis. The factors associated with a higher risk of malignant transformation include; duration & size of the lesions, age of the patient, large lesions on the extremity, linear type<sup>13</sup> & multiple patterns of porokeratosis.<sup>7</sup>

The risk for malignant transformation of porokeratosis of Mibelli has been reported to be 7.5 to 11%.<sup>7</sup> Squamous cell carcinoma is the most commonly reported malignancy in porokeratosis, and other malignancies reported are Bowen's disease, Basal cell carcinoma and Diffuse Large B cell Lymphoma.<sup>5</sup>

In this case, patient had some potential risk factors such as her age, long duration of the lesion, large size, sun exposure (as she is an agricultural worker) all of which strongly justify the conversion to squamous cell carcinoma.

Several large lesions of Porokeratosis of Mibelli have been reported as giant ones – 10 cms diameter,<sup>7</sup> 13×12 cms;<sup>4</sup> 14×10 cms<sup>3</sup>, 18×13 cms<sup>6</sup>; 25×50 cms<sup>1</sup>. Our presenting case measured 62×48 cms, largest giant porokeratosis ever reported to the best of our knowledge with large squamous cell carcinomas which is extremely rare.

#### IV. Conclusion

We conclude that the patients with long standing and large lesions of porokeratosis have high risk of malignant transformation hence should be monitored regularly to detect malignant changes.

#### References

- [1]. Ehsani AH, Shakoei S, Ranjabar M. Giant Porokeratosis of Mibelli with Squamous Cell Carcinoma. *Indian J Dermatology Venereology Leprology* 2014; 80: 96-7
- [2]. Rifaioglu EN, Ozyalvacli G. Follicular Porokeratosis at Alae nasi; A case report and short review of literature. *Indian J Dermatology* 2014; 59: 398-400
- [3]. Mohanan Saritha, Rashmi Kumari, Devinder Thappa, Nachiappa G. Rajesh, Surendra Kumar Verma. Benign giant cutaneous horn formed by giant Porokeratosis of Mibelli with dysplasia. *Indian J Dermatology Venereology Leprology* 2013; 79: 433-35
- [4]. Ray Chaudary T, Valsamma DP. Giant Porokeratosis. *Indian J Dermatology Venereology Leprology* 2011; 77: 601-2
- [5]. Sarma N, Boler AK, Bhattacharya SR. Familial Disseminated plaque type Porokeratosis with multiple horns and Squamous cell carcinoma involving anal skin; *Indian J Dermatology Venereology Leprology* 2009; 75: 551
- [6]. Ma DL, Vano-Galvan S. Squamous cell carcinoma arising from Giant Porokeratosis. *Dermatol. Surg* 2009; 35: 1999-2000
- [7]. Senguptha S, Das JK, Gangopadhyay. A multicentric squamous cell carcinoma over lesions of Porokeratosis Pamparis et plantaris disseminate an giant Porokeratosis. *Indian J Dermatology Venereology Leprology* 2005; 71: 414-6
- [8]. Vasudevan B, Chatterjee M, Grewal R, Rana V, Lodha N. A case of disseminated superficial Porokeratosis associated with giant Porokeratosis in pregnancy. *Indian J Dermatol* 2014; 59: 492-4.
- [9]. Pavithran K. Disorders of keratinisation. In: Valia RG, Valia AR, editors. *IADVLTxtbook and Atlas of Dermatology*. 2<sup>nd</sup> ed. Mumbai: Balani Publishing house; 2001. P 805-6.
- [10]. Palleschi GM, Torchia D. Porokeratosis of Mibelli and superficial disseminated porokeratosis. *J Cutan Pathol* 2008; 35: 253-5.
- [11]. Odeyinde S, Belcher H. Isolated single porokeratosis mibelli: An unusual case. *Dermatol online J* 2012; 18:13
- [12]. Perez-Crespo M., Betloch I, Lucas -Costa A, Banuls-Roca J, Niveiro de Jaime M, Mataix J. Unusual evolution of giant porokeratosis developing in two renal transplant patients. *Int J Dermatol* 2008;47:59-60
- [13]. Sasson M, Krain AD. Porokeratosis and cutaneous malignancy. A review. *Dermatol Surg* 1996;22:339-42.