

## Post traumatic benign nerve sheath tumour in supra-patellar region

Dr.P.Anil Babu<sup>1</sup>, Dr.G.Vara Prasad<sup>2</sup>

<sup>1</sup>( Assistant Prof. of Orthopaedics , Guntur Medical College , Govt. Gen. Hospital, Guntur,AP, India )

<sup>2</sup>(Associate Prof. of Orthopaedics , Guntur Medical College , Govt. Gen. Hospital, Guntur, AP, India )

---

**Abstract :** The principal structural component of peripheral nerve is the nerve fibre consisting of an axon with its Schwann cells and myelin sheath. The two main responses of peripheral nerve to injury are determined by the target of the injury: either the Schwann cell or the axon. Peripheral nerve is susceptible to the same wide range of categories of disease (inflammatory, traumatic, metabolic, toxic, genetic, neoplastic) as are other tissues. The pattern of disease, however, reflects the unique structure and function of nerve derangement. Peripheral nerves are injured in the course of trauma. Lacerations result from cutting injuries and can complicate fractures when a sharp fragment of bone lacerates the nerve. Avulsions occur when tension is applied to a peripheral nerve, often as the result of a force applied to one of the limbs. Regeneration of peripheral nerve axons following these types of injuries does occur, albeit slowly. Regrowth may be complicated by discontinuity between the proximal and distal portions of the nerve sheath as well as by the misalignment of individual fascicles. Axons, even in the absence of correctly positioned distal segments, may continue to grow, resulting in a mass of tangled axonal processes known as a traumatic neuroma (pseudoneuroma or amputation neuroma). Within this mass, small bundles of axons appear randomly oriented; each, however, is surrounded by organized layers containing Schwann cells, fibroblasts, and perineurial cells. The case we are reporting is in the backdrop of a blunt trauma followed by slow onset of a soft swelling in the supra patellar region to involve the nerve lesions occurring in the post traumatic period.

**Keyword:** Post traumatic benign nerve sheath tumour

---

### I. INTRODUCTION

Peripheral nerves are injured in the course of trauma. *Lacerations* result from cutting injuries and can complicate fractures when a sharp fragment of bone lacerates the nerve. *Avulsions* occur when tension is applied to a peripheral nerve, often as the result of a force applied to one end of the limbs.

#### Case report:

A forty year old female presented with a swelling in the supra patellar region of the left thigh. She is an agricultural labourer. She presented to the OPD with pain over left knee & lower end of left thigh since two years, and swelling over the lower end left thigh since one year. Stiffness of left knee experienced since one year.

Her present complaint started with pain over left knee and lower part of front of left thigh two years ago after a trivial injury with a blunt force. Pain is dull aching in nature, pain is intermittent, which is aggravated by activity, relieved by taking rest with no radiation of pain.

She noticed swelling one year back associated with pain over front of lower part of left thigh which is slowly increasing in size and attained present size. Stiffness of left knee joint since one year, unable to flex knee joint beyond 90 degrees and unable to sit cross legged and squat.

There is no history of pain in back & left hip, fever, night cries, loss of weight . Following trauma there was no history of massages.

**Clinical examination :** She is obese, Vitals are within normal limits. Local examination: There is a 7x5 cms swelling over supra patellar region of left thigh, skin over the swelling is normal, no sinuses , scars or engorged veins. On palpation, no local rise of temperature, tenderness over the swelling, with edges that are well defined, mobile horizontally, soft to firm in consistency, not fluctuant, not reducible , not compressible, not translucent, not pulsatile. Skin over swelling is pinchable. Size of the swelling decreased by contraction of muscles. No palpable lymphnodes.

She is treated by General practitioner with painkillers and three doses of intra articular steroid injections into the left knee initially from past 2years.

**Investigations** : the patient is investigated with blood investigations which are within normal limits. Radiographs revealed nothing abnormal in and around the knee joint. “Fig.1”. Ultra Sonogram detected enlarged irregular hypoechoic lesion of 4.4x1.6 cms size at tendinous insertion just above the patella with possibilities of ?Neoplastic, ?inflammatory lesion. “Fig 2”.

**Treatment:** Under spinal anaesthesia, under tourniquet control, lateral parapatellar skin incision was given. After separation of soft tissue, mass of 6x4cm was identified, and excised.“Fig. 3&4.” The specimen collected was sent for Histo Pathological Examination, which diagnosed the swelling as a Benign Nerve Sheath lesion. “Fig 5.”

**Discussion:** Peripheral nerves can be injured in the course of trauma[1]. Lacerations result from cutting injuries and can complicate fractures when a sharp fragment of bone lacerates the nerve. *Avulsions* occur when tension is applied to a peripheral nerve, often as the result of a force applied to one of the limbs. Blunt injuries with shear forces can lead to triggered inflammatory response in the nerve sheath[ 2] . These are the scenarios where a nerve injury may be missed or misdiagnosed for a longer periods [3]. Regeneration of peripheral nerve axons following these types of injuries does occur, albeit slowly. Regrowth may be complicated by discontinuity between the proximal and distal portions of the nerve sheath as well as by the misalignment of individual fascicles. The response of the peripheral nervous system to injury needs to be understood to suspect the injuries and their long term effects to minimize the anxiety to the patient [4]. Axons, even in the absence of correctly positioned distal segments, may continue to grow, resulting in a mass of tangled axonal processes known as a *traumatic neuroma (pseudoneuroma or amputation neuroma)*. Within this mass, small bundles of axons appear randomly oriented; each, however, is surrounded by organized layers containing Schwann cells, fibroblasts, and perineurial cells. The delay in diagnosis can be avoided if proper investigations are done at proper time so that better outcome is given in a short span of time[5]. The surgical intervention can be planned if slow inflammatory response builds up anxiety in the patient for treating the localized inflammatory response.

## II. FIGURES AND TABLES

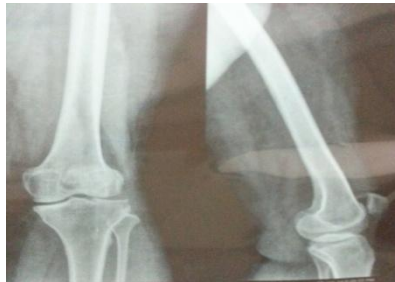

Fig.1: Radiograph of the Knee joint with thigh AP,Lat views

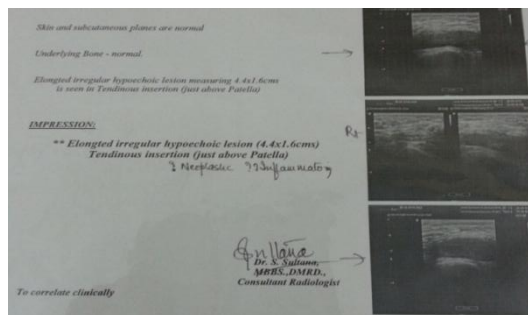


Fig.2 : Ultra sonogram of Knee joint with swelling in supra patellar region

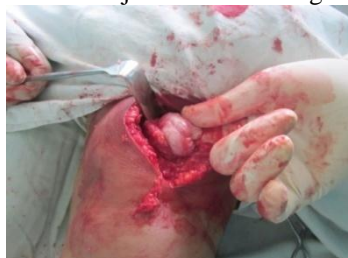

Fig.3: Gross intra operative appearance of the Tumor

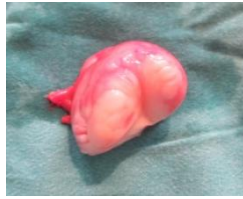

Fig.4: Gross appearance of the tumor after excision

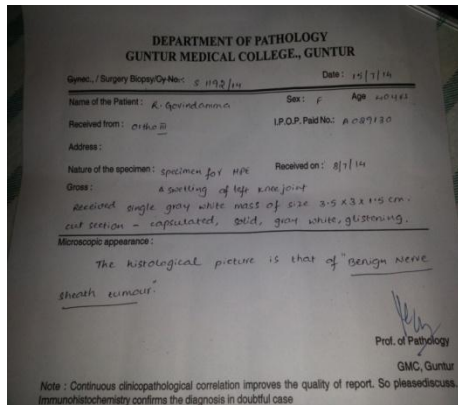


Fig.5: Histo pathology report of the specimen

### III. CONCLUSION

The nerve sheath tumor was presenting like a soft swelling in the supra patellar region otherwise a common site for swellings arising from the joint cavity or the collection in the joint. Blunt trauma triggered the nerve sheath to have an insidious inflammatory response presenting as a swelling close the joint. Peripheral nerve sheath tumors should be considered for blunt trauma, avulsion injuries which present with slow growing, less symptomatic swellings.

### ACKNOWLEDGEMENTS

Dr.K.Kishore Kumar M.S(Ortho.),Dr.K.Veeranjaneya Naik M.S(Ortho.)

### REFERENCES

- [1]. Steed MB. Peripheral nerve response to injury *Atlas Oral Maxillofac Surg Clin North Am.* 2011 Mar;19(1):1-13. doi: 10.1016/j.cxom.2010.11.001.
- [2]. Erwtaman AS<sup>1</sup>, Balach T. Clinical evaluation and management of benign soft tissue tumors of the extremities. *Cancer Treat Res.* 2014;162:171-202. doi: 10.1007/978-3-319-07323-1\_9.
- [3]. Hung EH, Griffith JF. Pitfalls in ultrasonography of soft tissue *Usg Semin Musculoskelet Radiol.* 2014 Feb;18(1):79-85. doi: 10.1055/s-0034-1365837. *Epub* 2014 Feb 10. tumors.
- [4]. Rigoard P<sup>1</sup>, Lapiere F. *Neurochirurgie. [Review of the peripheral nerve].* 2009 Oct;55(4-5):360-74. doi: 10.1016/j.neuchi.2009.08.156. *Epub* 2009 Sep
- [5]. Nawabi DH<sup>1</sup>, Sinisi M. Schwannoma of the posterior tibial nerve: the problem of delay in diagnosis. *J Bone Joint Surg Br.* 2007 Jun;89(6):814-6.