

Magnetic Over Denture: Bidding Adieu to Clasped Removable Partial Denture

Dr. Kurien Varghese¹, Dr. Kulangara Balakrishnan Prasad², Dr. Hassan Nehas³,
Dr. Rajaram Anuram⁴

¹ (Professor and Head, Department Of Prosthodontics, Azeezia College of Dental Science and Research Centre, Kerala, India)

^{2,3,4} (Post graduate student, Department Of Prosthodontics, Azeezia College of Dental Science and Research Centre, Kerala, India)

Abstract: Magnets have been used in prosthodontics for many years, but success has been limited because of their susceptibility to corrosion by the saliva and their retentive force is weak relative to the initial retention offered by mechanical attachments. More recently, magnets have been made from alloys of rare earth elements samarium and neodymium, which provide stronger magnetic force per unit size. In addition, a new generation laser welded containers has improved protection from salivary corrosion. The current resurgence of interest in this type of attachment appears justified because, unlike mechanical attachments, magnets have potential for unlimited durability and superior to mechanical ball or bar attachments for the retention of removable prostheses on implants. As the magnets can be manufactured in smaller dimensions, it can be used as retentive component in removable partial denture for rehabilitation in the esthetic zone, obturators, maxillofacial prosthesis and implant over dentures. The present article describe the esthetic rehabilitation of partially edentulous gummy smile patient with the help of magnetic overdenture.

Keywords: Magnet; overdenture, esthetic zone, keeper holder

I. Introduction

Retention, stability and clasp attachments of partial dentures in esthetic zone have been a continuing problem for dentists in clinical practice. There always a group of patients for whom conventional prosthodontic techniques have been inadequate to fulfill their satisfaction. In an attempt to alleviate their problems, a variety of materials and methods have been tried such as springs, esthetic clasp, adhesives, attachments, implants and magnets.

As a mature retentive technique and a better alternative to conventional methods, magnetic attachments are applied in various types of prosthesis. Magnet retained overdenture is one such method which fulfills dentist and patient needs. This innovative method was initiated way back from 1950 with the invention of Alnico bar magnets and later on progressed with the introduction of Platinum-Cobalt, Cobalt-Samarium [1,2]. Recently introduced Neodymium-iron-Boron magnets (Fe14Nd2B) provide stronger magnetic force per unit size than the earlier open field aluminum nickel cobalt magnets which are susceptible to corrosion by the saliva and provide weak retentive force [3,4]. Magnetic assembly consists of magnet enclosed in laser welded stainless steel and coping with a keeper on remaining tooth structure. Holder is laser welded to the edge of keeper [Figure 1]. Even though they are smaller in dimension and have excellent retentive force. Conventional over denture placement involves embedding the magnetic assembly in the denture base and inserting its corresponding keeper into the abutment root. The magnetic assembly holds the keeper with a retentive force [5,6]. This clinical report describes the fabrication of maxillary cast partial denture retained by closed field magnetic assembly for rehabilitation in esthetic zone.

II. Case Report

A 49 years old female patient reported to Department of Prosthodontics at Azeezia College of Dental Science And Research, Kollam with a chief complaint of missing teeth in maxilla. Intraoral evaluation revealed partially edentulous maxillary arch. She had a gummy smile and Missing teeth are 12, 14,15,16,22,24,25,26. Maxillary arch was classified as Kennedy's class III modification 1 [Figure 2]. Remaining teeth in the maxilla and all teeth in mandibular arch were periodontally sound. Patient was made aware of the clinical condition and was willing to preserve the remaining teeth. She was not willing for any surgical intervention like implant prosthesis. Study cast was made and surveyed. A prominent tissue undercut was observed buccal to 13 and 23. Gummy smile and tissue undercut limits the use of direct retainers like 'I' bar clasp assembly which brings an unesthetic appearance. Treatment plan was to do an intentional root canal treatment maxillary right and left canine to accommodate post along with the magnetic assembly (MAGFIT DX.)

2.1. Clinical Procedure

2.1.1 Endodontic treatment and abutment teeth preparation

Abutment teeth (13 and 23) were endodontically treated and prepared with diamond rotary instruments (Shofu, Kyoto, Japan), producing a chamfer margin and reduced slightly above the gingival margin (2 mm), followed by removal of two thirds of the root canal filling material with a rotary drill instrument (Peaso reamer; Dentsply,) to prepare the post space to accommodate the post along with the keeper [Figure 3].

2.1.2. Mandibular abutment teeth impression

Gingival retraction (Ultrapak cord#000, USA) followed by full arch impression with polyvinyl siloxane impression materials (Aquasil, Dentsply International Inc, USA) to record the margin area and post space was successfully made and definitive cast [Ultrarock, type IV dental stone, India] was fabricated.[Figure 4].

1.2. Laboratory Procedure

2.2.1 Wax Up and Attachment of keeper

Indirect inlay wax (Kerr Co, Washington D.C, USA) was used to make impression of post space to fabricate the post and 0.5 mm inlay wax was kept for the placement of keepers on root teeth. The keeper has a flat shape with an attractive face on one side and a dimple face on the other place. Attractive side was kept facing up on the wax up. All the keepers were placed parallel to the occlusal plane ensured by the surveying procedure. Cast bonded keeper method was used to attach the keepers on the abutment teeth. Sprue wax attached to the wax up unit and casting was performed for all root caps.[Figure 5]

2.2.2. Setting of root caps, rest preparation and definite impression of maxillary arch

All root caps were cemented on the roots with glass ionomer cement (GC Co, Tokyo, Japan). After cementing the root caps, cingulum rest on 11 and 21, occlusal rest on 17 and 27 was done. Final impression was made with polyvinyl siloxane impression materials [Figure 6] and definitive cast was poured.

2.2.3. Frame work try in and occlusal registration

Designing of the cast partial denture and casting of metal frame work was done. Frame work try in was carried out and checked for fit [Figure 7].Occlusal rim were fabricated on metal frame work. The occlusal registration was done and transferred to Hanua wide view articulator. Teeth arrangement and try in were completed on waxed denture and processed [Figure 8,9,10]. All interceptive occlusal contacts were eliminated before fixing the magnetic assembly.

2.2.4. Placement of magnetic assembly

All magnets (Magfit; Aichi Steel Corp.) were kept on the top of keeper so as to coincide with both central axes. The tissue surface of cast partial denture which contains the cavity corresponding to the denture magnet was slightly enlarged and undercut created with inverted cone bur to freely accommodate the magnet. Denture magnets were placed facing the root magnet. Autopolymerising acrylic resin (DPI-RR Cold Cure) was mixed and placed into the cavity and cast partial denture inserted into patient's mouth and patient asked to occlude with minimal force. Partial denture was later removed from mouth, excess acrylic flash were removed [Figure 11]. The occlusion was checked to remove interceptive occlusal contacts. Finally finished and polished prosthesis was inserted into patient's mouth. Regular post insertion instructions and advises were given to the patient [Figure 12].

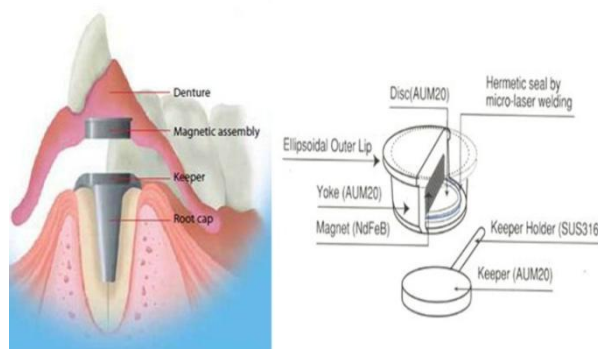


Fig 1: Magnet assembly and parts.

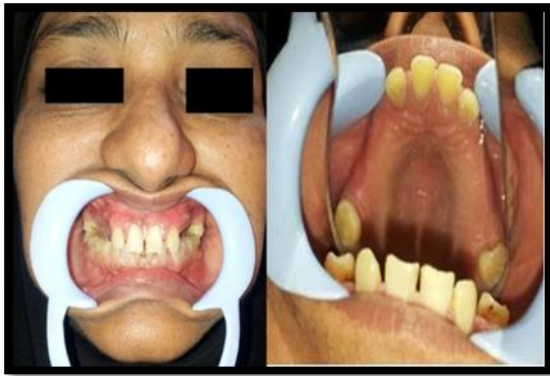

Fig 2: Partially edentulous maxillary arch.

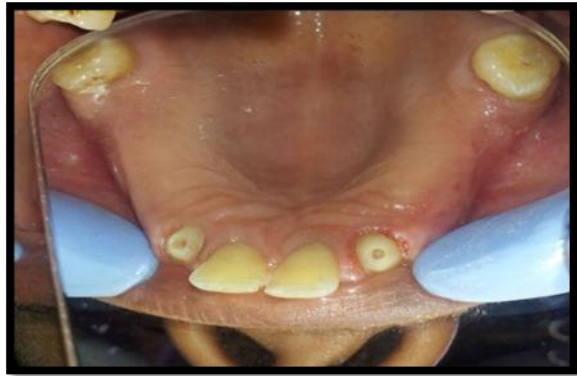

Fig 3: Preparation of post space.

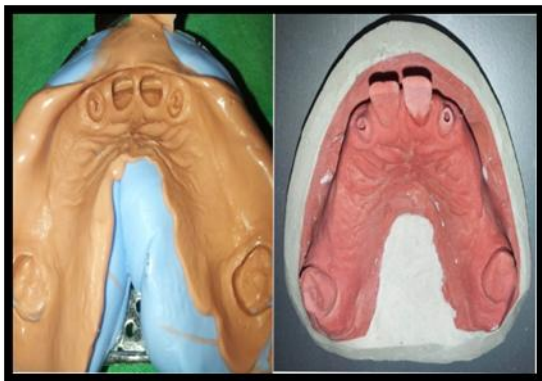

Fig 4: Post space impression and definite cast.

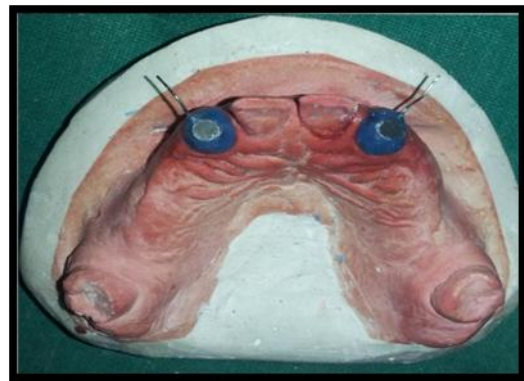


Fig 5: Attachment of keeper.

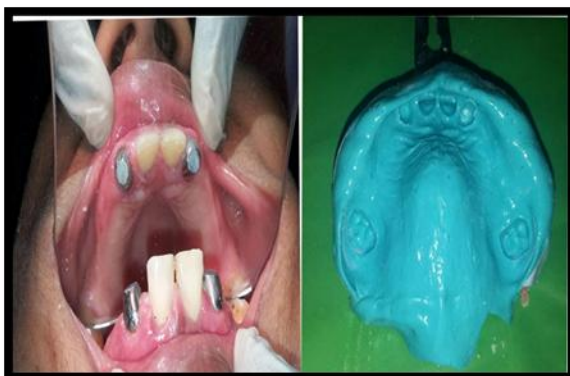

Fig 6: Metal coping with keeper and Final impression.

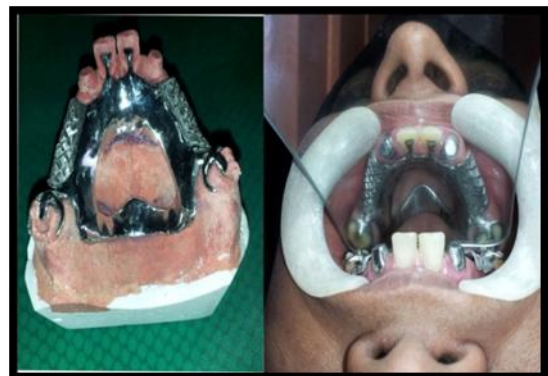

Fig 7: Metal frame work and try in.

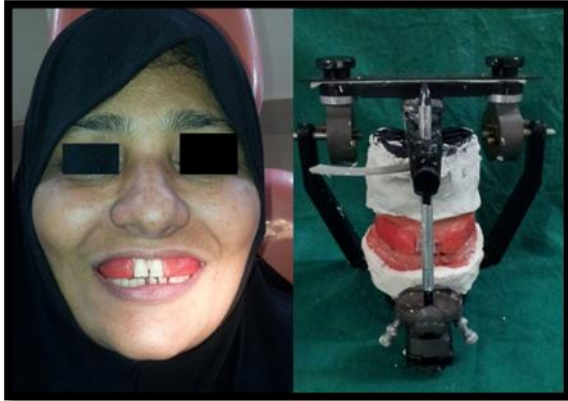

Fig 8: Jaw relation.

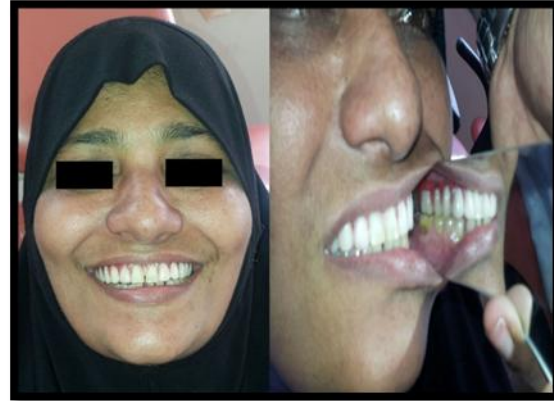

Fig 9: Try in

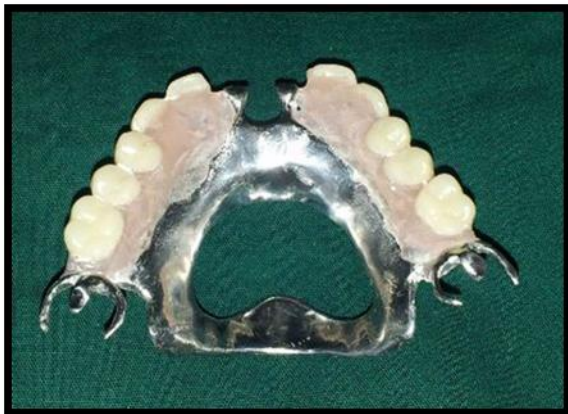

Fig 10: Final prosthesis

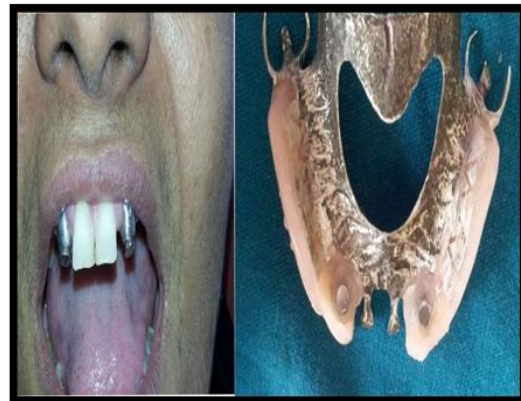

Fig 11: Pick up of magnet to denture

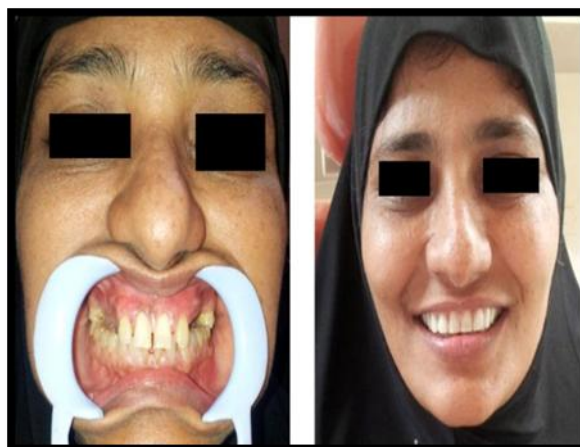

Fig 12: Pre and Post operative.

III. Discussion

Dental magnetic assembly of various types and sizes are commercially available. These systems, consisting of a magnet and a keeper, are used to retain removable partial dentures and maxillofacial prostheses. Magnetic system can also be used in an implant supported overdenture with magnets incorporated into the denture acting upon keepers attached to implant abutments. Most commercially available magnetic attachments are composed of a magnet and yoke made from ferromagnetic material [5,6,7,8]. In this case report neodymium–boron–iron (NdBF_e) magnets, stainless steel (AUM20) keeper were used. The heights of magnets

were 1.0 mm and keepers height and diameter were 0.5 mm and 3.0 mm respectively, selected according to the cross section of the retained root. Since these rare earth magnets are vulnerable to corrosion especially in the oral environment they are covered and sealed with a yoke cap. In the present case, the magnetic assembly utilized a stainless steel casing hermetically sealed by micro laser welding which provided a corrosion resistant environment in the oral cavity and magnets need not be replaced often which is a major advantage over other magnet systems.

3.1 Advantages of intra oral magnets include: Easy incorporation into a denture involving simple clinical and technical procedures, ease of cleaning, ease of placement for both dentist and patient (physically disabled or neuromuscular compromised), automatic reseating, and constant retention with number of cycles. They are typically shorter than mechanical attachments, are particularly useful for patients with restricted interocclusal space and challenging esthetic demands, can also accommodate a moderate divergence of alignment between two or more abutments and dissipate lateral functional forces. [9]

IV. Conclusion

Magnetic assembly used in this case is a new generation magnetic attachment system which provides predictable retention, stability, support, and offers long term durability. This system has successfully rehabilitated the patient when compared to overdenture with implants, when cost and time factors were considered. Magnet retained cast partial overdenture prevents unesthetic display of metallic clasp in esthetic zone, preserving natural abutment teeth has better proprioception and satisfaction, and enhanced esthetic gave a confident and psychologically beneficial for the patient.

References

- [1]. Becker J. Permanent magnets. *J Appl Phys* 1970;233:92-100.
- [2]. Strnat KJ. The hard magnetic properties of rare earth transition metal alloys. *IEEE Trans Magn* 1972;8:511-6.
- [3]. Sagawa M, Fujimura S, Yamamoto H, Matsuura Y, Hiraga K. Permanent magnet materials based on the rare earth-iron-boron tetragonal compounds. *IEEE Trans Magn* 1984;20:1584-9.
- [4]. Sagawa M, Fujimura S, Togawa N, Yamamoto H, Matsuura Y. New material for permanent magnets on a base of Nd and Fe. *J Appl Phys* 1984;55:2083-7.
- [5]. Maeda Y, Nakao K, Yagi K, Matsuda S. Composite resin root coping with a keeper for magnetic attachment for replacing the missing coronal portion of a removable partial denture abutment. *J Prosthet Dent* 2006;96:139-42.
- [6]. Van Waas MA, Kalk W, van Zetten BL, van Os JH. Treatment results with immediate overdentures: An evaluation of 4.5 years. *J Prosthet Dent* 1996;76:153-7.
- [7]. Saha S, Ray Chaudhuri A. Mandibular implant retained complete overdenture using retentive abutments: A case report. *Dent Update (England)* 2009;36:154-8.
- [8]. Riley MA, Walmsley AD, Harris IR. Magnets in prosthetic dentistry. *J Prosthet Dent* 2001;86:137-42.
- [9]. Ceruti P, Bryant SR, Lee JH, MacEntee MI, magnet retained implant supported overdentures: Review and 1 year clinical report. *J Can Dent Assoc* 2010;76:52.