

Prosthetic Rehabilitation of a Patient with Ectodermal Dysplasia - A Case Report

Dr. Ranjani Thillaigovindan, M.D.S¹, Dr. Paulin Vijay Chandran, M.D.S²,
Dr. Satheesh Babu M.D.S³

^{1,2} (Dept of prosthodontics, Sri Venkateshwaraa Dental College, Ariyur, India)

³ (Dept of oral pathology and microbiology, Sri Venkateshwaraa Dental College, Ariyur, India)

Abstract: The aim of this clinical report is to describe the management of a 20-year-old female patient affected by ectodermal dysplasia. Dental treatment can vary depending on the severity of the disease and age of the patient. The definitive treatment plan may include removable, fixed or implant-supported prostheses or a combination of these options depending on the remaining alveolar bone and pattern of missing teeth. The patient had ten retained deciduous teeth and only 14 permanent teeth (oligodontia). The retained deciduous canines were peg shaped. Wide midline diastema was evident. Maxillary and mandibular arches were poorly developed. Examination also revealed anterior open bite and bilateral posterior cross bite. All the teeth were not well aligned and there was no occlusion at all. Patients with disease often need a multidisciplinary team approach to treatment planning and dental treatment to regain appropriate function, esthetics and comfort.

Keywords: Clinical report, Ectodermal dysplasia, Oligodontia, Midline diastema, Posterior crossbite.

I. Introduction

Ectodermal dysplasia is a hereditary disorder characterized by abnormal development of certain tissues and structures of ectodermal origin. It is a relatively rare disorder, with a frequency ranging between 1:10,000 and 1:100,000 live birth, and more frequent in males. The majority of cases follow the autosomal-recessive mode of inheritance, but it can also be autosomal-dominant or X-linked [1]. According to Pinheiro and Freire-Maia [2], ectodermal dysplasia is any condition with defects in two or more ectodermal derivatives. The most frequently observed types are the hypohidrotic-anhidrotic (Christ-siemens – Touraine syndrome), and the hidrotic (clouston syndrome) [1]. Patients with hypohidrotic ectodermal dysplasia generally have prominent supraorbital ridges, frontal bossing, and a saddle nose. The maxilla may be under developed and the lips thick and prominent. The patient may resemble an edentulous old person. The skin is usually dry, scaly as a result of poorly developed oil glands. Sweat glands can be absent, few in number resulting in a high body temperature. Scalp hair, eye brows and eye lashes may be absent, few in number. Finger and toe nails are usually normal [3,4]. Orofacial characteristics of this syndrome include anodontia or hypodontia, hypoplastic conical teeth, under development of alveolar ridges, frontal bossing, a depressed nasal bridge, protuberant lips and hypotrichosis. Teeth in permanent dentition are usually small, conical, tapered (peg-like), and widely spaced. Lack of alveolar growth is usually associated with this condition and frequently results in increased interocclusal distance which allows optimum artificial tooth placement. Patients may present with marked mandibular protuberance on closure or a deep vertical overlap. Depending on the severity of the condition, various prosthodontic treatments are available to improve appearance, mastication, and speech [2-4]. The hidrotic type was first defined by clouston also called as clouston syndrome. It is transmitted as autosomal dominant trait. The clinical features include normal sweat and sebaceous gland function, total alopecia, nail dystrophy, hyperpigmentation of skin, palmoplantar keratosis and normal teeth [1-5,6]. Numerous combinations of clinical alterations can present in ectodermal dysplasia, observing diverse syndromes and up to 154 different types of ectodermal dysplasias and 11 subgroups, labeled from 1 to 4 according to whether they affect the hair, teeth, nails or sweat glands [2]. Complete or partial anodontia of the primary and permanent dentition and malformation of the teeth are the most frequent dental findings. Oral rehabilitation of these patients is often challenging and is influenced by patient's age, the pattern of dysplasia, and the morphology of the alveolar ridges [7]. The aim of this case report is to present the prosthetic rehabilitation of a patient with ectodermal dysplasia by achieving optimum function, esthetics and appearance of the patient and by enhancing the positive self-image and social comfort.

II. Case Description

A 20-yr old female patient reported with the chief complaint of multiple unerupted teeth, difficulty in chewing and psychosocial problems. The patient gave insignificant family history. She had mild sweating problems. Extra oral examination revealed symmetric face and a straight profile and normal vertical dimension.

Intra oral examination (Fig: 1) revealed the presence of ten retained deciduous teeth and only 14 permanent teeth (oligodontia). The retained deciduous canines were peg shaped. Wide midline diastema was evident. Maxillary and mandibular arches were poorly developed. Examination also revealed anterior open bite and bilateral posterior cross bite. All the teeth were not well aligned and there was no occlusion at all.

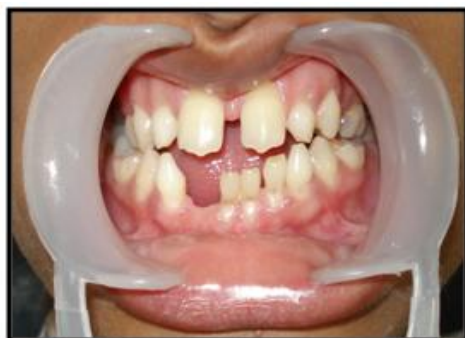

Fig 1: Intra oral view (Pre-operative)

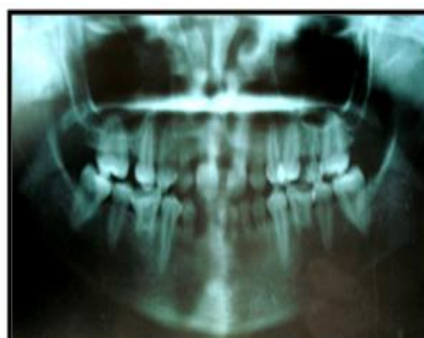

Fig 2: Pre-operative pantamogram.

Pre-operative radiograph (Fig: 2) shows the roots of the retained deciduous were resorbed which is not suitable for providing support for fixed prosthesis. The retained deciduous mandibular second molars are rectangular in shape with wide pulp chamber and the bifurcation seen only few millimeters above the apex of the root which gives the appearance of a taurodont [8]. The radiograph also reveals congenital absence of permanent maxillary lateral incisors, canines, first molars and mandibular anteriors and first molars.

A diagnosis of partial anodontia was made from clinical and radiographic features. Complete rehabilitation of dentition was planned with fixed partial denture and the patient was informed about the treatment. The treatment objective is to provide an ordered pattern of occlusal contact and articulation to optimize oral function, health of TMJ, occlusal stability, esthetics and comfort. Because of insufficient amount of alveolar bone, implant placement may be subjected to a greater risk of failure [9,10] .

III. Treatment Planning

The treatment protocol is to eliminate pain and infection, extraction of poor prognosis teeth. Except the mandibular deciduous first molars, the remaining deciduous teeth were extracted. The two deciduous molars were retained to minimize the alveolar bone resorption. An endodontic consultation was also obtained for the permanent teeth with the patients consent. The permanent teeth were endodontically treated and permanent coronal seal given. So with the existing 14 permanent teeth and 2 deciduous molars,a full mouth rehabilitation was planned with fixed partial denture.

Preliminary maxillary and mandibular impressions were made with irreversible hydrocolloid impression material and the stone casts were obtained. A facebow transfer (Fig: 3, 4) is done to orient the maxillary cast to the hinge axis of the whip mix semi- adjustable articulator. After the maxillary cast is articulated, interocclusal records are made to relate the mandibular cast with the maxillary cast. Interocclusal records are made with the patient in retruded mandibular jaw relationship using bimanual palpation method and wax record. The patient's vertical dimension is increased lightly by 2mm to create interocclusal space to accommodate restorative material and to allow adequate clinical crown height [11].

Diagnostic preparations were made on the stone cast, and diagnostic wax up was done for the maxillary and mandibular anterior teeth. Custom acrylic guide table is fabricated with anterior diagnostic wax up. The diagnostic wax up is then completed with a mutually protected concept of occlusion. As the existing intercuspation is unacceptable and has to be changed, the entire occlusal scheme should be modified and restoration provided should be in harmony with new jaw relationship [12].

Simultaneous arch technique is followed where the both the arches are restored simultaneously. Tooth preparation is done in the maxillary arch first followed by tooth preparation in the mandibular arch. Provisional restoration is then fabricated with the help of diagnostic wax-up by using indirect technique. It is cemented with temporary zinc oxide eugenol cement. The provisional restoration is maintained intraorally for 4 weeks before final impressions were made, allowing sufficient time for evaluation of VDO.

The patient was satisfied with the esthetics and comfort. The final impressions are made with addition silicone impression material. The master cast is obtained and wax pattern is fabricated in the mounted cast. The metal frame works is then obtained and try-in done in the patient's mouth followed by porcelain application. The maxillary and mandibular metal-ceramic restoration is finally evaluated in the clinical remount. The restoration is then glazed, polished and then luted with resin-modified glass- ionomer cement (Fig 6, 7, 8).



Fig 3: Face bow (quick mount) record in patient.

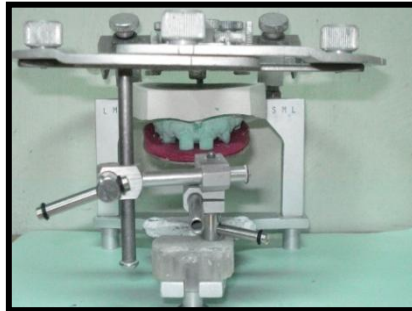

Fig 4: Face bow mounted on the whip-mix articulator.

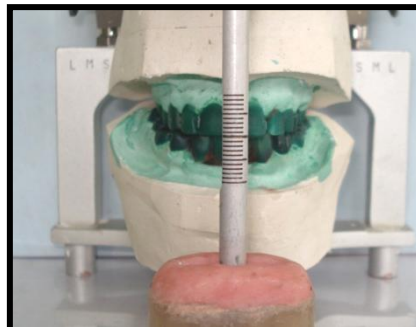


Fig 5: Completed diagnostic preparation and wax-up in the articulator.

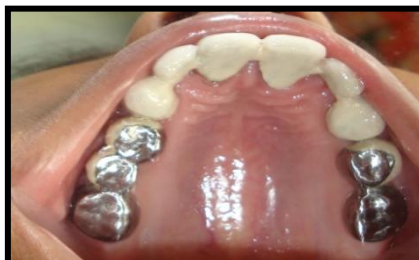

Fig 6: Metal-ceramic retoration cemented in maxillary arch.

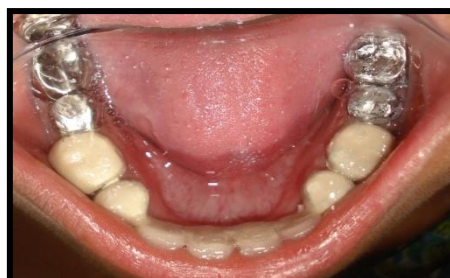

Fig 7: Metal-ceramic retoration cemented in mandibular arch



Fig 8: Rehabilitated patient

IV. Conclusion

Dental defects associated with ectodermal dysplasia can cause severe esthetic and functional problems. A multidisciplinary team approach to the oral rehabilitation of an adult patient with reduced number of teeth and underdeveloped alveolar bone has been presented [6]. The treatment not only improved the patient's functional and esthetic status, but also significantly increased her self-esteem. It is also important in the management of ectodermal dysplasia to include oral hygiene instruction, fluoride treatments, and periodic recall visit [13,14,15].

References

- [1]. Vallejo AP et al. Treatment with removable prosthesis in hypohidrotic ectodermal dysplasia. A clinical case. *Med Oral Patol Oral Cir Bucal*.2008 Feb 1;13(2):E 119-23.
- [2]. Priolo M et al. Ectodermal dysplasias: a new clinical-genetic classification. *J Med Genet* 2001; 38:579-585.
- [3]. Bal C et al. treatment considerations for a patient with hypohidrotic ectodermal dysplasia: A case report. *J Contemp Dent Pract* 2008 March;(9)3:128-134.
- [4]. Guckes AD et al. Prospective clinical trial of dental implants in persons with ectodermal dysplasia.2002 July;21-25.
- [5]. Tarjan I. Early prosthetic treatment of patients with ectodermal dysplasia: A clinical report: *J Prosthet Dent* 2005; 93: 419-24.
- [6]. Shigli A et al. Hypohidrotic ectodermal dysplasia: A unique approach to esthetic and prosthetic management: A case report: *J of Indian society of pedodontics and preventive dentistry* 2005;23:31-34.
- [7]. Bergendal B. Prosthetic habilitation of a young patient with hypohidrotic ectodermal dysplasia and oligodontia: A case report of 20 years of treatment. *Int J Prosthodont* 2001; 14:471-479.
- [8]. Muzio LL et al. Prosthetic Rehabilitation of a child Affected from Anhydrotic Ectodermal Dysplasia: A Case Report. *J Contemp Dent Prac* 2005 August;(6)3:120-126.
- [9]. Rashedi B. Prothodontic Treatment with Implant Fixed Prosthesis for a Patient with Ectodermal Dysplasia: A Clinical Report. *J Prothodont* 2003;12: 198-201.
- [10]. Siegel SC et al. Oral rehabilitation of a child with primary failure of tooth eruption. *J Prosthodont* 1999; 8:201-207.
- [11]. Patel MI et al. Prothodontic rehabilitation of a patient with partial anodontia: A clinical report: *J Prosthet Dent* 2002; 88: 132-4.
- [12]. Vence BS. A Systematic approach to full-mouth rehabilitation: Clinical and laboratory guidelines. *Quintessence*,2001;78-92.
- [13]. Imiralioglu P et al. Surgical and prosthodontic treatment alternatives for children and adolescents with ectodermal dysplasia: A clinical report. *J Prosthet Dent* 2002;88:569-72.
- [14]. Rambo V et al. Complete dentures for a child with hypohidrotic ectodermal dysplasia: A Clinical report. *J Prosthet Dent* 1995;74:329-31.
- [15]. Bergendal B. The role of prothodontist in habilitation and rehabilitation in rare disorders: The Ectodermal Dysplasia Experience. *Int J Prosthodont* 2001; 1: 466-470.