

## A Missed Case of Bladder Injury with Pubic Diastasis Injury

Dr. Anil Dhule<sup>1</sup>, Dr. Sandeep Chaudhary<sup>2</sup>, Dr. Ganesh M Nalge<sup>3</sup>,  
Dr. Shashikant Nawale<sup>4</sup>

<sup>1</sup>(Associate Professor, Department of Orthopaedics, G.M.C.H. Aurangabad, India)

<sup>2</sup>(3<sup>rd</sup> year resident, Department of Orthopaedics, G.M.C.H. Aurangabad, India)

<sup>3</sup>(2<sup>nd</sup> year resident, Department of Orthopaedics, G.M.C.H. Aurangabad, India)

<sup>4</sup>(2<sup>nd</sup> year resident, Department of Orthopaedics, G.M.C.H. Aurangabad, India)

**Abstract:** High-velocity trauma results in pelvic injury along with bowel and bladder injury. Timely identification and management of genitourinary injuries minimize associated morbidity. Proper history regarding passing urine, physical examination and clinical suspicion of bladder & bowel injury is very important as these injuries can be missed on ultrasound examination. We had one patient with normal USG abdomen pelvis, with pubic diastasis, while fixing found bladder injury with extra peritoneal urinary collection.

### I. Introduction

Pelvic fractures are usually the result of high-energy trauma and may have associated soft tissue and organ damage resulting in significant morbidity and mortality in these patients. The typical profile of such patient depicts a young male individual in his 30s involved in a high-energy road traffic accident (RTA) [1].

There may be multiple-system involvement following injury. Injuries to the lower genitourinary (GU) tract alone are not life threatening, but their association with other potentially more significant injuries necessitates an organized approach to diagnosis and management. Other injuries often take priority over injuries to the genitourinary system and may initially interfere or postpone a complete urologic assessment. Coordinated efforts between various services caring for the patient are crucial to ensure comprehensive care [2, 3].

Initial evaluation of the injured patient should follow the protocols of the Advanced Trauma Life Support program of the American College of Surgeons [4].

The lower GU tract comprises the urinary bladder, urethra, and external genitalia. Most bladder injuries occur in association with blunt trauma. Eighty-five percent of these injuries occur with pelvic fractures, with the remaining 15% occurring with penetrating trauma and blunt mechanism not associated with a pelvic fracture (i.e., full bladder blowout) [5].

Bladder injuries are best classified as intraperitoneal and extra peritoneal. Extra peritoneal bladder injuries account for 65–85% of bladder injuries and are usually associated with pelvic fractures, especially pubic ramus fractures (95%). Intraperitoneal bladder injuries account for 15–35% of bladder injuries and are infrequently associated with pelvic fractures. These injuries may be due to blunt rupture of a distended bladder or penetrating injury [5]. In this paper we are discussing a case of 50 yr. old male, RTA victim, in whom repeated USG Abdomen pelvis was normal & after 15 days when he was taken for fixation was found to have extra peritoneal rupture of bladder

### II. Case Report

A 50-year-old male pedestrian was hit by an autorikshaw and he immediately presented to our hospital. X-rays showed open book injury of pelvis with grade 3 compound fracture tibia fibula of left lower limb. Patient's vital parameters were stable. There was no distal neurovascular deficit. Use abdomen pelvis was done at the time of admission and no abnormality was detected. Patient didn't had any urinary complaint on admission. Next day he developed a scrotal swelling on the 3<sup>rd</sup> day he complained that he had not passed urine for 2 days. Then a repeat use was done and it didn't show any injury. General surgery opinion was done. Surgeon was able to pass a urethral catheter and there was a urinary flow through catheter. The urine was blood tinged and the surgeon suspected a urethral injury. But repeat USG also didn't show any injury and the patient was stable. The blood investigations showed deranged KFT values with serum creatinine 6 mg% and blood urea as 80mg/dl Serum creatinine became normal on 3<sup>rd</sup> day after insertion of catheter, General surgeon made final diagnosis of urethral injury On 15<sup>th</sup> day Patient was taken for fixation of pelvic injury as pt. was unfit for surgery till this period. Transverse incision 2 cm above pubic tubercle was taken, below fat layer external oblique aponeurosis identified. Muscle plain was found to be disturbed, there was sudden gush of urine seen, suspecting bladder injury general surgeon was called for further exploration. Large bladder tear was seen. A 2 cm rupture of the bladder was seen in the anteroinferior aspect of bladder and the ruptured portion was adherent with fracture site. Urine drained in extra peritoneal space. Bladder tear was repaired. Suprapubic catheter was kept,

urethral catheter was maintained insitu.Locking reconstructionplate was applied on the superior aspect of pubic rami& fixed with four screws, drain kept,incision closed procedure uneventful.Postoperatively side to side movement and siting was allowed as the patient tolerated. Urethral catheter was removed after 3 weeks and suprapubic after 8 weeks. Meanwhile open reduction, interlocking nailing for fracture tibia fibula was done as wound was healed completely.

### **III. Discussion**

In the setting of an acute injury, evidence based recommendations mandate a cystogram if there is haematuria and concomitant pelvic fracture. Yet delays (usually hours to days) and difficulties in the diagnosis of lower urologic injuries in the context of pelvic fractures have been documented in the literature [6, 7].

Prompt recognition and early management of these urological injuries are necessary in order to reduce morbidity and mortality. Difficulties arise most often in the multitrauma patients when lifesaving measures or damage-control surgery may delay the diagnosis and treatment of lower urinary tract injuries [8].

With the increased concentration of management of injured patients in trauma centres, both orthopaedic surgeons and urologists are recognising increasing numbers of lower urinary tract injuries [8].

Our case report presents an unusually delayed presentation of bladder injury after significant pelvic trauma. It highlights the importance of a good history and examination especially in the presence of persistent and unexplained symptoms. It also supports the view that a high volume of cases, standardized trauma protocols, and high index of suspicion can be proved to be of great benefit and help avoid delays in diagnosis and prompt management of such injuries.Although it is probably safe to assume that bladder injuries will continue to be a rare event, they will occur. It has been shown that a high index of suspicion and rapid utilization of all resources is our only way of diagnosing these injuries in a timely manner. Bony spicules in close proximity to the bladder wall have been speculated to be an increased risk for bladder rupture if seen and should be carefully examined [7].

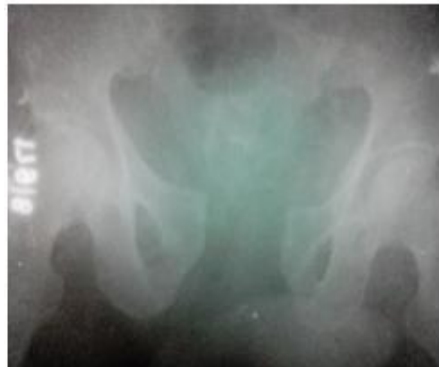### **IV. Conclusion**

While treating patients with pelvic injury a proper history regarding passing urine is very important and should be sought. USG is not the full proof method to rule out the genitourinary injury. So the possibility of bladder injury should be ruled out in each case.

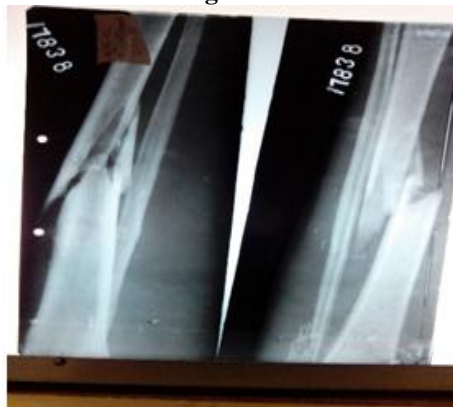### **V. Conflict Of Interests**

The authors declare that there is no conflict of interests regarding the publication of this paper.

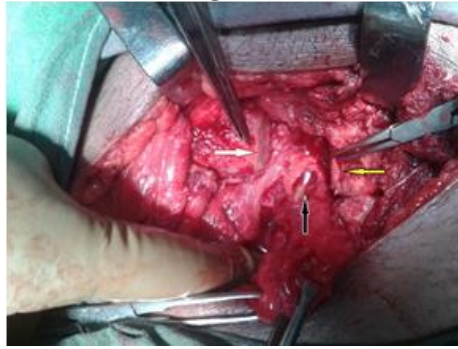
**Figure 1**



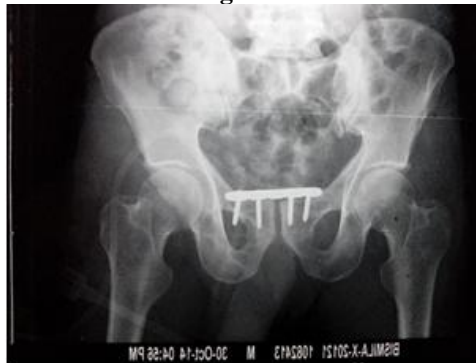**Figure 2**



**Figure 3**



**Figure 4**



**Figure 1** – showing open book fracture pubic symphysis

**Figure 2**- showing mid shaft tibia fracture lt leg

**Figure 3**- intra operative photographs showing bladder rupture (black arrow) pubic bones (white arrow)

**Figure 4**- post operative photograph after fixation.

### Reference

- [1]. N. Davarinos, P. Ellanti, S. Morris, and J. P. Mc Elwain, "Epidemiology of pelvic and acetabular trauma in a Dublin tertiary hospital: a 10-year experience," *Irish Journal of Medical Science*, vol. 181, no. 2, pp. 243–246, 2012. View at Publisher · View at Google Scholar · View at Scopus
- [2]. P. C. Walsh, "Genitourinary trauma," in *Campbell's Urology*, p. 2574, WB Saunders, London, UK, 6th edition, 1992.
- [3]. W. G. Guerriero, "Trauma to the kidneys, ureters, bladder, and urethra," *Surgical Clinics of North America*, vol. 62, no. 6, pp. 1047–1074, 1982. View at Scopus
- [4]. American College of Surgeons Committee on Trauma, "Initial assessment and management," *Advanced Trauma Life Support Program for Physicians*, 1993.
- [5]. P. Cutinha and C. R. Chapelle, "Bladder injuries," *International Surgery*, vol. 37, pp. 107–112, 1997.
- [6]. B. H. Ziran, E. Chamberlin, F. D. Shuler, and M. Shah, "Delays and difficulties in the diagnosis of lower urologic injuries in the context of pelvic fractures," *Journal of Trauma*, vol. 58, no. 3, pp. 533–537, 2005. View at Publisher · View at Google Scholar · View at Scopus
- [7]. S. Deem, C. D. Lavender, and S. Agarwal, "Delayed presentation of traumatic bladder injury: a case report and review of current treatment trends," *The Internet Journal of Urology*, vol. 5, no. 1, p. 8, 2007.
- [8]. J. P. L. Kong, M. F. Bultitude, P. Royce, R. L. Gruen, A. Cato, and N. M. Corcoran, "Lower urinary tract injuries following blunt trauma: a review of contemporary management," *Reviews in Urology*, vol. 13, no. 3, pp. 119–130, 2011.