

Autotransplantation: The Best Implant for A Missing Tooth Is A Natural Tooth

Dr. Reshma Chawla¹, Dr. Ushaina Fanibunda², Dr. Vibha Hegde³

¹Post Graduate Student, Dept. of Conservative Dentistry and Endodontics, Y.M.T. Dental College and Hospital, Kharghar, Navi Mumbai

²Reader, Dept. of Conservative Dentistry and Endodontics, Y.M.T. Dental College and Hospital, Kharghar, Navi Mumbai

³Professor & Head of Department, Dept. of Conservative Dentistry and Endodontics, Y.M.T. Dental College and Hospital, Kharghar, Navi Mumbai

Abstract: Autogenous tooth transplantation, or autotransplantation, is the surgical movement of a tooth from one location to another in the same individual. Although, once thought to be experimental, autotransplantation has achieved high success rates and is an excellent option for tooth replacement. Although the indications for tooth autotransplantation are narrow, careful patient selection coupled with an appropriate technique can lead to exceptionally well esthetic and functional results. This procedure is advantageous since the placement of an implant-supported prosthesis or any other form of prosthetic tooth replacement is not needed. This case report is one such example of a successful tooth autotransplantation. A review of the surgical technique as well as success rates is also discussed.

Keywords: autogenous tooth transplantation; complete root formation; success rates

I. Introduction

Congenitally missing teeth or teeth lost due to caries, trauma etc. can be a challenge to the clinician. Conventionally, missing teeth are replaced with removable prostheses- which more often caused discomfort to the patient, fixed prostheses- which involve the preparation of one or more healthy teeth or implants- which are often limited by bone availability and are expensive. Tooth autotransplantation provides a viable, predictable treatment option and the most natural one for replacing missing teeth. Autotransplantation refers to the repositioning of autogenous erupted, semierupted or unerupted tooth; from one site into another in the same individual.¹This type of dental surgical intervention was first documented by Abulcassis, in 1050; however, only in 1564, did the French dentist Ambroise Paré perform the first recorded surgery with details about tooth bud transplantation.²In 1953, Fong reported the successful autotransplantation of third molars and was followed by other authors who validated the procedure.³⁻⁵

The following case report presents the successful transplantation of a mandibular third molar with complete root formation.

II. Case Report

A 22 year-old male patient reported to the Department of Conservative Dentistry and Endodontics with a chief complaint of caries and food impaction in relation to 47. Clinical examination showed extensive destruction of the crown of this tooth as a result of dental caries (Fig 1). Radiographic examination confirmed the clinical findings (Fig 2). Examination led to a diagnosis of pulpal necrosis with periapical extension. It was felt that the extent of the caries subgingivally would make restoration of the tooth difficult and hence it was decided to extract it. The 48 was mesioangularly impacted. The impacted third molar (48) was sound, having mature apices and was suitable for transplantation. Thus, autologous tooth transplantation was suggested to prevent bone resorption at the site of the mandibular second molar and to restore function and esthetics. A complete medical history was taken and an informed consent was obtained after the patient was explained about the treatment procedure including the risks and benefits. The patient was prescribed preoperative medication of 500 mg Amoxicillin to prevent infection and a combination of diclofenac sodium (50 mg), paracetamol (500 mg) and serratiopeptidase (15 mg) to reduce post-operative pain and swelling. The procedure was performed in one stage. A flap was raised to visualize the 48 (Fig. 3). The 47 was extracted atraumatically without any damage to the cortical plates (Fig 4). The third molar was extracted and placed back into the extraction socket until the recipient site was prepared with a #4 surgical carbide round bur using a low-speed handpiece under sterile saline irrigation. The donor tooth was then placed into the recipient socket and its fitting was evaluated. Wire splinting was done to stabilize the tooth in the socket and silk suturing was done to stabilize the soft tissues (Fig. 5, 6). The tooth was de-occluded and adjustments made. The patient was prescribed a 0.12% Chlorhexidine mouthwash twice daily for 7 days. After 7 days, the healing was evaluated and the endodontic

treatment was initiated [Fig. 7(a) & (b)]. The endodontic procedures were all carried out under rubber dam isolation following strict asepsis. Stainless steel K-files (Dentsply, Maillefer) were used for initial instrumentation. The root canals were prepared using crown down technique till ProTaper size F1. The canals were irrigated with 5.25% sodium hypochlorite solution. Calcium hydroxide was placed as an intracanal medicament for 15 days after which the tooth was obturated using guttapercha and a MTA based sealer (Fillapex, Angelus) (Fig. 8). The splint was removed after 20 days after the transplant.

Clinical and radiographic follow-ups were conducted at 3, 6 (Fig. 9, 10) and 12 months after autotransplantation and demonstrated successful treatment. At the end of 1 year, bone growth around the transplanted tooth was considered satisfactory (Fig 11).

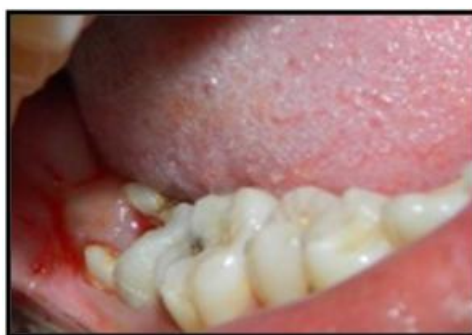

Fig. 1: Pre-operative photograph

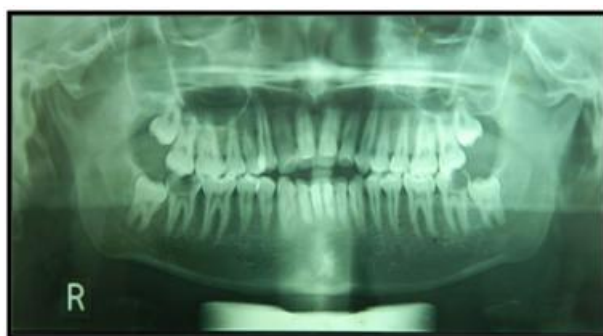

Fig. 2: Pre-operative Panoramic view

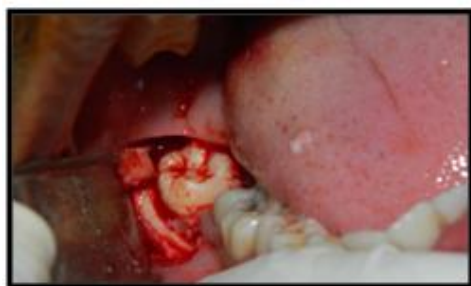

Fig. 3: Flap raised to visualize 48

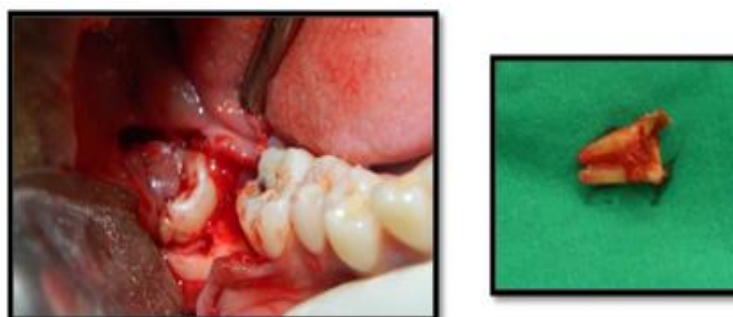

Fig. 4: Atraumatic extraction of 47

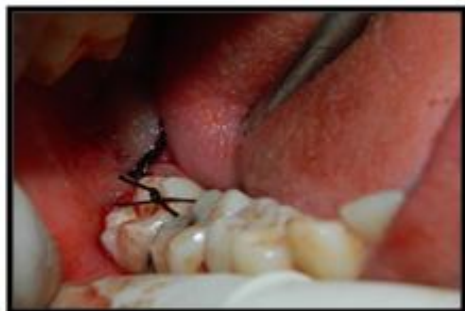

Fig. 5: soft tissues approximated and stutured

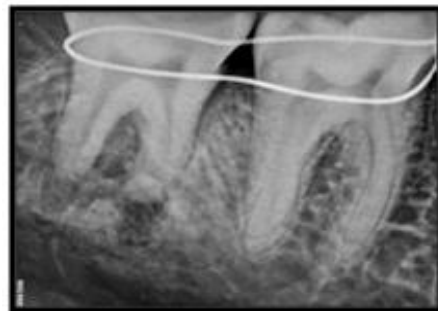


Fig. 6: Immediate post-operative radiograph

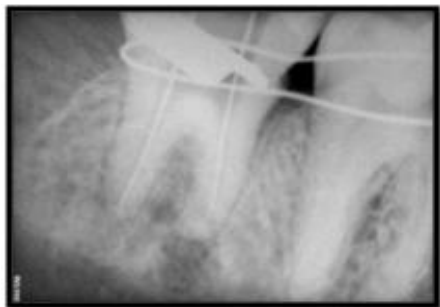

Fig. 7(a): working length determination

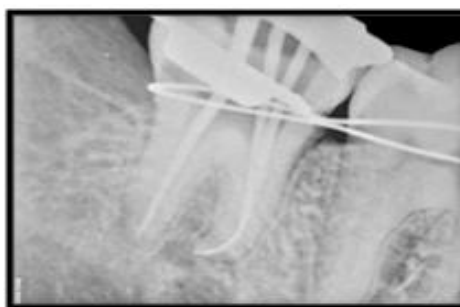

Fig. 7(b): Master cone radiograph

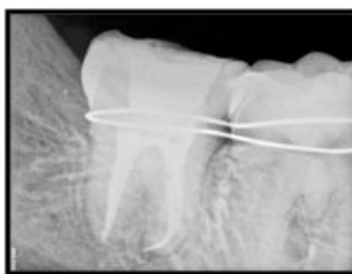

Fig. 8: Post-obturation radiograph

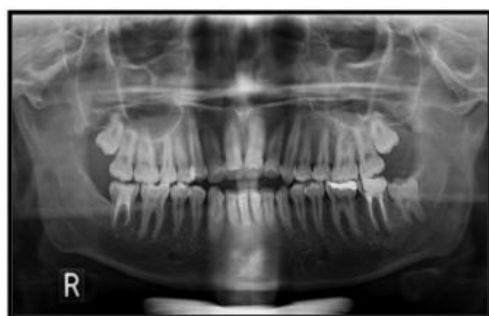

Fig. 9: Follow-up OPG

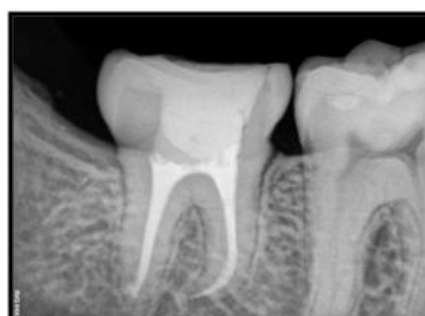

Fig. 10: 6 month follow-up radiograph

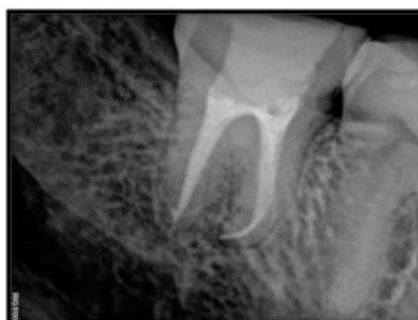

Fig. 11: Radiograph taken 1-year after treatment indicating a successful outcome.

III. Discussion

Autotransplantation can be defined as the transplantation of teeth from one site to another in the same individual into extraction sites or surgically prepared sockets.⁶The advantages of autotransplantation include: the possibility of maintaining the viability of the periodontal ligament, orthodontic movement and proprioception, and preservation of the alveolar bone and gingiva with a natural contour. Moreover, autotransplantation has a low procedural cost compared to that of osseointegrated implants since it is performed in a single stage and no prosthesis is required. Careful case selection and treatment planning are essential requisites for successful autotransplantation. In the reported case, despite the suitability for placement of an osseointegrated implant, autotransplantation was chosen since it involves a single surgical phase, the donor tooth was in a good condition and the complete procedure had a low cost. The donor tooth and recipient site should both be examined meticulously for suitability and dimensions. The recipient site should have an adequate bone support with sufficient attached keratinized tissues to allow tooth stabilization and should also be free of infection and/or inflammation.

The most important factor for governing the success of autogenous tooth transplantation is the vitality of the periodontal ligament attached to the transplanted tooth. The periodontal ligament is sensitive to pH changes and its viability is reduced if extra oral dry time is extended. The chances of periodontal ligament healing are greatly increased when a donor tooth is immediately placed into a fresh extraction socket.

A clinical-radiographic study conducted with 25 autotransplanted third molars suggested the use of burs under irrigation with normal saline for the preparation of the donor site.⁷The donor tooth is then extracted and placed into the recipient socket for assessment of the fit. If further adjustment of the recipient site is necessary, the donor tooth should be placed back into the extraction socket or kept in sterile saline solution. In our reported case as well as in the case reported by Teixeira et al.⁸, the donor site was prepared using round burs in a low-speed surgical handpiece under sterile saline irrigation and the donor tooth was maintained in its own socket until the preparation and adjustment of the donor site after extraction.

In the present case, occlusal reduction of the transplanted tooth was done to protect the tooth from any occlusal trauma thus allowing proper healing of the periradicular tissues.

The use of calcium hydroxide as an intracanal dressing is indicated as part of the endodontic treatment since the high pH and antimicrobial properties of this medicament contributes to the prevention of root resorption and stimulation of the healing process^{9,10}.

The literature reports excellent success rates following autogenous tooth transplantation when the appropriate protocol is followed. Andreassen¹¹ found 95% and 98% long-term survival rates for incomplete and complete root formation of 370 transplanted premolars observed over a period of 13 years. Kvint et al.¹² performed autotransplantation in 215 patients with a mean follow-up of 4.8 years and reported an overall success rate of 81% and a 100% success rate of premolars autotransplanted to the maxillary incisor region. Similar findings were reported by Bae et al.¹³, who obtained a success rate of 84% in a case series.

The transplanted tooth can serve and function as a normal tooth. Therefore, in addition to improved esthetics and mastication, successful tooth transplantation offers arch space maintenance and preserves the volume and morphology of the alveolar bone. The cost is also considerably reduced in comparison to advanced treatment options such as dental implants and/or prosthetic replacements; moreover, it can be performed as a single-step surgical procedure.¹⁴

IV. Conclusion

It can be concluded that autogenous tooth transplantation, when well indicated, planned and performed, can be a viable alternative mainly in young patients with low socioeconomic conditions, allowing reestablishment of the function (mastication) and aesthetics as well as to contribute clinically for bone formation stimulus at the transplanted site. Proper planning, surgical technique knowledge, the clinician's ability to perform the procedure, and the patient's compliance has a fundamental role in the success of autotransplantation.

References

- [1]. FarheenUstad, FareediMukram Ali, Zaheer Kota, Abdelbagi Mustafa and MohdInayatullah Khan. Autotransplantation of teeth: A Review. *Am. J. Med. Dent. Sci.*, 2013, 1(1):25-30.
- [2]. Nathália Martins Pacini¹, Dirceu Tavares Formiga Nery¹, Daniel Rey de Carvalho¹, Normeu Lima Junior¹, Alexandre Franco Miranda¹, Sérgio Bruzadelli Macedo². Dental autotransplant: case report. *RSBO*. 2012 Jan-Mar; 9(1):108-13.
- [3]. Bae JH, Choi YH, Cho BH, Kim YK, Kim SG. Autotransplantation of teeth with complete root formation: a case series. *J Endod* 2010; 36:1422-1426.
- [4]. Akiyama Y, Fukuda H, Hashimoto K. A clinical and radiographic study of 25 autotransplanted third molars. *J Oral Rehabil* 1998; 25:640-644.
- [5]. Yan Q, Li B, Long X. Immediate autotransplantation of mandibular third molar in China. *Oral Surg Oral Med Oral Pathol Oral Radiol Endod* 2010; 110:436-440.
- [6]. Tsurumachi T, Kuno T. Autotransplantation of a maxillary first premolar to replace an ankylosed maxillary incisor: 7-year follow-up. *Int Endod J* 2011; 44:863-875.

- [7]. Akiyama Y, Fukuda H, Hashimoto K. A clinical and radiographic study of 25 autotransplanted third molars. *J Oral Rehabil* 1998;25:640-644.
- [8]. Teixeira CS, Pasternak Jr. B, Vansan LP, Sousa-Neto MD. Autogenous transplantation of teeth with complete root formation: two case reports. *IntEndod J* 2006;39:977-985.
- [9]. Heer J. Calcium hydroxide therapy and bony regeneration following autogenous tooth transplantation: case report and three year follow up. *Br Dent J* 2007;203:403-405.
- [10]. Singh R, Khatter R, Bal R, Bal C. Intracanal medications versus placebo in reducing postoperative endodontic pain – a double-blind randomized clinical trial. *Braz Dent J* 2013;24:25-29.
- [11]. Andreasen JO, Paulsen HU, Yu Z, Bayer T, Schwartz O. A long-term study of 370 autotransplanted premolars. Part II. Tooth survival and pulp healing subsequent to transplantation. *Eur J Orthod* 1990; 12(1):14-24.
- [12]. Kvint S, Lindsten R, Magnusson A, Nilsson P, Bjerklin K. Autotransplantation of teeth in 215 patients. A follow-up study. *Angle Orthod* 2010; 80:446-451.
- [13]. Bae JH, Choi YH, Cho BH, Kim YK, Kim SG. Autotransplantation of teeth with complete root formation: a case series. *J Endod* 2010;36:1422- 1426.
- [14]. Asgary S, Ehsani S. Autotransplantation of A Third Molar with Complete Root Development: A Case Report. *International Journal of Surgical Research* 2012, 1(1): 1-6.