

## Jejunal Diverticular Disease Presenting As Perforation Peritonitis:A Rare Case Report

Dr. Abha Gune<sup>1</sup>, Dr. Ankur V. Tiwari<sup>2</sup>, Dr. Vadiraj Hunnur<sup>3</sup>  
<sup>1,2,3</sup>, (General Surgery Department, M.G.M Medical college, India)

**Abstract:** Jejunal diverticular disease is a rare disease and gets complicated even more rarely. Perforation being the least commonly reported complication. We report a case of a 60 year female presenting with crampy abdominal pain since two days and five episodes of vomiting. Abdominal scout x-ray revealed gas under diaphragm and few air-fluid levels. On laparotomy multiple jejunal diverticulae with a diverticular perforation and fecal contamination was present. Peritoneal lavage and resection of diseased segment followed by primary anastomosis was done. Post operative period being uneventful, patient recovered and discharged. Jejunal diverticulosis in the elderly can lead to significant morbidity and mortality and so prompt diagnosis and treatment necessary.

**Keywords:** Diverticular perforation, Diverticulitis, Jejunal perforation, Perforation peritonitis.

### I. Introduction

Jejunal Diverticula is a rare entity; incidence being less than 0.5% [1]. Jejunal Diverticula are pseudo-diverticula of pulsion type pathologically, with a complication rate of 10 to 30 % of which perforation is rare [1]. Radiological investigations help to diagnose asymptomatic as well as complicated jejunal diverticular perforations [2].

### II. Case Report

A 60 year old woman came to Emergency Department with generalized abdominal pain since two days. Patient had moderate fever and five episodes of vomiting. On physical examination the patients pulse was 106 /minute, blood pressure was 100/70mmHg and patient had tachypnea. Abdominal examination revealed generalized tenderness, guarding and rigidity. On laboratory investigations total WBC count and serum creatinine was raised. An erect abdominal X-ray showed free gas under diaphragm suggestive of perforated viscus "Fig. 1". The patient underwent an emergency exploratory laparotomy. Intra operative findings were multiple diverticuli, identified over a 15 centimeters segment of proximal jejunum, along the mesenteric border "Fig.3" approximately 10 centimeters from the duodenal- jejunal junction, of which one was perforated "Fig.2". A segmental resection of the jejunum was undertaken with end to end anastomosis in two layers. The rest gastro-intestinal tract appeared normal. Pelvic drain was kept, which was removed on post-operative day 5. Patient was started on oral diet on post-operative day 4. Patient had uneventful post-operative recovery and was discharged a week later.

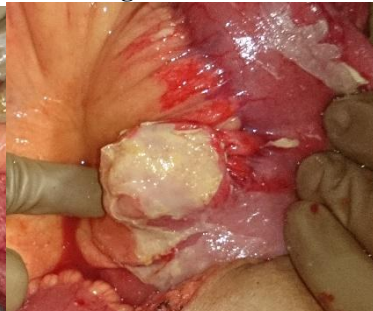
Figure 1.

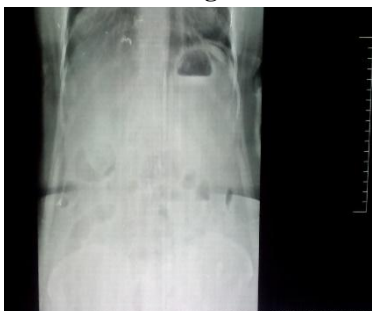

Figure 2.

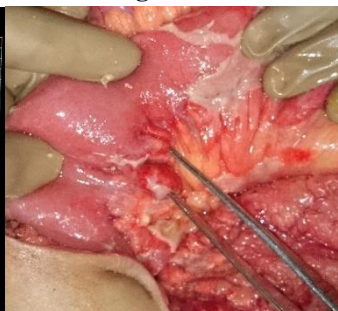

Figure 3.



### III. Discussion

The prevalence of jejunal diverticula is 0.5% [1]. It was first described by Somerling in 1794 and Sir Astley Cooper in 1807. Radiologically on enteroclysis study the prevalence is 2.0 to 2.3 % in general population and autopsy studies reveal incidence of 0.06 – 4.6 % [3]. The incidence is higher in elderly men (58%) [5].

The true etiology of the disease is not known, but is believed to develop from a combination of abnormal peristalsis, intestinal dyskinesia and high segmental intraluminal pressure [2]. About 75% of the small bowel diverticuli are located in proximal jejunum, around 20 % in distal jejunum and around 5% in

ileum[4]. Jejunal diverticula are of pulsion type usually 1-4 centimeters in diameter and found along the mesenteric border [2]. Those larger than 4 centimeters are called 'Giant diverticula' [10]. Jejunal diverticula are situated on the mesenteric border of the bowel and consists of mucosa and submucosa[2]. Jejunal diverticula may be associated with Fabry's disease, Ehlers- Danlos syndrome and rare neuromuscular disorders like Cronkhite- Canada Syndrome [10].

Diverticula are usually asymptomatic but can present with a triad of epigastric pain, abdominal discomfort and flatulence one to two hours after meals. Patient might complain of chronic nonspecific abdominal pain, but diverticula can be life threatening. Complication in jejunal diverticula occur in 6- 10 % cases [4]. Complications include diverticulitis, malabsorption, hemorrhage, mechanical obstruction and perforation. Perforation of the diverticula is rare and occurs in 2.3 to 6.4 % patients [3]. Perforation is not always because of diverticulitis, but can be because of trauma or foreign body[10].

Barium study of small intestine is one of the best radiological test to identify diverticulae, it is contraindicated in perforation [3]. Plain X-ray abdomen standing will show free gas under diaphragm in perforation. Computer tomography will be helpful in diagnosing perforation [4].

The management of the disease depends upon the presentation of the patient. If diverticulae are an incidental finding during laparotomy and patient had no symptoms related to it, diverticulae are left alone [2]. If the jejunal diverticular perforation causes localized peritonitis and if the patient remains vitally stable, a trial of conservative management with intravenous antibiotics and supportive measures along with computer tomography guided aspiration of the localized intra-peritoneal collection may be done to avoid surgery [7]. The current treatment of choice for perforated diverticula is exploratory laparotomy with segmental intestinal resection and primary anastomosis of the bowel loop [1,6]. If extensive diverticula are present on laparotomy and if resection may land up the patient into short bowel syndrome, it is wise to leave a segment of non-perforated diverticula unresected [8].

Diagnosis of Jejunal diverticulosis is challenging. Abdominal X ray may present with free gas under diaphragm, multiple air fluid levels and dilated bowel loops [1]. Jejunal wall thickening and localized abscess can be diagnosed on Computer Tomography[2]. Double-balloon enteroscopy and capsule endoscopy can diagnose diverticulum. These procedures cannot be used in case of perforation. The reported overall mortality rate is 24%, with a mortality rate of 14% in cases where resection of the involved segment with primary anastomosis was done [9].

In our patient there was a segment of jejunum with diverticulae of which one was perforated. The complete segment with all the diverticulae was resected with primary anastomosis, as it would not have predisposed to short bowel syndrome.

#### **IV. Conclusion**

Jejunal Diverticula are rare and silent disease. They may lead to complications including perforation which require immediate intervention in form of laparotomy. In case jejunal diverticulitis has been diagnosed, medical management should be started promptly to reduce the risk of complications. It should be suspected in those presenting with crampy abdominal pain and altered bowel habits in old age.

#### **References**

- [1]. Zager JS, Garbus JE, Shaw JP, Cohen MG, Garber SM: Jejunal diverticulosis: a rare entity with multiple presentations, a series of cases. *Dig Surg* 2000, 17:643-645.
- [2]. Joseph S Butler\*, Christopher G Collins and Gerard P McEntee: Perforated jejunal diverticula: a case report: *Journal of Medical Case Reports* 2010, 4:172 doi:10.1186/1752-1947-4-172
- [3]. Makris K, Tsiotos GG, Stafyla V, Sakorafas GH. Small intestinal nonmeckelian diverticulosis: clinical review. *J Clin Gastroenterol.* 2009;43:201-7.
- [4]. de Bree E, Grammatikakis J, Christodoulakis M, Tsiftsis D. The clinical significance of acquired jejunoileal diverticula. *Am J Gastroenterol.* 1998;93:2523-8.
- [5]. Tsiotos GG, Farnell MB, Ilstrup DM. Nonmeckelian jejunal or ileal diverticulosis: An analysis of 112 cases. *Surgery.* 1994;116:726-32.
- [6]. Herrington JL Jr. Perforation of acquired diverticula of the jejunum and ileum: Analysis of reported cases. *Surgery* 1962;51:426-33.
- [7]. Novak JS, Tobias J, Barkin JS: Nonsurgical management of acute jejunal diverticulitis: a review. *Am J Gastroenterol* 1997, 92(10):1929-1931.
- [8]. Alvarez J Jr, Dolph J, Shetty J, Marjani M: Recurrent rupture of jejunal diverticula. *Conn Med* 1982, 46(7):376-378.
- [9]. Roses DF, Gouge TH, Scher KS, Ranson JH. Perforated diverticula of the jejunum and ileum. *Am J Surg* 1976;132:649-52.
- [10]. Evangelos Falidas\*, Konstantinos Vlachos, Stavros Mathioulakis, Fotis Archontovasilis and Constantinos Villias: Multiple giant diverticula of the jejunum causing intestinal obstruction: report of a case and review of the literature. *World Journal of Emergency Surgery* 2011, 6:8 doi:10.1186/1749-7922-6-8.