

Triple tumors in MISME syndrome- a rare case report and review of literature.

Dr. Duttaluru Seshadri Sekhar¹, Dr. Injeti Babji syamkumar²,
Dr. Bhavanam Hanuma Srinivas³, Dr. Sathish Vandanapu⁴, Dr. Ambati Vimala⁵

^{1,2}Assistant professors, ^{3,4}Senior residents, ⁵Postgraduate.

Dept of neurosurgery, Guntur Medical College, Guntur, Andhra Pradesh, India

Abstract: Neurofibromatosis(NF) type 2, also called as MISME syndrome, is a rare autosomal dominant inherited disorder, characterized by occurrence of multiple benign neoplasms in central and peripheral nervous system associated with eye lesions¹. MISME stands for multiple inherited schwannomas, meningiomas and ependymomas. To our knowledge, till now in literature simultaneous occurrence of all the above three tumors in a single patient with histological confirmation had been reported in only one case². Here with we are reporting a very rare case of MISME syndrome with triple tumors in a 24 year old patient presenting with bilateral vestibular schwannomas, cervico medullary junction(CVJ) meningioma and an intra medullary ependymoma at D11&D12 region.

Keywords: Cervico medullary junction, Ependymoma, Meningioma, Neurofibromatosis type 2, MISME syndrome, Schwannoma.

I. Introduction

NF2, also called as MISME syndrome, is a rare autosomal dominant inherited disorder, with estimated incidence of 1 in 33,000 and prevalence of 1 in 60,000^{3,4}. It has no predilection for race, sex and ethnicity⁴. Most commonly presented in 2nd and 3rd decade, mostly between 16 to 24 yrs of age group⁵. Approximately 50% of cases are familial, remaining 50% are sporadic in nature as a result of de novo/ new mutations⁶. NF2 is caused by defect in merlin gene which is a tumor suppressor gene, located on long arm of chromosome 22(22q12.2)⁷. The hallmark for diagnosis of NF2 is presence of bilateral vestibular schwannomas. The three types of tumors most commonly seen in NF2 are schwannomas, meningiomas and ependymomas. Here with we are presenting a rare case of simultaneous presentation of triple tumors in MISME syndrome with histopathological confirmation in a 24 yr old male patient.

II. Case Report

A 24 yr old patient born to non consanguineous parentage presented to our hospital with the chief complaints of tinnitus and defective hearing in both ears(Rt>Lt) for past 2 years. Swaying while walking for past 1 year, stiffness of all four limbs for past 8 months and urge incontinence of bladder for past 6 months. Family history revealed his father had H/O swaying while walking with right hemiplegia died undiagnosed at an early age, his grand father also died undiagnosed at an early age. Neurological examination showed left 7th cranial palsy(House and Brackmann grade2),and bilateral 8th,9th,10th cranial nerve palsies. Motor examination showed increase tone in all four limbs (Upper limbs Modified Ashworth Score -1,lower limbs Modified Ashworth Score - 2). Deep tendon reflexes are 3+in all four limbs and plantars were bilateral extensor. Sensations of touch and pinprick decreased by 50% below C3 level. Pure tone audiometry showed bilateral sensory neural deafness more on right side. Ophthalmic evaluation revealed bilateral subcapsular lenticular opacities. MRI brain showed bilateral uniformly enhancing cerebellopontine angle(CPangle) tumors(Left - 5x4 cms, Right- 3x3 cms) [Figure:1& 2]. In view of bilateral 8th nerve schwannomas, MRI screening of whole spine was performed.

MRI CVJ with C-Spine revealed a well defined intradural extramedullary lesion of size 4x3 cms with moderate homogenous enhancement anteriorly at cervicomedullary junction extending from C2 to foramen magnum in the form of dumbbell with severe compression over cord [Figure:3]. MRI dorsal spine showed 4x2 cms intramedullary lesion at D11-D12 region with heterogenous enhancement on contrast [Figure:4]. Staged excision of tumors were done. Patient underwent gross total excision of left Cerebellopontine angle tumor through retrosigmoid approach for better preservation of hearing, later stage CVJ and dorsal lesions excised [Figure:5,6& 7]. Histopathology showed Schwannoma, Transitional meningioma and Ependymoma respectively [Figure:8,9& 10].

III. Discussion

Neurofibromatosis(NF) is an autosomal dominant inherited condition characterized by development of multiple neoplasms in central and peripheral nervous system. In 1987 NF was classified as two types(Type 1 & 2) based on their clinical and pathological features⁸. NF type 1 caused by defect in neurofibromin gene which was located on long arm of chromosome 17, where as type 2 caused by mutations in merlin gene located on long arm of chromosome 22(22q12.2). This merlin gene was a tumor suppressor gene, which maintains cell connection of cytoskeleton with the plasma membrane, there by controlling shape, motility of cell as well as growth regulation⁹. It has almost 90% clinical penetrance rate.

The diagnosis of NF2 usually made in 2nd and 3rd decades, mostly 18 to 24 yrs of age. In literature 90-95% of cases of NF2 had 8th cranial nerve schwannomas, 80% of patients develop tumors in other cranial nerves or meningiomas and 2/3 of patients develop spinal neoplasms^{2,10,11}. Approximately 90% of patients suffer from ocular abnormalities mostly early cataracts but retinal hamartomas, epiretinal membranes, corneal lesions also have been documented in literature. There are two phenotypes of NF2. 1) Wishart phenotype and 2) Feiling-Gardner phenotype¹². The Wishart phenotype is more aggressive and characterized by multiple neoplasms in brain and spine, usually seen in patients <20 yrs age. The Feiling-Gardner phenotype mostly seen after 20 yr age group, characterized by single neoplasm in CNS with less aggressive nature. In 1997 diagnostic criteria for NF2 was updated. The definite or confirmed diagnosis of NF2 are A) Bilateral 8th cranial nerve schwannomas on imaging or B) First degree relative with NF2 and unilateral 8th cranial nerve schwannoma at <30 yrs or any two of following: Glioma, Neurofibroma, Schwannoma, Meningioma, Juvenile posterior subcapsular lenticular opacity. The criteria for presumptive or probable diagnosis of NF2 are A) unilateral 8th cranial nerve schwannoma <30 yrs and: Glioma, Schwannoma, Meningioma or posterior subcapsular cataract or cortical cataract. B) Multiple Meningiomas (Two or More) and unilateral vestibular schwannoma <30 yrs or atleast one of Glioma, Schwannoma, Juvenile lens opacity^{13,14,15,16}. More recently in 2011 Baser et al updated NF2 diagnosis criteria¹⁷. The occurrence of various tumors in NF2 include the following

1.Schwannomas: Almost more than 90% cases of NF2 will develop bilateral 8th cranial nerve Schwannomas. In literature occurrence of Schwannomas from other cranial nerves like Trigeminal, Oculomotor, Trochlear and Abducens nerves have been described previously.

2.Spinal Schwannomas: The most common type of spinal tumor in NF2 is Schwannomas. Most common site is Cervico thoracic region originating from dorsal root.

3.Meningiomas: 50 to 75% of NF2 patients develop Meningiomas, most commonly in supra tentorial location. Histopathologically mostly they are fibroblastic type. In spinal cord, Meningiomas are mostly seen in thoracic region.

4.Ependymomas : Mostly Ependymomas are seen in intramedullary location of conus medullaris or cervical region.

5. Astrocytomas: Mostly these are low grade, seen in the brain.

6. Ocular lesions: Approximately 90% of NF2 patients had ocular lesions. Posterior subcapsular lenticular cataract is an important clue for diagnosis of NF2. Occurrence of other eye lesions like retinal Hamartomas, epiretinal membranes, orbital meningiomas, corneal abnormalities can be seen.

NF2 patients may harbor many of pathologies at various CNS locations. Therefore neurological examination and imageological assessment is very important to establish a diagnosis. In 1996 Mautner et al published a case series of 48 NF2 patients about their prevalence of tumors¹⁸. He concluded that 46 patients (96%, 3 unilateral and 43 bilateral) had 8th cranial nerve Schwannomas, 43 patients(90%) had Spinal tumors, 30 patients(63%) had posterior subcapsular cataracts, 28 patients(58%) had Meningiomas, and Trigeminal Schwannomas were found in 14 (29%) patients. MR imaging of brain and spine with contrast is the investigation of choice in NF2 patients. NF2 patients should be managed by multidisciplinary approach which includes a team of doctors like neurologists, neurosurgeons, neuro radiologists, ophthalmologist, geneticist, audiologists and otologists. The children with family history of NF2 should be screened with imageology of brain and spine as early as possible from 10 to 12 years with annual scans until 4th decade. Aoki S et al, 1989 reported a radiological study on NF2 in 11 patients. In that all 11 patients had 8th cranial nerve schwannomas, 8 had other cranial tumors apart from 8th cranial nerve¹⁹.

Management in NF2 patients is preservation of function rather cure as they have life long tendency to develop new tumors and/or recurrences. NF2 related 8th cranial nerve Schwannomas are difficult to manage as they are often big by the time they are diagnosed and tend to behave more aggressive in nature. Most of the

studies shown early intervention is the best for symptomatic Vestibular Schwannomas to preserve auditory and other cranial nerve functions. Cochlear implants, hearing aids complemented by lip reading and sign language and auditory brainstem implants are alternative modes of treatment for complete hearing loss^{20,21,22,23}. In literature conservative treatment for vestibular Schwannomas in NF2 patients is also documented. Clinical trials on Avastin/ Bevacizumab, which is a monoclonal antibody against Vascular endothelial growth factor (VEGF), showing interesting results in preventing growth of CP angle Schwannomas, but still it was only off label use. It is suggested in situations where tumor load is so high and surgery is not possible or beneficial.

MISME syndrome characterized by multiple inherited Schwannomas, Meningiomas and Ependymomas. Very few cases of Simultaneous occurrence of all three tumors in a single patient have been reported in literature. Till now only one case with Simultaneous occurrence of all three tumors with HPE confirmation had been documented. In this report, we have presented a case of triple tumors with MISME syndrome had bilateral 8th cranial nerve Schwannomas, CVJ Meningioma and dorsal intramedullary Ependymoma.

IV. Conclusion

NF2 or MISME syndrome is a rare clinical entity in which development of bilateral 8th cranial nerve Schwannomas are hall mark for diagnosis. As there is lifelong tendency for formation of new tumors, treatment is focussed on preservation of cranial nerve function and maintenance of quality of life. Simultaneous occurrence of triple tumors in NF2 patient is rare. Hence, we should get the imageology of brain and whole spine while treating these cases to rule out the possibility of other tumors at different locations. The patients with family history of NF2 should be screened as early as 10 to 12 yrs of age with annual screening MRI s until 40 years age.

References

- [1]. Spilberg G, Marchiori E, Gasparetto EL, Cabral RF, Takayassu TC, Batista RR, Vieira IG. Magnetic resonance findings of neurofibromatosis type 2: a case report. *Cases J.* 2009 Jul 2;2:6720.
- [2]. Jin X, He J, Wang D, Zhang X, Wu Y, Liu H, Wu Z, Liu J, Luo JJ. MISME syndrome with triple tumors affecting cervical spinal cord. *Neurology cases.* 2014 Apr Vol1: 2374-3522.
- [3]. Evans DG, Howard E, et al. Birth incidence and prevalence of tumor-prone syndromes: estimates from a UK family genetic register service. *Am. J. Med. Genet. A.* 2010 Feb;152A(2):327-3.
- [4]. Baser ME, Evans DG: Lack of sex-ratio distortion in neurofibromatosis 2. *Am J Med Genet* 2000, 95:292.
- [5]. Evans DG. Neurofibromatosis type 2 (NF2): A clinical and molecular review. *Orphanet Journal of Rare Diseases.* 2009;4(16).
- [6]. Antinheimo J, Sankila R, Carpen O, Pukkala E, Sainio M, Jaaskelainen J: Population-based analysis of sporadic and type 2 neurofibromatosis-associated meningiomas and schwannomas. *Neurology* 2000, 54:71-76
- [7]. Striedinger K, VandenBerg SR, Baia GS, McDermott MW, Gutmann DH, Lal A. The neurofibromatosis 2 tumor suppressor gene product, merlin, regulates human meningioma cell growth by signaling through YAP. *Neoplasia* 2008;10(11):1204-12.
- [8]. Rouleau GA, Wertelecki W, Haines JL, Hobbs WJ, Trofatter JA, Seizinger BR, et al.: Genetic linkage of bilateral acoustic neurofibromatosis to a DNA marker on chromosome 22. *Nature* 1987, 329:246-248.
- [9]. Chen AF, Samy RN, Gantz BJ. Cerebellopontine angle tumor composed of Schwann and meningeal proliferations. *Arch Otolaryngol Head Neck Surg* 2001;127:1385-9.
- [10]. Asthagiri AR, Parry DM, Butman JA, Kim HJ, Tsilou ET, Zhuang Z, et al. Neurofibromatosis type 2. *Lancet* 2009;373(9679):1974-86.
- [11]. Mautner VF, Baser ME, Thakkar SD, Feigen UM, Friedman JM, Kluwe L. Vestibular schwannoma growth in patients with neurofibromatosis Type 2: a longitudinal study. *J Neurosurg* 2002;96(2):223-8.
- [12]. Walter J, Kuhn SA, Brodhun M, Reichart R, Kalff R. "Pulmonary meningioma and neurinoma associated with multiple CNS tumours in a patient with neurofibromatosis type 2". *Clin Neurol Neurosurg* 2009;111:454-9.
- [13]. Stumpf DA, Alksne JF, Annegers JF. Neurofibromatosis. Conference statement. National Institutes of Health Consensus Development Conference. *Arch Neurol* 1988;45(5):575-8.
- [14]. Gutmann DH, Aylsworth A, Carey JC, Korf B, Marks J, Pyeritz RE, et al. The diagnostic evaluation and multidisciplinary management of neurofibromatosis 1 and neurofibromatosis 2. *JAMA* 1997;278(1):51-7.
- [15]. National Institutes of Health Consensus Development Conference Statement on Acoustic Neuroma, December 11-13, 1991. The Consensus Development Panel. *Arch Neurol* 1994;51(2):201-7.
- [16]. Mautner VF, Tatagiba M, Guthoff R, Samii M, Pulst SM. Neurofibromatosis 2 in the pediatric age group. *Neurosurgery* 1993;33(1):92-6.
- [17]. Baser ME, Friedman JM, et al. Empirical development of improved diagnostic criteria for neurofibromatosis 2. *Genet. Med.* 2011 Jun;13(6):576-81.
- [18]. Mautner VF, Lindenau M, Baser ME, Hazim W, Tatagiba M, Haase W, et al.: The neuroimaging and clinical spectrum of neurofibromatosis 2. *Neurosurgery* 1996, 38:880-885.
- [19]. Aoki S, Barkovich AJ, Nishimura K, Kjos BO, Machida T, Cogen P, et al.: Neurofibromatosis types 1 and 2: cranial MR findings. *Radiology* 1989, 172:527-534.
- [20]. Odat HA, Piccirillo E, Sequino G, Taibah A, Sanna M. Management strategy of vestibular schwannoma in neurofibromatosis type 2. *Otol Neurotol* 2011;32(7):1163-70.
- [21]. Roehm PC, Mallen-St Clair J, Jethanamest D, Golfinos JG, Shapiro W, Waltzman S, et al. Auditory rehabilitation of patients with neurofibromatosis Type 2 by using cochlear implants. *J Neurosurg* 2011;115(4):827-34.
- [22]. Lustig LR, Yeagle J, Driscoll CL, Blevins N, Francis H, Niparko JK. Cochlear implantation in patients with neurofibromatosis type 2 and bilateral vestibular schwannoma. *Otol Neurotol* 2006;27(4):512-8.
- [23]. Bento RF, Brito Neto RV, Tsuji RK, Gomes MQ, Goffi-Gomez MV. Auditory Brainstem Implant: surgical technique and early audiological results in patients with neurofibromatosis type 2. *Braz J Otorhinolaryngol* 2008;74(5):647-51.

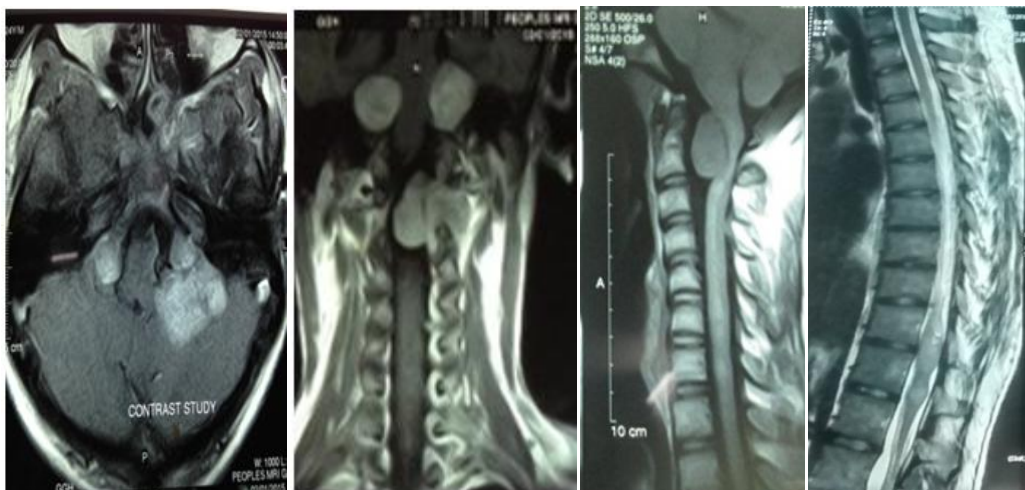

Figure:1

Figure:2

Figure:3

Figure:4

Figure:1,2,3 Showing bilateral eighth nerve schwannomas and Foramen magnum Meningioma.
Figure:4 Showing Dorsal Ependymoma.

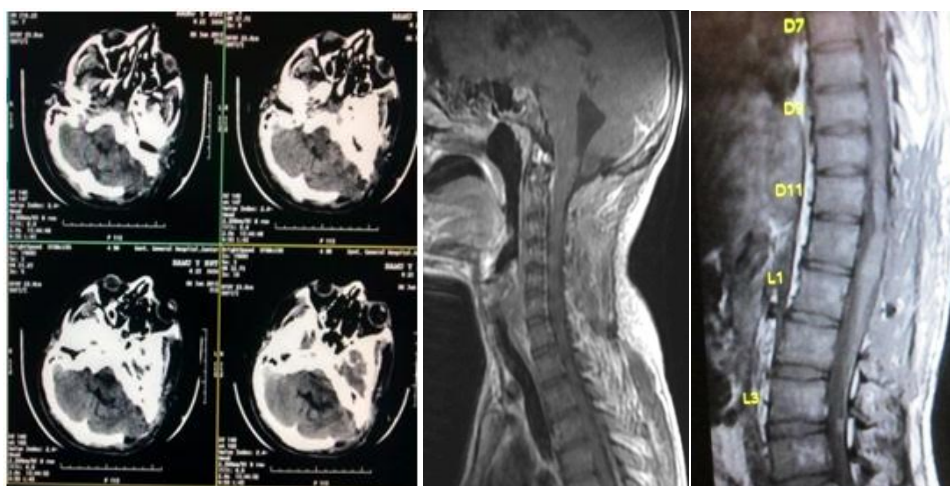


Figure:5

Figure:6

Figure:7

Figure:5,6,7 showing post operative images after excision of tumours

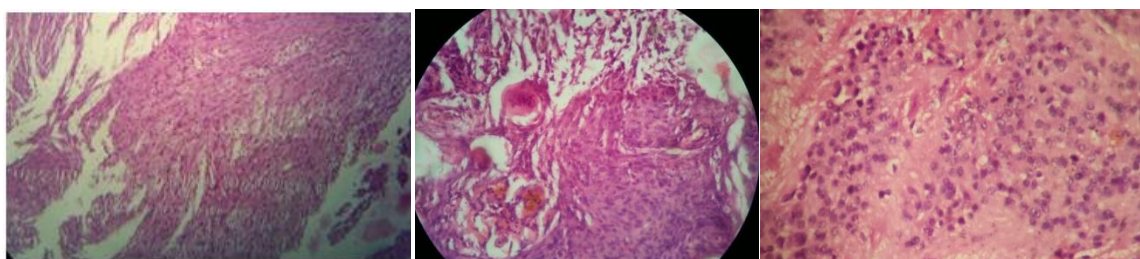


Figure:8

Figure:9

Figure:10

Figure:8,9,10 showing HPE of left eighth nerve schwannoma, Foramen magnum Meningioma and Dorsal Ependymoma respectively.