

A Comparative Study between External Dacryocystorhinostomy and Transcanalicular Laser Dacryocystorhinostomy

Dr. Phani Kumar Sarkar¹, Dr. Saumya Haldar², Dr. Umakanta Acharjee², Dr. Sandip Sarkar², Dr. Chiranjit Noatia³

¹Assoc. Prof, Dept. of Ophthalmology, Agartala Government Medical College, India

²PGT, Dept. Of Ophthalmology, Agartala Government Medical College, India

³Medical Officer, Tripura Health Service

Abstract

Background: Dacryocystitis is the inflammation of the lacrimal sac due to nasolacrimal duct obstruction. Chronic dacryocystitis is a constant threat to cornea and orbital soft tissue. Surgery is the mainstay for its treatment. The gold standard procedure of choice for the treatment of epiphora is Dacryocystorhinostomy (DCR). This study proposes to evaluate and compare the surgical outcome of External DCR and Transcanalicular laser DCR (TC- DCR).

Methods: An Open Level Randomized Clinical Trial study was conducted from December 2013 to May 2015. 80 diagnosed cases of chronic dacryocystitis were randomized into two groups, External DCR and TC- DCR groups. Each of them included 40 patients.

Results: Out of 80 patients majority of them were females (77.5%). Mean age was 36.25 years. Duration of operation was about 20 minutes for External DCR and 12 minutes for TC- DCR. No major complications occurred intraoperatively except bleeding in some cases of External DCR. The average duration of stay after External DCR was 2 days, while that of TC- DCR was day care. Two patients developed epistaxis after External DCR. One patient had epistaxis after 1 week and another after 1 month. No major complications were noted after TC- DCR. After 3 months, the nasolacrimal duct, 35 out of 40 patients were patent in External DCR group, out of which 1 patient was partially patent and in another patient was patent through upper punctum. While TC- DCR group showed 33 patients were patent, out of which 1 patient was partially patent and 2 patients were patent through upper punctum. Epiphora was seen in 10 patients in External DCR group and 11 patients in TC- DCR group. After 3 months, success rate in External DCR was 88.5% and that in TC- DCR was 82.5% ($p = 0.279$), which was not statistically significant.

Conclusion: Transcanalicular laser DCR is a relatively new procedure. Its advantages are no external scar formation and less collateral tissue damage. But it has certain disadvantages like higher cost and steeper learning curve. TC DCR also has a shorter duration of surgery, less complication, repeatable and shorter patient recovery time. So it can be a good alternative to External DCR. However it depends upon the preference of the patient, resource available and the surgeon himself to decide the right surgical option to axe the disease.

Keywords: Dacryocystitis, External Dacryocystorhinostomy, Transcanalicular laser DCR, Diode laser, Endoscope

I. Introduction

Inflammation of the lacrimal sac is known as dacryocystitis. It generally affects two age groups, infants and adult females. While acquired dacryocystitis may be acute, sub acute or chronic. Approximately 40% of initial attacks do not recur, but in the 60% of patients, repeated attacks occur. ^[1] Chronic dacryocystitis is commonly attributed to the effects of stricture of the nasal duct arising from chronic inflammation, usually of nasal origin. A common organism involved is *Staphylococcus aureus*. ^[2] Chronic dacryocystitis is characterized by persistent epiphora and regurgitation of mucoid or mucopurulent material on pressure over the sac area. In some cases the sac becomes distended and appears as a cystic swelling below the medial palpebral ligament; this is called mucocele. Occasionally, the opening of common canaliculus into the sac gets blocked because of kinking of the lateral end of common canaliculus; resulting in formation of an encysted mucocele. ^[3] Dacryocystorhinostomy (DCR) is indicated for obstruction beyond the medial opening of the common canaliculus. The operation involves anatomising the lacrimal sac to the nasal mucosa of the middle nasal meatus. The procedure usually performed under hypotensive general anaesthesia or local anaesthesia. ^[4] DCR can be done by various techniques, mainly external & laser assisted DCR. Laser DCR can be endonasal or transcanalicular laser DCR.

Transcanalicular laser DCR (TC–DCR) is a relatively new procedure. This approach was first described by Jack in 1963. ^[5] In this procedure, a probe is inserted through the punctum via the canaliculus into the lacrimal sac following the anatomical pathway of tear outflow. Osteotomy is performed by laser energy

through an optic fibre which is inserted within the probe. It has to be ensured that the aiming beam is at the brightest and is not scattered. Laser is fired only after confirmation in short pulses with equal gap intervals. [6]

Various studies were done to compare External DCR with TC-DCR. However, all these studies recommended long term studies necessary to validate the results. Epiphora, being a common cause of morbidity in the north eastern part of India, along with no pioneer study to compare the results of the two proposed procedures, so the studies proposes to elucidate the effectiveness between external DCR and TC- DCR. So the purpose of the study is to find out whether transcanalicular laser DCR is better than external DCR or not.

II. Materials And Methods

This study was an Open Level Randomized Clinical Trial study done with patients with diagnosis of Nasolacrimal Duct obstruction presenting at Out Patient Department of Department of Ophthalmology, Agartala Government Medical College, Agartala for a period of One and half years, from May 2013 to November 2015. All symptomatic cases of epiphora which were diagnosed as NLD obstruction and who had given consent for surgery were included in the study. However, patients with lower lid laxity, nasal pathologies like atrophic rhinitis, gross DNS, polyps, lacrimal sac abnormalities such as large abscess in lacrimal sac, dacryoliths and lacrimal sac tumours, fibrotic lacrimal sac, any suspicious intranasal malignancy, any previous oro-facial radiation therapy, or having uncontrolled diabetics & hypertension were excluded from the study.

Each patient was subjected to detailed history taking followed by ocular and adnexal examination as per a pre designed performa. Detailed history was taken about the epiphora, its duration, nature, any associated pain, itching and any history of recurrent episodes. The eyelids were examined for ectropion, entropion and lid laxity. Examination of the puncti for the normal location and size were evaluated. Any medial canthi swelling were noted. Nasolacrimal duct obstruction was diagnosed by regurgitation of fluid into the conjunctival sac by applying pressure over the lacrimal sac area. Lacrimal syringing was done to determine patency of the lacrimal apparatus and to determine hard stop and soft stop when syringing was not patent. An ENT surgeon conducted a thorough anterior rhinoscopy and any abnormality like a deviated nasal septum; hypertrophied turbinates, polyposis etc were looked for.

A panel of investigations including complete haemogram, blood sugar, bleeding and clotting time, HbSag, ECG, X ray Paranasal sinus (Water's view) was done for all patients. All patients had a preoperative counselling & both procedures were explained in details with advantages & disadvantages. Written consent was taken and preparation of local parts was performed. Patients were advised to use Oxymetazoline (0.05%) nasal drop in both nostrils and antibiotic eye drop in diseased eye for 3 days prior to the surgery. Surgery, externally or transcanalicular was done by a single surgeon.

Technique of External Dacryocystorhinostomy

All the surgeries were performed under local anaesthesia. Inj Xylocaine with adrenaline (1: 100,000) of about 6 ml was infiltrated at superior and inferior orbital notch and sub periostally over the incision site. Anterior nasal packing with Xylocaine, Adrenaline and Oxymetazoline was done. Curvilinear incision was given at 8 mm medial to medial canthus measuring 6 – 7 mm. Blunt dissection of orbicularis oculi was done to expose and identify the medial palpebral ligament (MPL) and dissection was continued to expose the lacrimal fascia. It was dissected to expose the lacrimal sac in the lacrimal fossa. Then Nettleship punctum dilator was used to dilate the lower punctum and Bowman's probe was inserted through the lower punctum to identify the sac. After that anterior flaps were made by giving a U- shaped incision over the sac. A bony ostium measuring 15 mm x 10 mm was made over the lacrimal bone by Bone punch to expose the nasal mucosa. Anterior U - shaped flaps were made over the nasal mucosa in similar fashion. The anterior flaps of lacrimal sac and nasal mucosa were sutured by Vicryl (6-0). Orbicularis oculi was sutured by vicryl (6-0) and skin was closed by Mersilk (6-0). The duration of the surgery was measured from skin incision to closure of skin.

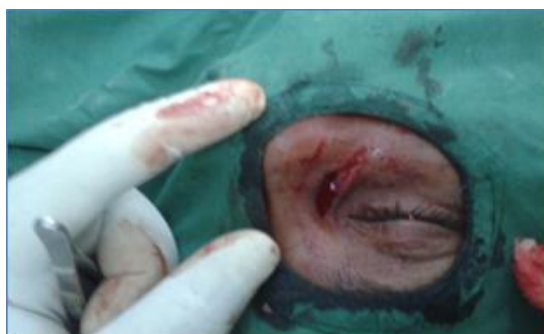

fig. 1: intra operative picture of a patient undergoing external dcr

Technique of Transcanalicular Laser Dcr

Local anesthesia and anterior nasal packing was similar to that of external DCR. Punctum was dilated by Nettleship punctum dilator of variable diameters in increasing order until adequate dilatation was achieved. Then Bowman's probe was inserted through the punctum. Lacrimal bone was felt to determine the hard stop. Now the Fiberoptic probe of the Semiconductor infrared Diode 980 nm Laser was inserted through the punctum. The probe had a red light in front of it. The nasal pack was removed and the endoscope was focused near middle turbinate to see the glow from the probe. After confirming the position of the laser probe, laser was delivered at a repeated pulse mode. The settings of the diode laser machine were 12 mW power, 0.2 seconds repetition time and 0.2 seconds pulse duration. Gradually there was charring of tissues. The suction tube was also inserted when needed to clear the nasal mucous and debris that was formed by charring of the tissue. The laser was delivered in an intermittent fashion. A large ostium of about 15 mm x 10 mm was created. After attaining satisfactory sized ostium, syringing was done on table to check the patency. The wound was inspected by endoscope. The duration of surgery was measured from insertion of punctum dilator to intraoperative syringing.

All the patients were followed up at first week, one month and three months after surgery. Syringing was done during each visit in every patient. However endoscopy was performed through nostril in TC DCR patients to inspect the ostium. Any mucous plugs or blood clots found obstructing the ostium were removed with the help of Tilley's forceps and suction.

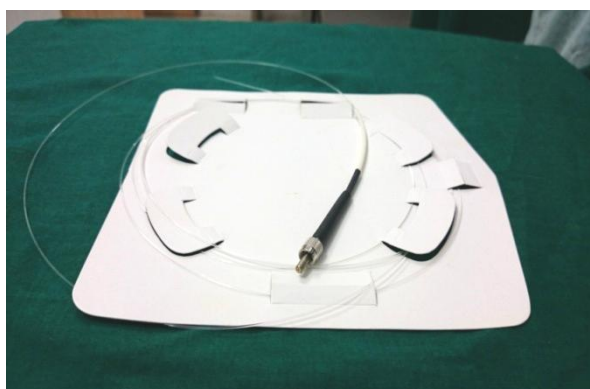


fig 2: fibre- optic laser probe



fig 3: diode laser (980 nm) machine.



fig 4: endoscope probe

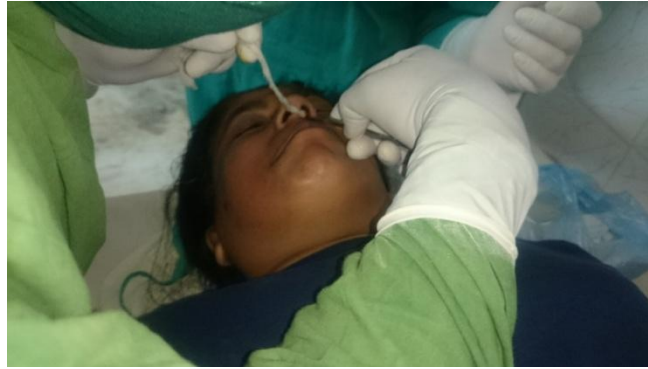

fig 5: anterior nasal packing given before surgery

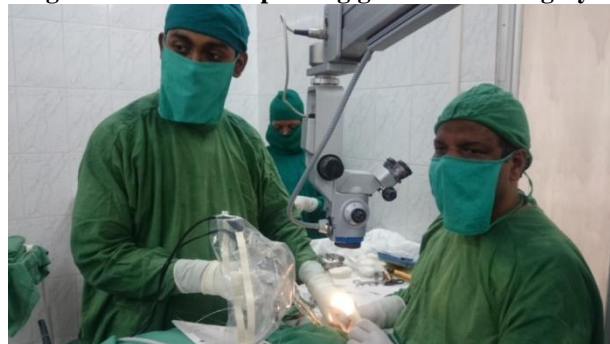

fig 6: dr. phani sarkar performing tc dcr.

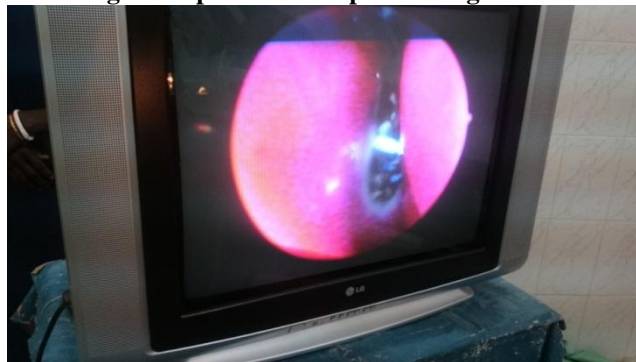


fig 7: creation of ostium over nasal mucosa by the laser probe

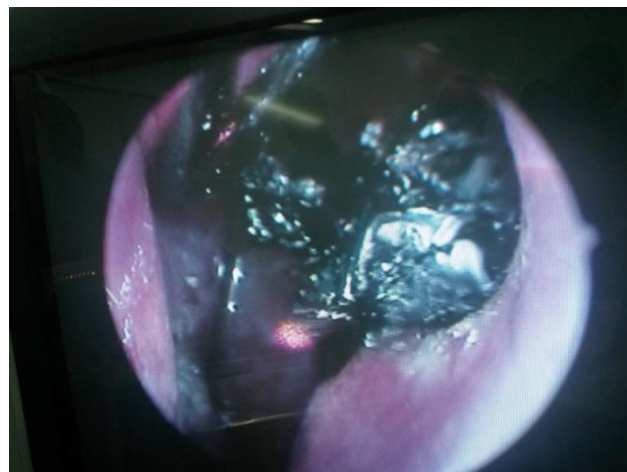


fig 8: charring of tissues with formation of large ostium indicating end point of surgery

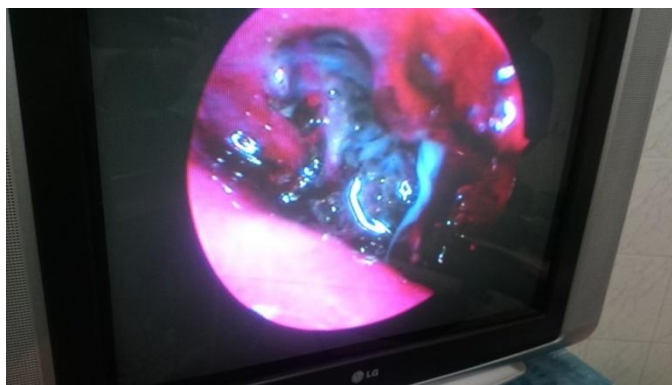


fig 9: passage of water by syringing at the end of surgery to check patency

III. Results

A total of 80 patients were included in the study. 18 patients (22.5%) were male and 62 patients (77.5%) were female. The age of the patients varied from 14 years to 66 years. Mean age being 36.76 years.

Table 1: Sex distribution

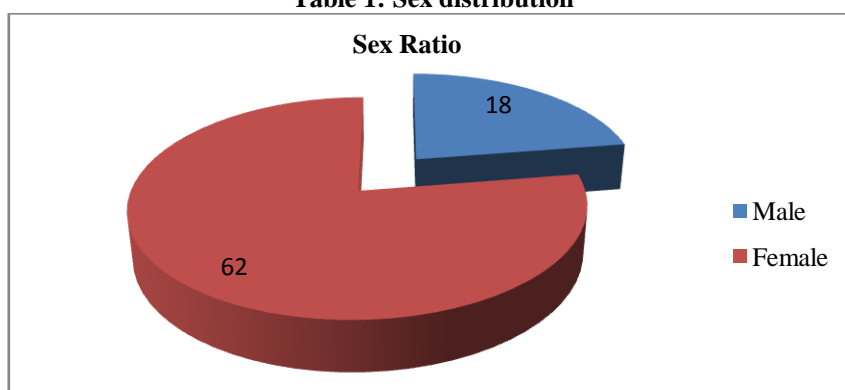
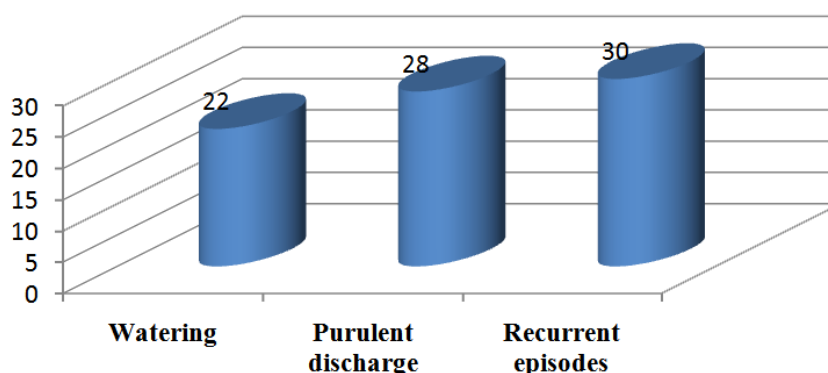


Table 2: Age distribution

Age Distribution	Number Of Patients
10 – 20 years	6
21 – 30 years	16
31 – 40 years	29
41 – 50 years	23
51 – 60 years	4
61 – 70 years	2

Out of 80 patients, 22 patients (27.50%) complained of only watering from the eye, not associated with purulent discharge and no history of acute episodes. 28 patients (35%) complained of watering associated with purulent discharge occasionally. 30 patients (37.5%) complained of watering with history of recurrent episodes of acute on chronic dacryocystitis. The duration of symptoms varied between 1 year to 15 years.

Table 3: Complains of patients



Intraoperative duration of External DCR was about 20 minutes and that of TC- DCR was about 12 minutes. No major intraoperative complications were noted in both the procedures. Duration of hospital stay was on an average of 2 days in External DCR and day care in TC DCR. In case of External DCR, after 3 months, out of 40 patients, syringing test showed, 32 patients were patent, 3 patients were partially patent and 5 patients were blocked. Epiphora was present in 10 patients.

Table 4: Syringing after 3 months (external DCR)

Syringing Test (Ext DCR)	No. of Patients
Patent	32
Partially Patent	3
Patent through upper punctum	0
Blocked	5

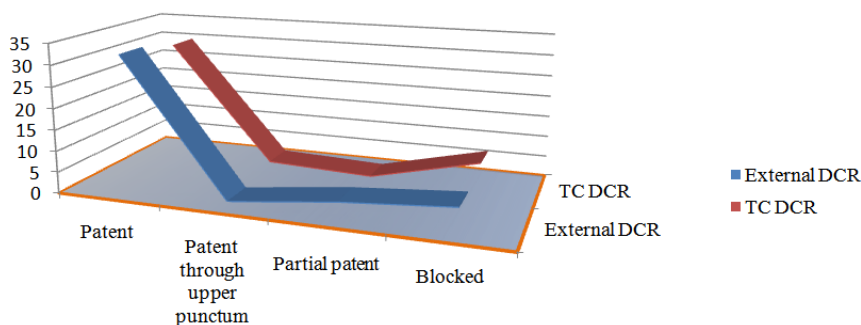
In case of TC- DCR, at the end of 3 months, syringing test showed, out of 40 patients, 30 patients were patent, 2 patients were patent through upper punctum, 1 patient was partially patent and 7 patients were blocked. Epiphora was present in 11 patients.

Table 5: Syringing after 3 months (TC- DCR)

Syringing Test (TC- DCR)	No. of Patients
Patent	30
Partially Patent	1
Patent through upper punctum	2
Blocked	7

Table 6: Results after 3 months

Procedure	Three Months syringing				Total
	Blocked	Partially Patent	Patent	Patent Through upper punctum	
Ext DCR	5	3	32	0	40
TC DCR	8	1	29	2	40
Total	13	4	61	2	80



It was found that success rate of External DCR was 87.5% and that of Transcanalicular laser DCR was 82.5% (p = 0.279).

Chi-Square Tests			
	Value	df	Asymp. Sig. (2-sided)
Pearson Chi-Square	3.840 ^a	3	.279
Likelihood Ratio	4.665	3	.198
N of Valid Cases	80		

IV. Discussion

The aim of development in the field of DCR is to shorten the procedure time, to shorten patient's recovery period, to decrease complication rate, to avoid surgical skin and mucosal scars and to make the procedure possible on an outpatient basis, under local anaesthesia. On the other hand, Toti's [7] classic external approach with a 90–95 % success rate remains the golden standard, compared to the 70–80 % success rate of transcanalicular laser DCR.

TCL-DCR is a minimally invasive surgical procedure. It takes advantage of accessing the operating field through anatomic pathways – the lacrimal canaliculus. This contributes greatly to minimizing trauma to the surrounding tissue and avoiding unnecessary surgical skin scars. However, as in all endoscopic surgeries, the surgeon must have mastered the classical approach first, to be able to use it in the case of intraoperative complications.

Of course, there are certain disadvantages of this procedure such as careful handling of the laser and its cost. All the patients were advised to undergo treatment for nasal pathology first.

We included 80 patients in our study. 18 (22.5%) patients were male and 62 (77.5%) were female. The female preponderance is in accordance to other studies. Our study showed that age of the patients varied from 14 years to 66 years. Mean age of our study was 36.76 years, with standard deviation being 10.963.

In our study syringing was done to determine any obstruction in lacrimal passage. The average duration taken to perform external DCR by us was about 20 minutes and TC DCR was taken about 12 minutes. Tasciran Comez et al found that the duration of the operation was 22.2 ± 4.8 minutes for TC DCR, while it was 56.3 ± 15.7 minutes for External DCR ($P=0.0001$)^[8]. Gupta et al took at an average of 7 minutes (range 5 minutes to 18 minutes) to perform TC DCR^[9]. Nuhoglu F et al performed TC DCR in 13.4 ± 5.3 minutes (range 9 minutes to 21 minutes)^[10]. Drnovsek-Olup et al, in their study, took an average of 12 minutes to perform laser DCR^[11]. Our study is comparable to most of the literatures.

In our study we used diode laser of 980 nm wavelength. Nuhoglu F et al^[10], Drnovsek B et al^[11] and Kanyak P et al^[12] used 980 nm diode laser in their studies. Al-Asadi et al used 812 nm diode laser^[13]. Gupta et al used 810 nm diode laser in their study^[9]. In our study, the osteotomy created by external DCR and TC- DCR was about 15 mm x 10 mm. We did not inserted silicone tubes in any of the procedures. Nuhoglu F et al mentioned the size of the osteotomy created with the help of 810 nm diode laser was > 4 mm. It was comparable to our study. Intraoperative bleeding in TC DCR in our cases was minimal as compared to external DCR. Apart from that no major intraoperative complications were noted in both the procedures.

After the operation, the patients who had undergone External DCR received parenteral antibiotics for 2 days and then shifted to oral formulation for another 5 days. They also received tablet NSAIDs and topical antibiotics drops and ointment for 2 weeks. The patients who had undergone TC DCR received oral formulation for 5 days, anti inflammatory tablets, anti allergic tablets for 5 days and topical antibiotic with steroid combination drops for 10 days. Anti allergic tablets were given to prevent epistaxis. The duration of stay in hospital for external DCR was at an average of 2 days, with a maximum of 5 days in some patients and that of TC DCR was at an average day care with a maximum of 2 days in some patients.

The patients were followed up at day 1, 1st week, 1st month and 3rd month after the respective procedures. In case of TC DCR, nasal cavity and the ostium were examined with the help of the endoscope. Any crust or charred tissue was removed with the help of Tilley's forceps and suction cannula. Yeniad et al followed up the patients at 1 week, 1 month and 3 months after surgery^[14]. In a study by Derya K et al the mean follow up times were 8.82 ± 5.1 months (range 3 – 18 months) and 7.12 ± 2.96 months (range 2 – 12 months) respectively for both external DCR and TC DCR groups^[15]. Al-Asadi et al followed up the patients for an average of 6 months^[13]. The mean duration of follow up by and by Drnovsek-Olup et al was 6 months^[11]. The duration of follow up was little less in our study.

In External DCR group, 2 patients had epistaxis postoperatively, of which 1 patient developed epistaxis 1 month after the surgery due to sneezing. Bruising, wound infection, cerebrospinal fluid leaking, punctal eversion, inadvertent incision of periorbital tissues which are known complications of external DCR mentioned in various studies had not been reported in our study^[16]. TC- DCR group had no significant complications.

Success rates of External DCR and TC- DCR groups were found to be 87.5% and 82.5% respectively. This study was done in medium settings. So this success rates may vary when it will be done in large settings. Nuhoglu F et al found out that there was 91.8% success rate in TC-DCR group and 93.4% success rate in external DCR group^[10]. Pal VK, Agarwal A *et al* concluded that external DCR has a high success rate (93-95%) than TC DCR^[17]. Yeniad B et al, in their study, found no significant difference was found between external DCR and TC- DCR^[14]. Suranagi MD et al found out in their study that success rate was 93.4% in external DCR and 92.2% in TC- DCR^[18].

Our study was similar to the literature as we found that external DCR was successful marginally. However, most of the studies found no statistical difference in between the two procedures. All the studies showed that TC DCR required less intraoperative time, short duration of stay in hospital, had less complications, much less morbidity and most importantly no external scar when compared to external DCR. Some of the studies concluded that the less success rate of TC DCR may be attributed to closure of the osteotomy by crusts, allergic rhinitis and unsuitable passage for endoscopic surgery. They also concluded that as it is a relatively new procedure and needs a learning curve, the success rate is hampered.

V. Conclusion

Transcanalicular laser DCR is a relatively new procedure. Its advantages are no external scar formation and less collateral tissue damage. But it has certain disadvantages like higher cost and steeper learning curve. Various studies, comparing TC DCR with External DCR, concluded that external DCR still remains the gold standard in terms of better success rate. But the difference is statistically insignificant. They found TC DCR also

has a shorter duration of surgery, less complications, repeatable and shorter patient recovery time. So it can be a good alternative to External DCR. However everything depends upon the preference of the patient, resource available and the surgeon himself to decide the right surgical option to axe the disease.

References

- [1]. Sihota R, Tandon R. Parsons' Disease of the Eye. 21st edition, New Delhi: Elsevier; 2011. Diseases of the Lacrimal Apparatus; p462-469.
- [2]. Hurwitz JJ. The lacrimal drainage system. In: Yanoff M, Duker JS. Ophthalmology. 3rd edition, Philadelphia: Mosby Elsevier; 2009. P1482-1487.
- [3]. Dutta LC, Dutta KN. Modern Ophthalmology vol 2. 3rd Edition, New Delhi: Jaypee Brothers; 2005. Anatomy Physiology and Diseases of the Lacrimal System; p 718-724.
- [4]. Kanski JJ, Bowling B, Nischal K, Pearson A . Clinical Ophthalmology A Systemic Approach. 7th edition, Edinburg: Elsevier Saunders; 2011. Lacrimal drainage system; p 65-78.
- [5]. Jack MK. Dacryocystorhinostomy. Description of a Transcanalicular Method. Am J Ophthalmol 1963; 56: 974-7.
- [6]. Haefliger IO, Piffaretti JM. Lacrimal drainage system endoscopic examination and surgery through the lacrimal punctum, Klin Monatsbl Augenheilkd 2001; 218: 384-7.
- [7]. Isloor SD. External, Conventional or Percutaneous Dacryocystorhinostomy. In Lacrimal drainage surgery. First edition, New Delhi: Jaypee Brothers; 2014. P 30-31.
- [8]. Taşkıran Çömez A¹, Karadağ O, Arkan S, Gencer B, Kara S. Comparison of transcanalicular diode laser dacryocystorhinostomy and external dacryocystorhinostomy in patients with primary acquired nasolacrimal duct obstruction. Lasers Surg Med. 2014 Apr;46(4):275-80.
- [9]. Gupta KS et al. Transcanalicular laser dacryocystorhinostomy using low energy 810 nm diode laser. Oman J Ophthalmol. 2012 Sep-Dec; 5(3): 171–174.
- [10]. Nuhoglu F, Eltutar K. Long Term Outcomes of Transcanalicular Laser and External Dacryocystorhinostomy Poster Details. Acta Otorhinolaryngol Ital 2012 August; 32(4): 258-262.
- [11]. Dmovšek-Olup. B, Beltram M. Transcanalicular diode laser-assisted Dacryocystorhinostomy. Indian J Ophthalmol. 2010 May-Jun; 58(3): 213–217.
- [12]. Kanyak P et al. Transcanalicular diode laser assisted dacryocystorhinostomy in primary acquired nasolacrimal duct obstruction: 2-year follow up. Ophthal Plast Reconstr Surg. 2014 Jan-Feb;30(1):28-33.
- [13]. Al Asadi SZ et al. Efficacy of Diode laser Transcanalicular Dacryo cysto rhinostomy in Acquired Nasolacrimal Duct Obstruction. Gomal Journal of Medical Sciences. July- December 2011; 9: 152-155.
- [14]. Yeniad B, Uludag G, Kozar-Bilgin L. Assessment of patient satisfaction following external versus transcanalicular dacryocystorhinostomy with a diode laser and evaluation if change in quality of life after simultaneous bilateral surgery in patients with bilateral nasolacrimal duct obstruction. Curr Eye Res 2012 Apr; 37(4) :286-92.
- [15]. Derya K, Demirel S, Doganay S, Orman G, Cumurcu T, Gunduz A. Endoscopic transcanalicular diode laser dacryocystorhinostomy is it an alternative method to conventional external dacryo cystorhinostomy. Ophthal Plast Reconstr Surg 2013 Jan; 29(1): 15-7.
- [16]. Dolman PJ. Comparison of external Dacryocystorhinostomy with nonlaser endonasal dacryocystorhinostomy. Ophthalmology. 2003; 110:78–84
- [17]. Pal VK, Agarwal A, Suman S, Pratap VB,. Transcanalicular Endoscope Combined Laser Assisted Dacryocystorhinostomy. Del J Ophthalmol. 2012; 23(4): 271-274.
- [18]. Damayanti M. Suranagi, B. I. Mirajkar, A. V. Revankar, Madhuri Parande. "A Comparative Study of Success Rate and Complications of External Dacryocystorhinostomy and Laser Assisted Dacryocystorhinostomy". Journal of Evidence based Medicine and Healthcare; Volume 2, Issue 16, April 20, 2015; Page: 2232-2235.