

Extranasal Presentation of Juvenile Nasopharyngeal Angiofibroma - A Case Report and Literature Review

Vibhu Garg¹, Shashank Mishra², Sandeep Kansal³, Rohit Kamboj⁴,
Y.P.Monga⁵, Akshay Baid⁶, Garima Jain⁷, Ruchi Tyagi⁸

^{1,6}Resident,

²Associate Professor,

^{3,4}Assistant Professor,

⁵Professor and Head, Department of General Surgery, Subharti Medical College, Meerut U.P., India

⁷Resident, Department of Radiodiagnosis and Imaging, Subharti Medical College, Meerut U.P., India

⁸Assistant Professor, Department of Physiology, Subharti Medical College, Meerut U.P., India

Abstract: Juvenile nasopharyngeal angiofibroma is a locally aggressive benign vascular neoplasm, composed of vasogenic and myofibroblastic elements, accounts for 0.05–0.5% of all the head and neck neoplasms. There are very few case reports of nasopharyngeal angiofibroma involving the oral cavity; we report a case involving both the maxilla and mandible in a 12-year-old patient who reported with a large firm swelling on left side of face with recurrent epistaxis. The contrast CT showed a large multilobulated soft tissue mass epicentered in the left sinonasal cavity with extension into left parapharyngeal space postero-laterally, into the middle cranial fossa, sphenoid sinus and cavernous sinus superiorly, posterior nasopharynx posteriorly, oral cavity inferiorly, infratemporal and masticator space laterally and also submandibular space. It was supplied by the right external carotid artery. Open surgical excision of the mass was done. The diagnosis at an early stage is important because it is associated with high risk of morbidity, but advances in imaging, and surgical methods of treatment have changed the outcome of this rare disease.

Keywords: Computed Tomography(CT), Juvenile nasopharyngeal angiofibroma, Vascular neoplasm, Sphenopalatine foramen, Embolisation.

I. Introduction

Hippocrates described this tumor in the 5th century BC, but Friedberg first used the term angiofibroma in 1940.[1] Juvenile nasopharyngeal angiofibroma (JNA) is a relatively rare tumor with an incidence of between 1:6000 and 1:55,000 of the population[2] and occur almost exclusively in male adolescent.[3] It invades the natural foramina and fissures usually present in the nasopharyngeal region.[4,5,6] The patients of nasopharyngeal angiofibroma presents with classical triad of epistaxis, unilateral nasal obstruction and a mass in the nasopharynx suggesting a diagnosis of nasopharyngeal angiofibroma and is supplemented by imaging.[3,7] Imaging such as computed tomography (CT), nuclear magnetic resonance, angiography and even nasal endoscopy clearly establishes the extent of tumor, its pattern of spread and consequently surgical planning.[8] Several classification methods based on CT, magnetic resonance imaging (MRI) and endoscopy have been employed to stage the tumor and assist in choosing the appropriate treatment. These include those developed by Radkowski (1996), Fisch (1983), Andrews (1989), Chandler (1984), although none is universally accepted.[9] But the classification by Fisch is mostly followed[3]

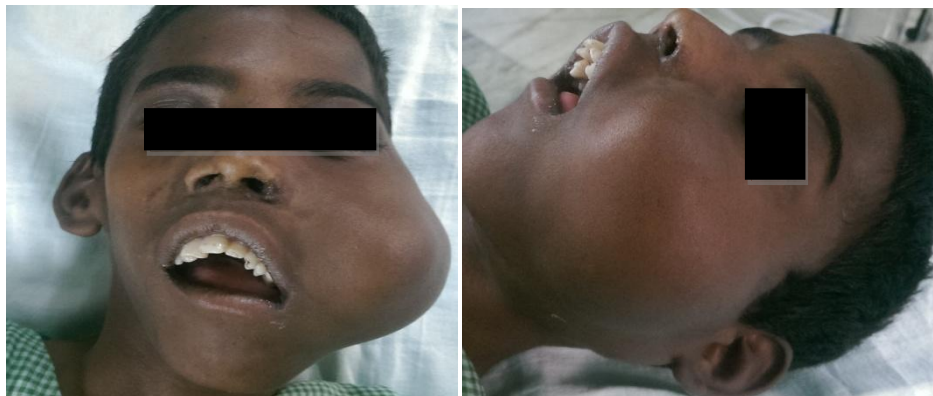Classification of Fisch

- Type I: The tumor is limited to the sphenopalatine foramen, nasopharynx, and nasal cavity without bone destruction.
- Type II: The tumor invades the nasal sinuses or the pterygomaxillary fossa with bone destruction.
- Type IIIa: The tumor invades the infratemporal fossa or orbit without intracranial involvement.
- Type IIIb: The tumor invades the infratemporal fossa or orbit with intracranial extradural commitment.
- Type IVa: The tumor shows intracranial extradural and/or intradural invasion, without invasion of the optic nerve, sella, or cavernous sinus.
- Type IVb: The tumor shows intracranial extradural and intradural invasion, with invasion of the optic nerve, sella, and/or cavernous sinus.

Here, we are reporting a case of JNA in a 12-year-old male presenting as an extraoral facial swelling with stage IIIb and reviews the pathogenesis and role of imaging in the diagnosis of the tumor and surgical management done for the same are discussed.

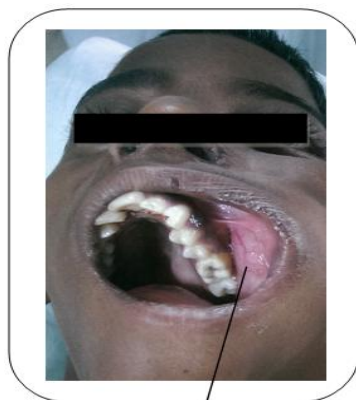II. Case Report

A 12 year old male child presented to us with complaint of progressively increasing non painful mass over left side of cheek and nasal blockage with few episodes of nasal bleeding from 2 years. It was followed by facial deformity and persistent nasal discharge and snoring from last 1 ½ years. Speech of the patient was also disturbed because of the mass and patient was not able to close his left eye completely. There was no history of fever, trauma, difficulty in breathing, difficulty in swallowing, headache, any visual disturbance. Physical general examination along with cranial nerve examination did not reveal any abnormality. Systemic examination of the patient was within normal limit. On local examination a well defined growth was present over left side of cheek around 20cm × 15cm in size. With irregular surface, nontender, firm in consistency, displacing the zygomatic bone, maxilla and mandible outwards. Mass was extending superiorly upto the outer canthus of eye with slight proptosis of left eyeball, inferiorly going beyond the mandible body and displacing it outwards. Medially mass was extending till the nasolabial folds and angle of mouth displacing the mouth towards right, laterally the mass was reaching in front of the tragus and extending beyond the ramus of mandible and displacing it outwards.(Picture 1,2)

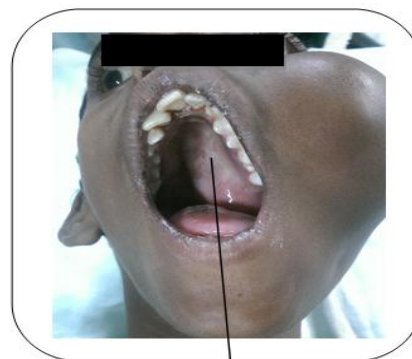

Picture 1: Showing lump on left side of cheek Picture 2: Lateral view of the lump

There was no movement of the mass and skin was freely mobile. Intraoral examination: Mass seen to be extending to the lateral side of the oral cavity, displacing the lateral side of the oral cavity, both hard and soft palate along with anterior and posterior faucial pillars. Surface was smooth, non tender, firm in consistency, without congestion of surface mucosa. Mucosa was freely mobile over the mass.(Picture 3,4)

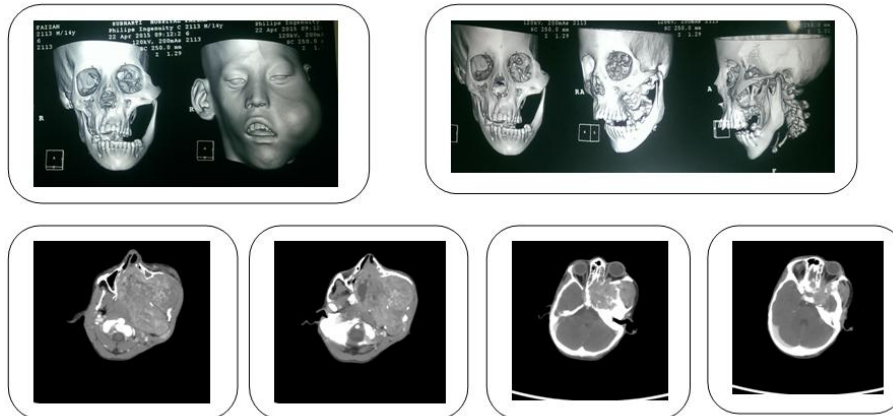


Picture 3: Intraoral extension of lump



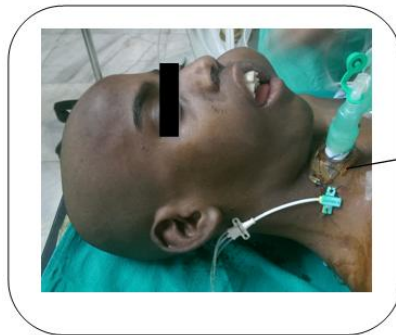Picture 4: Mass displacing the hard and soft palate

Nasal examination: Mass was extending inside the nasal cavity completely occluding it, with deviation of nasal septum towards right side and also occluding the right nasal cavity. Slight discharge present from left nostril with mucosal congestion. Patient was investigated and the routine blood examination was within normal limits. The CECT face showed a large multilobulated soft tissue mass epicentered in the left sinonasal cavity with extension into left parapharyngeal space postero-laterally, into the middle cranial fossa, sphenoid sinus and cavernous sinus superiorly, posterior nasopharynx posteriorly, oral cavity inferiorly, infratemporal and masticator space laterally and also submandibular space.(Picture 5)



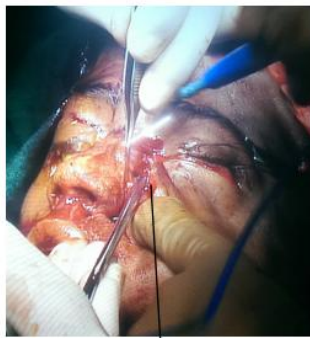Picture 5: CECT images with 3D reconstruction showing extent of the tumor

Biopsy of the patient was taken from intraoral route and it showed consistant with hamartoma of cheek. Patient was planned for excision by a team of neurosurgeon, plastic surgeon and ENT surgeon. A preoperative tracheostomy with central line placement was done.(Picture 6)

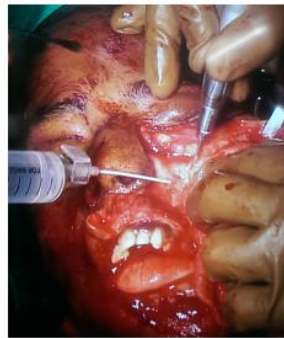

Picture 6: Preoperative thacheostomy and central line placement

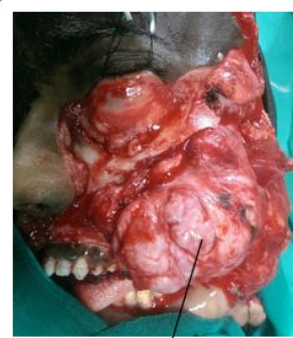Excision was done from left side Waber Ferguson incision lifting the left side of the face with extension to left temporal incision. Tumor was found under the facial muscles going beyond the mandibular borders , zygomatic arch and maxillary bone. Tumor was highly vascularised.(Picture 7,8,9)



Picture 7: Exposure by Waber ferguson incision

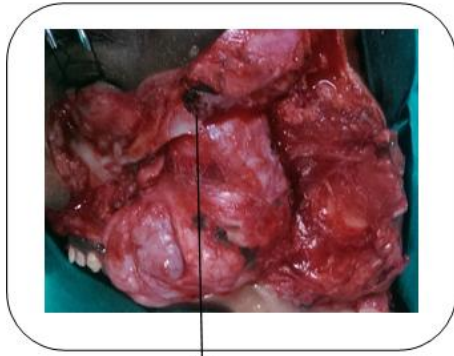


Picture 8: Exposing the tumor

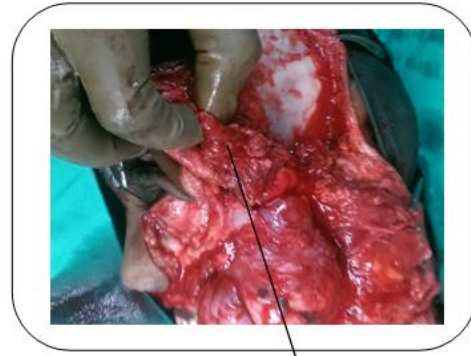


Picture 9: Tumor after exposure

Thinned out zygomatic arch was split for complete tumor exposure.(Picture 10,11)

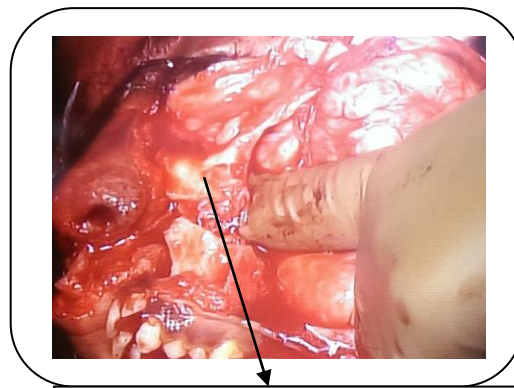


Picture 10: After splitting the zygomatic arch



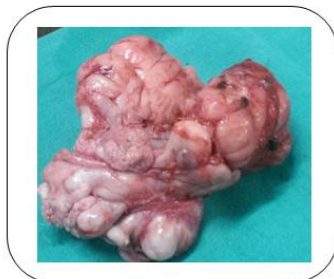Picture 11: Tumor exposure after zygomatic arch splitting

Left side Maxillary swing was done for accessing the deep parts of the tumor.(Picture 12)

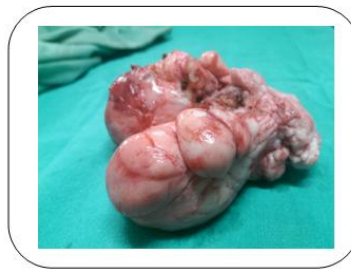

Picture 12: Picture showing left maxillary swing

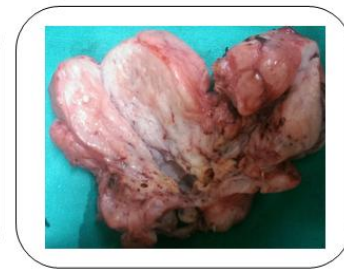Tumor was found to be attached to the nasopharynx and seems to arise from the same. Tumor was mobilised by dissection was found to be extending to the middle cranial fossa, eroding the cribriform plate. Tumor was carefully dissected from the middle cranial fossa and cavernous and sphenoid sinus with precaution of not opening the sinus. Tumor was excised as a single specimen and sent for histopathology.(Picture13,14,15)



Picture 13: Excised tumor

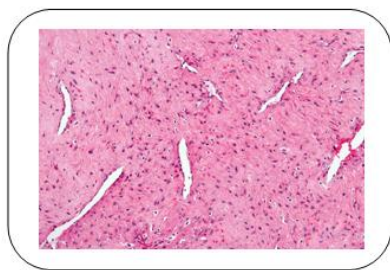


Picture 14: Excised tumor



Picture 15: Cut surface of excised tumor

The cavity left was packed and reconstruction was done. Patient tolerated the procedure well and Total duration of the surgery was 300 min. Histopathology report of the excised tumor was nasopharyngeal angiofibroma.(Picture16)



Picture 16: Microscopic picture of juvenile nasopharyngeal angiofibroma

III. Discussion And Literature Review

Angiofibroma is a relatively rare tumor.[2,5,10,11] JNAs are age and sex linked. It affects almost exclusively male adolescents with median age of 15 years; raising suspicion about the role of sexual hormones in its pathogenesis.[9] They originate predominantly in the posterolateral wall of the nasopharynx, specifically at the trifurcation of the sphenoidal process of the palatine bone, the horizontal process of the vomer and the roof of the pterygoid process.[1] Patients usually present at late stage of the disease with typical complaints of nasal obstruction and recurrent epistaxis and rarely as swelling on face. Extensive growth of tumor may cause facial swelling, proptosis, diplopia with disturbance in speech and conductive hearing loss.[9] In the present case also, the patient was a male, 12 years old who presented with the left facial swelling along with the classical triad of recurrent epistaxis, nasal stuffiness and discharge.

Although the origin is still disputed, the medical literature reveals several consistent features like involvement of sphenopalatine foramen, erosion of the base of pterygoid plate; and secondary involvement of the nasopharynx.[2] In separate studies, Brunner and Harrison found endothelial lined spaces in region of sphenopalatine foramen and base of pterygoid plates in male and female fetuses which suggests that JNA originates in a hamartomatous nidus of vascular tissue in the area of the sphenopalatine foramen that is stimulated by endogenous testosterone in early puberty.[2,12]

Lloyd *et al.*[13] reported three finding on CT and MRI imaging that should suggest a diagnosis of JNA:

1. A soft tissue mass in the nasopharynx or nasal cavity
2. A mass in the pterygopalatine fossa
3. Erosion of posterior osseous margin of the sphenopalatine foramen extending to the base of the medial pterygoid plate.

Angiofibroma can be diagnosed using CT, MRI, and magnetic resonance angiography.[1] CT is the most important preoperative test because it is useful in showing the destruction of bony structures and widening of foramen and fissures at the skull base.[1] Demonstration of the anterior bowing of the maxillary wall due to presence of a mass in the pterygomaxillary space on axial CT slices known as the Holman-Miller sign is a characteristic finding of JNA.[9] Moreover, tumor staging is done based on CT. MRI is useful to show the presence of intracranial extension of the tumor. MRI also helps discern between sinus invasion, obstruction and retention of secretions.[1] On MRI, JNA appears as a heterogeneous mass with signal voids that are consistent with the highly vascular tumor.[1] Selective angiography identifies the feeding vessels and allows for preoperative embolization for vascular control. It shows the size and site of lesion as well as the size and location of feeding vessel.[1,13] Vascularization arises most frequently from the external carotid branch of maxillary artery with background vascularization arising from blood vessels in the ascending pharyngeal artery and internal carotid artery.[4]

The preferred management includes surgery with preoperative embolization.[4] Other methods of treatment that have been employed are irradiation, hormone therapy, cryotherapy, arterial ligation, use of sclerosing agents.[2,4] Future therapy for JNA may include intra-arterial immunotherapy and the use of certain agents that inhibit angiogenesis.[2]

IV. Conclusion

Surgical management of JNA with intracranial extension is complex and thus requires an expert multidisciplinary team. Although craniofacial approaches appear to be the current standard of treatment, there is increased experienced-based evidence that endoscopic resection of large or an extended tumor is feasible in expert hands. Preoperative embolization reduces intraoperative blood loss and should be undertaken in all suitable patients. Subtotal tumor resection and postoperative radiotherapy does not appear to result in higher recurrence. Significance of reporting the case lies in its involvement and extension into the oral cavity including mandible, and intracranial extension which is rare and utilization of imaging as the sole modality to diagnose the lesion well in time, and appropriate surgical excision have significantly improved outcome.

Bibliography

- [1]. Mehmet A, Orhan S, Suphi M. Juvenile nasopharyngeal angiofibroma: Radiological evaluation and pre-operativ embolization. *KBB Forum*. 2006;5:58–61.
- [2]. McDaniel RK, Houston GD. Juvenile nasopharyngeal angiofibroma with lateral extension into the cheek: Report of case. *J Oral Maxillofac Surg*. 1995;53:473–6. [[PubMed](#)]
- [3]. Martins MB, Lima FV, Mendoca CA, Jesus EP. Nasopharyngeal Angiofibroma: Our experience and literature review. *Int Arch Otorhinolaryngol*. 2013;17:14–9.
- [4]. Dillard DG, Cohen C, Muller S, Del Gaudio J, Reichman O, Parrish B, et al. Immunolocalization of activated transforming growth factor beta1 in juvenile nasopharyngeal angiofibroma. *Arch Otolaryngol Head Neck Surg*. 2000;126:723–5. [[PubMed](#)]
- [5]. Shaheen OH. Angiofibroma. In: John NG, editor. *Scott and Brown Otolaryngology*. 5th ed. London: Butterworth-Heinemann; 1987. pp. 291–4.
- [6]. Kabot TE, Goldman ME, Bergman S, Schwartz RD. Juvenile nasopharyngeal angiofibroma: An unusual presentation in the oral cavity. *Oral Surg Oral Med Oral Pathol*. 1985;59:453–7. [[PubMed](#)]
- [7]. Enepekides DJ. Recent advances in the treatment of juvenile angiofibroma. *Curr Opin Otolaryngol Head Neck Surg*. 2004;12:495–9. [[PubMed](#)]
- [8]. Nicolai P, Berlucchi M, Tomenzoli D, Capiello J, Trimarchi M, Maroldi R, et al. Endoscopic surgery for juvenile angiofibroma: When and how. *Laryngoscope*. 2003;113:775–82. [[PubMed](#)]
- [9]. Maurice M, Milad M. Pathogenesis of juvenile nasopharyngeal angiofibroma. *Braz J Otorhinolaryngol*. 1981;95:1121–6. [[PubMed](#)]
- [10]. Andrade NA, Pinto JA, Nóbrega Mde O, Aguiar JE, Aguiar TF, Vinhaes ES. Exclusively endoscopic surgery for juvenile nasopharyngeal angiofibroma. *Otolaryngol Head Neck Surg*. 2007;137:492–6. [[PubMed](#)]
- [11]. Neville BW. Soft tissue tumors. In: Neville BW, Damn DD, Allen CM, Bouquot JE, editors. *Oral and Maxillofacial Pathology*. 1st ed. Philadelphia, Pennsylvania: WB Saunders Company; 1995. pp. 362–415.
- [12]. Harrison DF. The natural history, pathogenesis, and treatment of juvenile angiofibroma. Personal experience with 44 patients. *Arch Otolaryngol Head Neck Surg*. 1987;113:936–42. [[PubMed](#)]
- [13]. Lloyd G, Howard D, Phelps P, Cheesman A. Juvenile angiofibroma: The lessons of 20 years of modern imaging. *J Laryngol Otol*. 1999;113:127–34. [[PubMed](#)]