

## Enhancing Smile through Veneers- A Case Report.

Dr. Krupali Shah<sup>1</sup>, Dr. N. Vimala<sup>2</sup>, Dr. Lalitagauri Mandke<sup>3</sup>

<sup>1,2,3</sup> (Dept. of Conservative Dentistry & Endodontics/ D Y Patil University School of Dentistry, India)

---

**Abstract:** Re-establishing a patient's lost natural dental esthetics is one of the most important topics of today's dentistry, in addition to function and phonation. A major factor in achieving an elusive dominant characteristics called personality is a captivating smile showing an even row of natural gleaming white teeth. In order to solve such problems, the technique preferred most frequently is to cover teeth with dental crowns. However, major disadvantages of crowns is excessive preparations of teeth and damages to surrounding tissues, such as gingiva. Therefore, in recent years, laminate veneer restorations, are more esthetic and conservative treatment option, used in dentistry.

**Key words:** aesthetic, ceramic, fracture, indirect, veneers

---

### I. Introduction

“All human desires are in some way related to beauty.” Aesthetic is derived from the Greek word “aesthesia”, which means sensation or sensibility. It can be defined as belonging to the appreciation of the beautiful. An important asset a person can have is a smile which shows beautiful, natural teeth. Color, shape, structure and position abnormalities of anterior teeth can lead to important esthetic problems for patients<sup>[1]</sup>. There is a conscious effort to avoid smiling when teeth are discolored, crooked, missing, or malformed and individual tries to cover up the teeth. Correction of such problems can produce dramatic change in appearance of the person, which results in improved confidence, personality, and social life<sup>[2]</sup>.

A perfect smile will improve the self-confidence, personality and social life of patient and also has psychological effect on improving the self-image with an enhanced self-esteem of the patient. The use of ceramic veneers is not a recent development. In 1938 Pincus described a technique used for Hollywood filmmaking. A common adhesive was used for total prosthesis to retain veneers to the tooth surface. The introduction of adhesive system and their continuous improvements has increased clinical success of these techniques<sup>[3]</sup>.

New ceramic and composite materials have increased the conservative treatments of compromised anterior teeth<sup>[4]</sup>. Restorative treatment of malposition, discolored, or fractured anterior teeth is still a challenge for dental practitioners. Full coverage crowns provide very satisfactory results, but the loss of sound tooth structure is regarded as an important drawback<sup>[5]</sup>. Indirect additive veneering was introduced in 1980s as an alternative to full-coverage crowns<sup>[4]</sup>. The development of adhesive techniques has increased the use of particulate filler composite (PFC) veneers or ceramic veneers as minimally invasive treatment options. The major advantages of laminate veneers are, minimal reduction of tooth structure, good esthetic properties, color stability, and reliable bonding compared to traditional full coverage restorations. The concept of no preparation or minimal preparation has followed the development of appropriate enamel bonding procedures<sup>[5]</sup>. The color and integrity of dental tissue substrates to which veneers will be bonded are considered important for clinical success<sup>[4]</sup>. The longevity of porcelain veneers has been evaluated clinically and shown to range from 3 to 15 years<sup>[5]</sup>.

### II. Case Report

A 16-year old female patient had reported to the department of conservative dentistry and endodontics complaining of fractured restoration in her upper front tooth. Restoration (direct composite veneer) was done few years back in 11, 21, 22. Restoration on tooth 11 was fractured (Fig 1, 2, 3, 4).

### III. Treatment Plan And Procedure

Placement of indirect laminate veneer was proposed to the patient in relation to 11, 12, 21, 22. A prophylactic scaling and polishing was carried out. Shade selection was done using the VITA classic shade

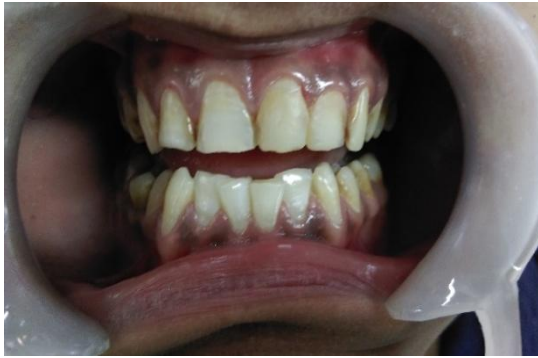

Fig 1.

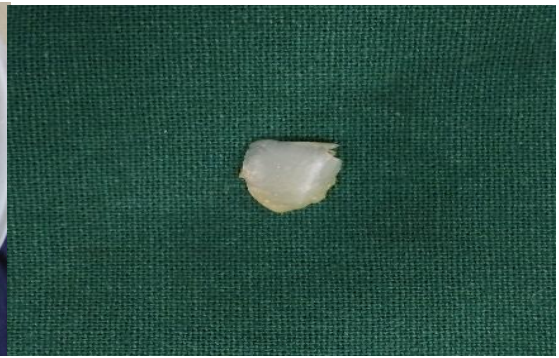

Fig2.

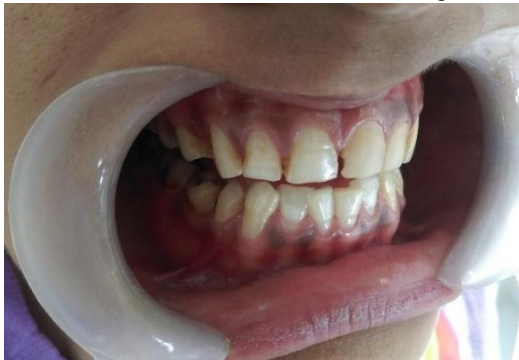

Fig 3.

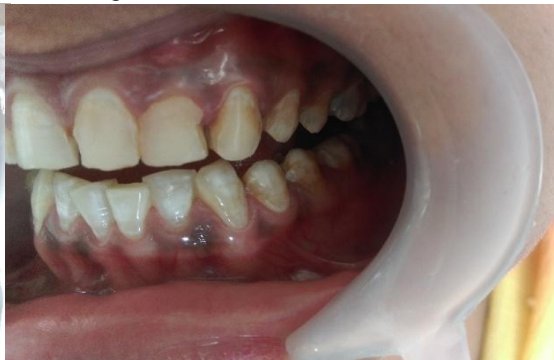

Fig4.

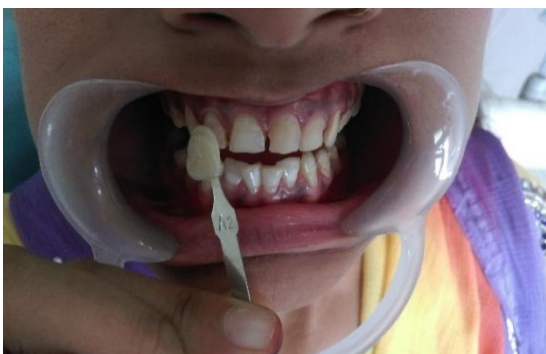

Fig 5.

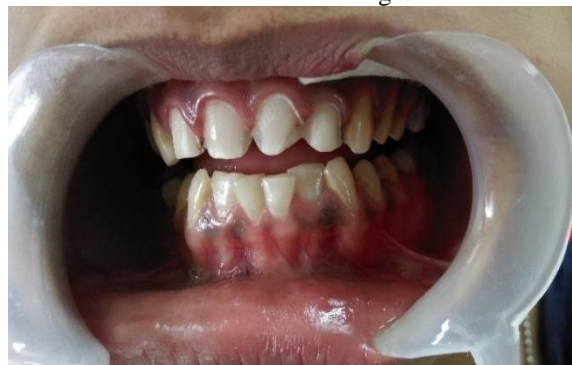

Fig 6.

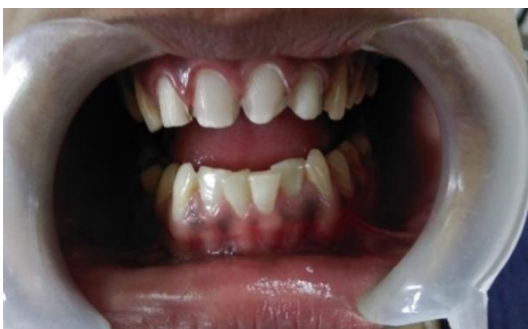

Fig7.

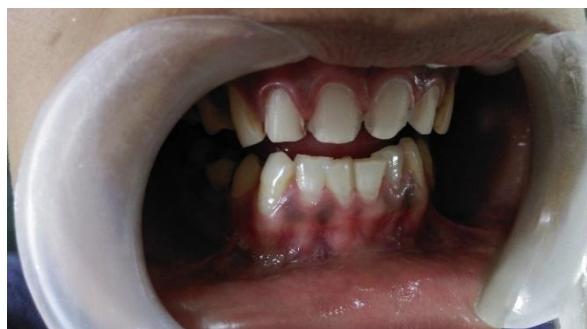

Fig 8.

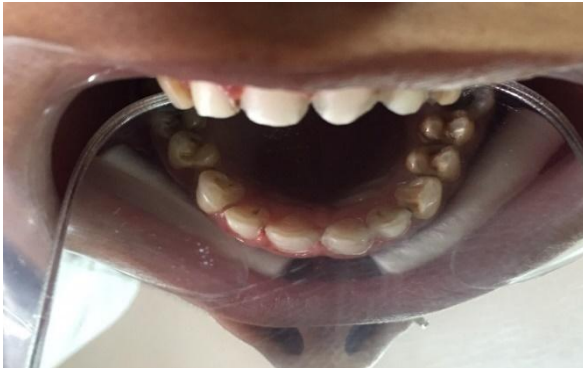

Fig 9

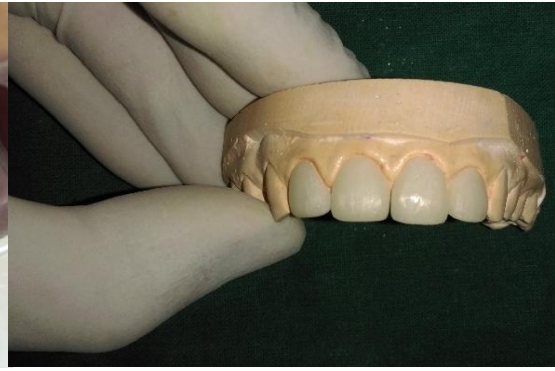

Fig 10.

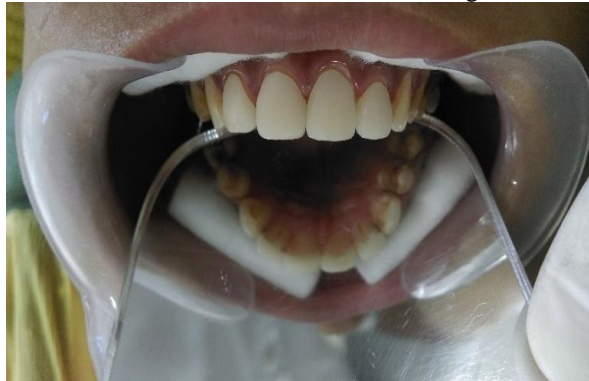

Fig 11.

Upper and lower alginate impression were taken before starting the treatment. The teeth were then isolated with bilateral cotton rolls and gingival retraction cord. Existing defective restorations and small carious lesions were restored before preparation. Tooth preparation was done using a flat end tapered diamond bur to a depth of 0.5 to 0.75 mm (Fig6,7,8). Interproximal margin extended into the facial and gingival embrasure. Incisal over-lap was given to all the teeth (Fig 9). Elastomeric impression was taken of the preparation. Stone working cast were made from the impression (Fig 10).A trial of the veneer was done in the next appointment (Fig 11).

### Veneer Cementation

Veneer cementation was done in two steps:

- Preparation of the veneer.
- Preparation of the tooth.

Acid etching of the veneer was done using 10% hydrofluoric acid (Fig 12a, 12b, 12c, 12d). Then a silane primer was applied to the veneer and cured for 30 second (Fig 13a, 13b,13c).Followed by which the resin bonding agent was applied and cured for 30 seconds (Fig 14). The veneer were placed under the jar lid that was impervious to light (Fig 15).

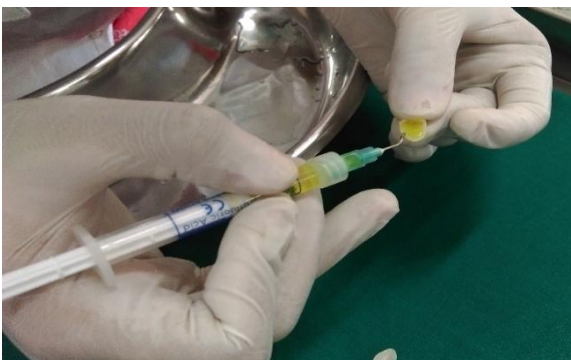

Fig 12a.

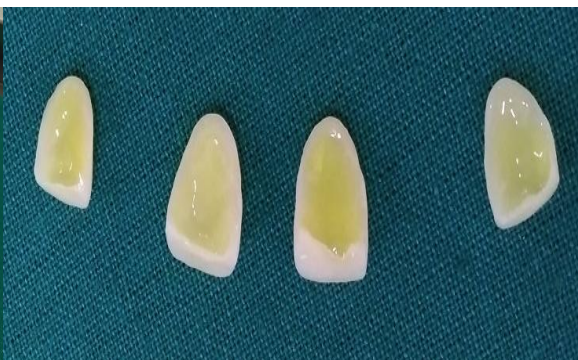

Fig 12b.



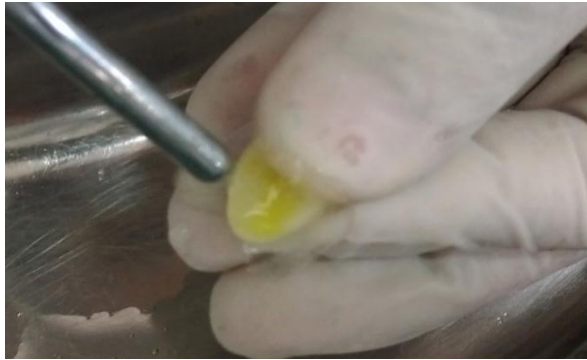

Fig 12c.

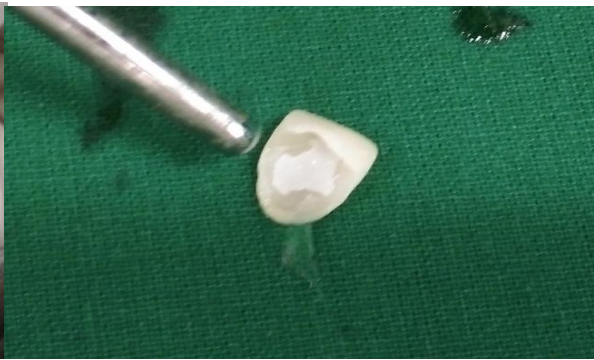

Fig 12d.

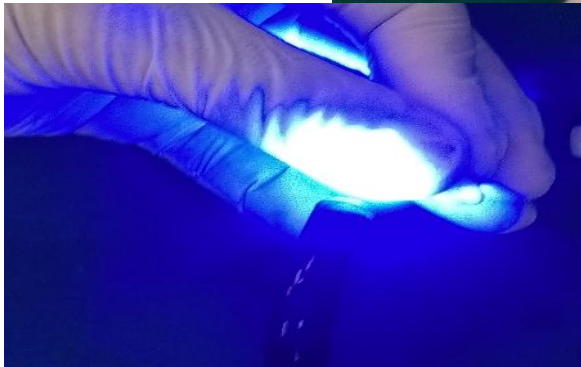
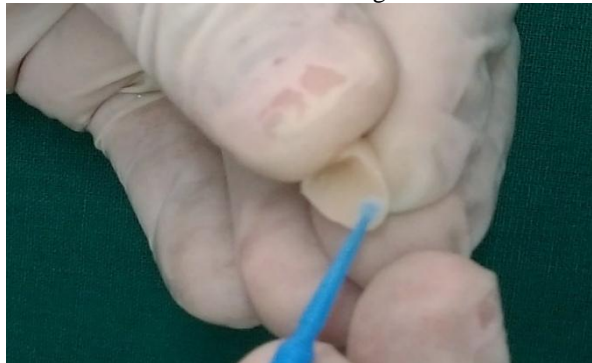
Fig 13a.

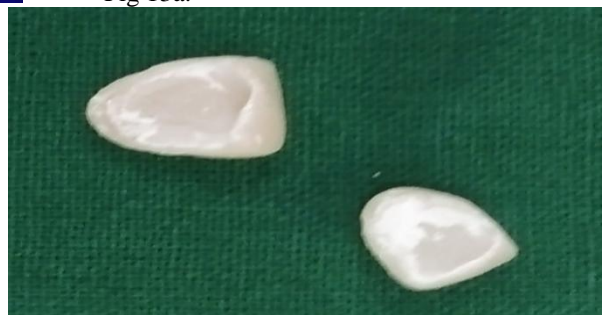

Fig 13b.

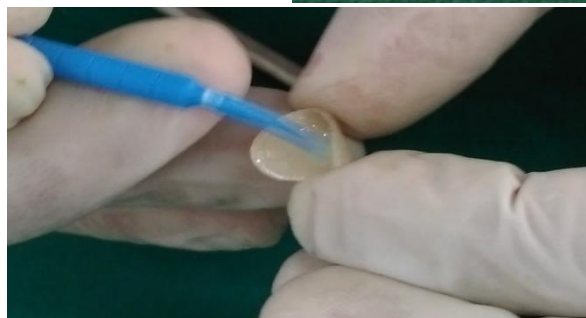

Fig 13c.

Fig 14.

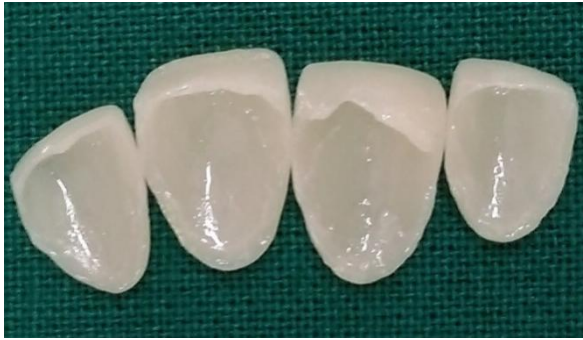

Fig 15.

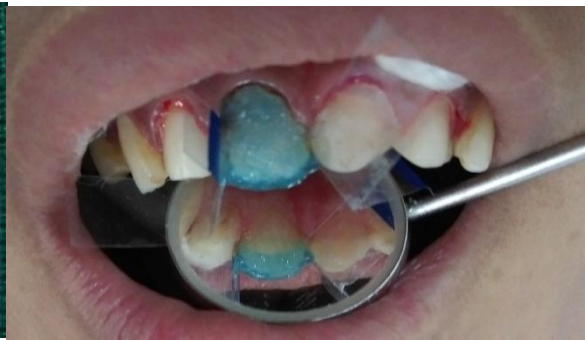

Fig 16a.

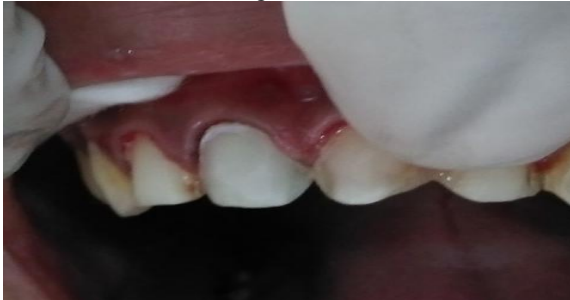

Fig 16b.

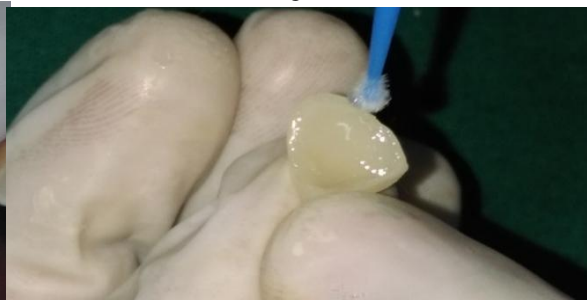


Fig 17.

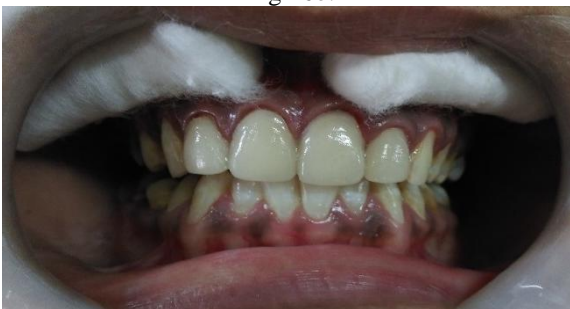

Fig 18a.

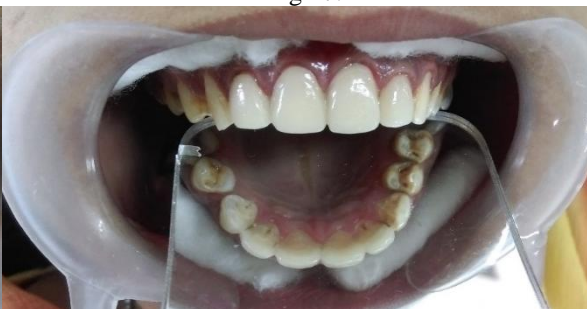

Fig 18b.

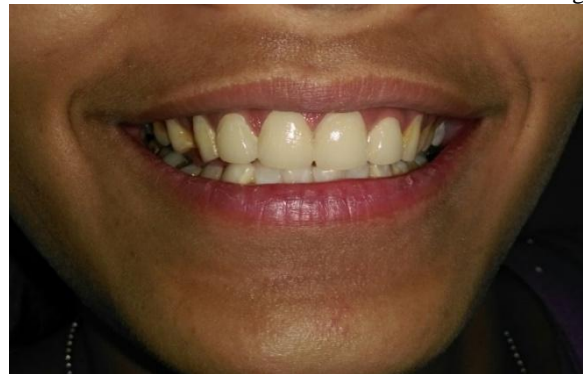

Fig 19.

Polyester strips were placed interproximally followed by which etching of the tooth was done (Fig 16a, 16b). Then the bonding agent was applied to the tooth and cured for 30 seconds. Thin layer of light cured resin cement was placed on the tooth side of the veneer (Fig 17) and the first veneer was placed on the tooth and carefully positioned. The margins of the veneer were examined to verify the accurate seat of the veneer. The excess cement was removed and the margins were evaluated again before the veneer was exposed to the curing light. After positioning and bonding the first veneer, the second veneer was positioned carefully and bonded followed individually by the remaining veneer. The marginal fit of the veneers were checked and any excess cement was removed. (Fig 18a, 18b, 19).

#### **IV. Discussion**

The demand for attractive smile and tooth color restorations has passed the boundaries from exclusive practitioners, esthetic centers and specialist to all over the world. Esthetically pleasing restorations of young

fractured teeth or malformed or discolored teeth has been a perplexing problem for the dentist, for the past few years. A conservative approach to improve the esthetic appearance of such patients has led to widespread use of veneering system. One of the most conservative and aesthetic techniques that can be used when restoring the human dentition is porcelain laminate veneer. Veneer is a layer of tooth-colored material that is applied to a tooth to restore generalized or localized defects and intrinsic discolorations. Veneers can be made by directly applied composite, processed composite, porcelain, or pressed ceramic materials. Common indication of teeth include teeth with facial surfaces that are abraded, eroded, discolored or malformed or have faulty restorations.

Two types of veneers exist:

**Partial Veneers:** indicated for the restoration of localized defect or areas of intrinsic discoloration.

**Full Veneers:** indicated for the restoration of generalized defects or areas of intrinsic discoloration involving most of the facial surface of the tooth. Several factors including patient's age, occlusion, position and alignment of the teeth, tissue health and oral hygiene must be evaluated before pursuing full veneers. Two basic preparation designs for full veneers are: *window preparation* and *incisal lapping* preparation.

**Window Preparation** is recommended for most indirect and direct composite veneers. This preserves the functional lingual and incisal surfaces of the maxillary anterior teeth and protects the veneer from significant occlusal stress. **Incisal lapping preparation** is indicated when the tooth to be veneered needs lengthening or when an incisal defect warrants restoration. Incisal lapping design is used frequently with porcelain veneers because it facilitates accurate seating of the veneer on cementation and also allows improved esthetics along the incisal edge. Full veneers can be accomplished by a *direct* and *indirect technique*. *Directly applied composite veneers* can be completed chairside for the patient in one appointment when only few teeth are involved, or when the entire facial surface is not faulty. One of the most important considerations in this technique is tooth preparation. Bonding to enamel provides the best/strongest bond values when we want to bond porcelain to tooth structure. Microleakage or debonding of a porcelain veneer restoration is not likely to occur when it is bordered by enamel on all margins.

Indirect veneer require two appointments, but it typically offer three advantages over direct veneers:

- Indirectly fabricated veneers are less sensitive to operator's technique.
- Indirect veneers last much longer than direct veneers, if they are made of porcelain or pressed ceramic.
- If multiple teeth are to be veneered, indirect veneers can be placed much more expeditiously<sup>[6]</sup>.

The advantages offered by indirect techniques are:-

- Superior esthetic result
- Adequate abrasion resistance
- Dimensional & chromatic stability overtime
- Better control over contacts & contours
- Superior physical & mechanical properties
- Reduce chairside time

## V. Conclusion

The success of anterior indirect restoration depends on proper treatment planning and application of proper operative protocol. Veneers have become esthetic alternative to ceramic crowns and traditional porcelain fused to metal. Smile can be transformed painlessly, quickly and conservatively with dramatic, long-lasting results with the successful use of the porcelain veneer. Veneers are now the restorative choice for esthetic in numerous clinical circumstances that would have resulted in the use of full crown in the past. Tissue response is excellent and the finished surface is similar to the natural tooth. They exhibit natural fluorescence and absorb, reflect, and transmit light exactly as does the natural tooth structure.

## References

- [1] Bora Korkut, Funda Yanikoğlu, Mahir Günday, Direct Composite Laminate Veneers: Three Case Reports, Journal of Dental Research, Dental Clinics, Dental Prospects 7(2), 2013, 105-111.
- [2] Galip Gürel-. The Science and Art of Porcelain Laminate Veneers-1<sup>st</sup> edition (Quintessence publishing) 19-47
- [3] Francesco Mangani, Antonio Cerutti, Angelo Putignano, Raffaele Bollero, Lorenzo Madini, Clinical Approach to Anterior Restorations Using Resin Composite Veneer, The European Journal Of Esthetic Dentistry, Vol 2, No, 2 Summer 2007.
- [4] Dino Re, Gabriele Augusti, Massimo Amato, Giancarlo Riva and Daugusti Esthetic Rehabilitation of Anterior Teeth with Laminates Composite Veneers, Case Reports in Dentistry, Vol 2014.
- [5] Suha TURKASLAN, Arzu TEZVERGİL-MUTLUAY, Bora BAGIS, Akikazu SHINYA, Pekka K VALLITTU and Lippo V LASSILA Effect of Intermediate Fiber Layer on the Fracture Load and Failure Mode of Maxillary Incisors Restored with Laminate Veneers, Dental Materials Journal, 27(1), 2008, 61-68.
- [6] Roberson, Sturdevant's art and science of operative dentistry- 5<sup>th</sup> edition (Elsevier, New Delhi, India 2008) 623-681