

Cheiloscopy – A Study of Lip Prints for Personal Identification

Remya S¹, Priyadarshini T¹, Umadethan B¹, Gopalan M², Jeyaseelan N³

¹Department of Forensic Medicine, Amrita School of Medicine, Amrita Institute of Medical Sciences & Research center

²Department of Medical Illustrations, Clinical Skills Simulations, Digital Health & Telemedicine, Amrita School of Medicine, Amrita Institute of Medical Sciences & Research center, Amrita University, Kochi-41, Kerala, INDIA.

³Department of Anatomy, Faculty of Medicine, SEGi University, Kota Damansara, Selangor, Malaysia.

Abstract: Wrinkles and grooves found on the mucosa of lips have characteristic patterns, known as lip prints. The present study was conducted to determine the uniqueness of lip prints, to identify the most common type and to evaluate the gender difference in the lip print patterns. Lip prints of 200 undergraduate medical students (100 males and 100 females) in the age group of 18-23 years were collected and analyzed with the help of a personal computer and Adobe photoshop software. The lip print pattern of an individual is unique and there is difference in the pattern of both sexes.

Keywords: Cheiloscopy, lip prints, sex determination.

I. Introduction

There are several methods of establishing identity of a living person. Apart from the routine parameters of identification such as sex, age, stature, dental peculiarities, palate prints, lip prints also play a role in establishing identity. Lip prints are the normal lines and fissures in the zone of transition of human lip between mucosa and the skin^[1, 2]. The study of lip prints is known as cheiloscopy. Cheiloscopy is important because, like finger prints lip prints are permanent, unchangeable and unique to each person except in monozygotic twins^[1]. They are identifiable as early from the sixth week of intrauterine life. It has been verified that they recover after undergoing alterations like trauma, inflammation and diseases like herpes. The disposition and form of the furrows in the lip prints do not vary with environmental factors^[3]. It has also been suggested that variations in patterns among males and females could help in determining the gender^[4].

II. Cheiloscopy

Lips are two highly sensitive mobile folds, composed of skin, muscle, glands and mucous membrane. They surround the oral orifice and form the anterior boundary of the oral cavity. Anatomically, the surface that forms the oral sphincter is the lip area. There are two lips, an upper and lower which are joined at the corners of the mouth, the commissures and separated by the buccal fens^[5].

Lips are covered by mucosa and partly by skin. When the two meet a white wavy line is formed, the labial cord which is quite prominent in Negroes. When identification is concerned, the mucosal area is important. This area called Klein's zone is covered with wrinkles and grooves which form a characteristic pattern called lip print^[6].

Lip prints are useful in personal identification as they are analogues to fingerprints. There are different systems of classification of lip prints. Lip prints described for the first time by Fisher^[7] and a simple system for classification of lip prints was devised by Martin Santos^[8,9,10]. Kazuo Suzuki and Yasuo Tsuchihashi (1971) devised their own classification of six different types of grooves as shown in Table- 1^[8, 9,11,12].

Table 1. Tsuchihashi's classification of lip prints

Type	Description
I	The clear-cut vertical grooves that run across the entire lips
I□	Grooves similar to Type I but do not cover the entire lip
II	Branched grooves (branching Y-shaped pattern)
III	Criss-cross pattern
IV	Reticular patterns
V	Miscellaneous

III. Objectives Of The Study

Primary objective of the present study was to determine the uniqueness of lip prints, to identify the most common type and to determine the gender difference in the lip print pattern.

IV. Materials And Methods

Present study was undertaken in the Department of Forensic Medicine of Amrita School of Medicine. A study group of 200 undergraduate students (100 males and 100 females) in the age group 18-23 years were chosen randomly from Amrita School of Medicine, Kochi, hailing from different districts of Kerala State, India.

After obtaining written informed consent from the subjects, basic details such as personal identification, demographic data, medical and surgical history were obtained and recorded in the proforma prepared. Subjects with congenital lesions, diseases and injuries of lips and persons with known hypersensitivity to lipstick were excluded.

To obtain the lip prints of the subjects, dark colored lip stick was applied on each lip evenly using a lip stick applicator. Pieces of cellophane tape measuring 10x 3cm were applied on each lip and lip print was lifted and affixed onto a plain white paper. Images of the lip prints thus obtained were scanned using a HP flatbed scanner. The scanned images were analyzed with the help of a personal computer using the Adobe photoshop software. The lip print pattern of middle part of lower lip was considered for classification, as it is visible in almost all the prints. The pattern is determined based on the numerical superiority of lines in the study area^[2]. Lip prints collected were classified based on the classification scheme proposed by Suzuki and Tsuchihashi into 6 types as given in Table 1.

After classifying the lip prints into different types, they were compared with each other for determining the uniqueness. The result obtained were subjected to statistical analysis using SPSS (Statistical package for social sciences) version 20 and Chi square test.

V. Results

The 200 lip prints obtained were classified into 6 types based on the method of classification proposed by Suzuki and Tsuchihashi (Fig.1, 2). Majority of the study group (52 people -26%) belonged to Type IV and 15 people (7.5%) belonged to Type V group. 33 females (33%) belonged to Type II and 38 males (38%) belonged to Type IV (Table. 2). This result was statistically significant in determining the gender (p value of <0.001). No two lip prints of the same type matched with each other, and hence considered unique.

Figure 1 and 2 showing the different types of lip prints as per the classification scheme proposed by Suzuki and Tsuchihashi.

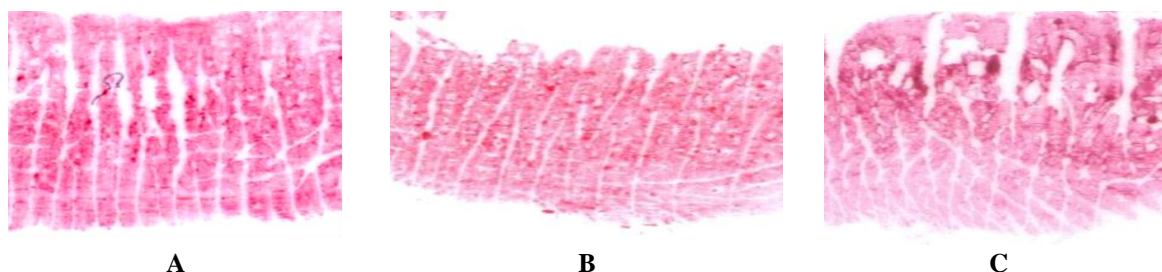


Figure 1. Types of lip prints A: Type I, B: Type I□, C: Type II

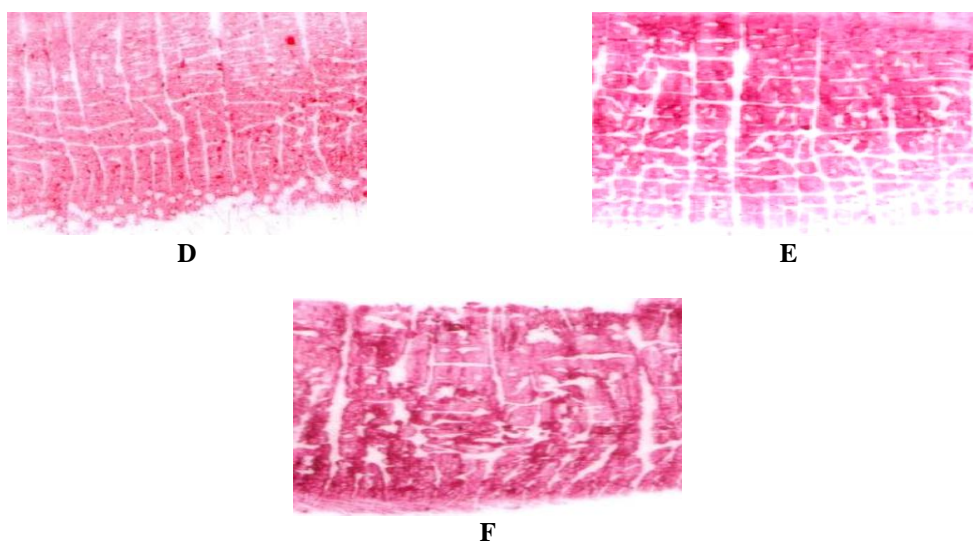


Figure 2. Types of lip prints D: Type III, E: Type IV, F: Type V

Table 2. Type of lip print and frequency in the study population

Type of lip print	Type I	Type I□	Type II	Type III	Type IV	Type V
Females	11	26	33	8	14	8
Males	10	21	11	13	38	7
Total	21(10.5%)	47(23.5%)	44(22%)	21(10.5%)	52(26%)	15(7.5%)

VI. Discussion

In a study conducted by Kinra et al^[13] in 40 subjects from Rajasthan, it was revealed that majority of the study group (13 subjects) belonged to Type III. In males, the predominant type was Type III (13 subjects) followed by Type IV. In the study group of 20 females, 12 belonged to Type I and Type I' followed by Type II. Chi-square test did not show a significant difference between males and females, with a p value of 0.31. But on comparison of lip print patterns and sex identification with Z test, a significant correlation was noted between Type III pattern of males and Type I/I' pattern of females.

In another study conducted by Vahanwahal et al^[14], Type I and Type I' patterns were found to be common in females, while Types III and IV patterns were common in males. The study by Naik et al^[15], showed that Type IV pattern was the most prevalent in males and Type I/I' pattern was the most prevalent in females. In a study conducted by Neeraj et al^[16] in 128 subjects, it was observed that Type I pattern was predominant in both males and females. Study conducted by Sharma et al^[17] in 40 subjects, it was revealed that Type I and I□ (10 subjects) were most commonly seen in females, and Type IV (11 subjects) was seen most commonly in males.

In the present study of 200 subjects, it was observed that majority of the subjects belonged to Type IV (26%). Type II (33 subjects) was predominant in females and Type IV (38 subjects) in males. The results were statistically significant in determining gender (p value <0.001).

VII. Conclusion

Lip prints are unique and hence can be used as a tool for personal identification. Majority of the study population belonged to Type IV (26%) and Type I□ (23.5%) ranking next. Type V (7.5%) was the least type of lip print in the present study group. Type II (33%) was common in females and Type IV (38%) was common in males which was statistically significant in determining the gender (p value <0.001).

References

- [1]. Caldas IM, Magalhaes T, Afonso A. Establishing identity using cheiloscopy and palatoscopy. *Forensic Sci Int* 2007, 167:1-9.
- [2]. Sivapathasundharam B, Prakash PA, Sivakumar G. Lip prints (Cheiloscopy). *Indian J Dent Res* 2001, 12:234-237.
- [3]. Ghimire N, Ghimire N, Nepal P, Upadhyay S, Budhathoki SS, Subba A, Kharel B. Lip print pattern : An identification tool. *Health Renaissance* 2013, 11(3):229-233.
- [4]. Augustine J, Barpande SR, Tupkari JV. Cheiloscopy as an adjunct to forensic identification: A study of 600 individuals. *J Forensic Odontostomatol* 2008, 27(2):44-52.
- [5]. R. Warwick, P.L. Williams, *Gray Anatomia*, 35th ed., Rio de Janeiro, Guanabara Koogan, 1979, pp. 1137-1140; 1168-1173.
- [6]. V.M. Pueyo, B.R. Garrido, J.A.S. Sa 'nchez, *Odontologi 'a Legaly Forense*, Masson, Barcelona, 1994, pp. 277-292.
- [7]. Kasprzak J. Possibilities of cheiloscopy. *Forensic Sci Int*. 1990, 46:145-51.
- [8]. Suzuki K, Tsuchihashi Y. New attempt of personal identification by means of lip print. *JIDA* 1970, 42:8-9.
- [9]. Suzuki K, Tsuchihashi Y. Personal identification by means of lip prints. *J Forensic Med* 1970, 17:52-57.
- [10]. Williams TR. Lip Prints – Another means of identification. *J Forensic Indent* 1991; 41:190-194.
- [11]. Ball J. The current status of lip prints and their use for identification. *J Forensic Odontostomatol* 2002, 20:43-46.
- [12]. Tsuchihashi Y. Studies on personal identification by means of lip prints. *Forensic Sci* 1974, 3:233-248.
- [13]. Kinra M, Ramalingam K, Sethuraman S, Rehman F, Lalawat G, Pandey A. Cheiloscopy for sex determination. *Universal Research Journal of Dentistry*. 2014, 4(1):48-51.
- [14]. Vahanwala S, Nayak CD, Pagare SS. Study of lip-prints as aid for sex determination. *Medico-legal Update* 2005, 5:93-98.
- [15]. Naik SK, Prabhu A, Nargund R. Forensic odontology: Cheiloscopy. *Hong Kong Dent J*. 2011, 8:25-28.
- [16]. Gupta N, Gupta R, Ingale DI, Bhuyar C, Nuchhi UC, Hibare SR. Role of lip print in personal identification. *Int J Cur Res Rev* 2013, 5(13): 25-28.
- [17]. Sharma P, Saxena S, Rathod V. Cheiloscopy: The study of lip prints in sex identification. *Journal of Forensic Dental Sciences*. 2009, 1(1): 24-27.