

The Size of the Tumor Does Not Determine the Feasibility of Limb Salvage but the Grade Does

Prof.T.Bavani Sankar, Prof.A.Affee Asma, Prof.J.C.Bose,
Dr.Appu Mathi Roga Rajan.M,
Institute of General Surgery, Madras Medical College, Chennai.

21 Year old male patient was admitted in our unit with the complaints of a swelling in the left forearm for the past four years. He had pain in that swelling for the past two years. There was a gross restriction of movements of the left forearm. Swelling started insidiously with gradual progression to reach the current size. This swelling was not associated with trauma. Patient was initially evaluated at a private hospital at vellore where incisional biopsy was done and it was reported as fibromatosis.

On clinical examination patient had a swelling noted at the distal one –third of volar aspect of left forearm. It measured about 9*7*6 cm. The surface of the tumour was found to be irregular with a longitudinal scar at the lateral aspect. The mass extended 15 cm from the elbow joint and 1cm from the wrist joint. The swelling was tender. Skin was free at all areas except at the site of the scar area. The swelling had well defined borders. The consistency was variable; it was firm to hard in certain areas. Mobility of the swelling was restricted. There was no distal neurovascular deficit. There was restriction of supination and pronation of left forearm; Rest of the movements of the both upper limbs were normal. There was no associated weakness of the left upper limb. There were no regional lymph nodes made out clinically. The differential diagnosis made was soft tissue sarcoma and Bone tumor and the case was evaluated.

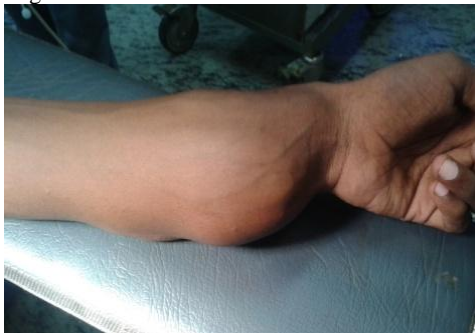

Figure 1. Pre-operative photograph of the left forearm tumor.

X ray forearm showed soft tissue mass in the distal forearm associated with multiple focal erosions of ulna and radius.

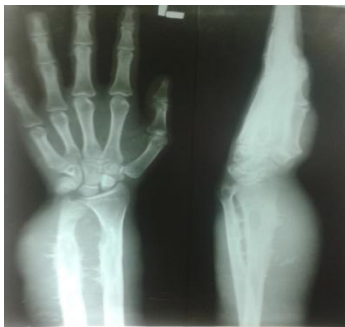

Figure 2. X ray of left forearm - AP & Lateral view.

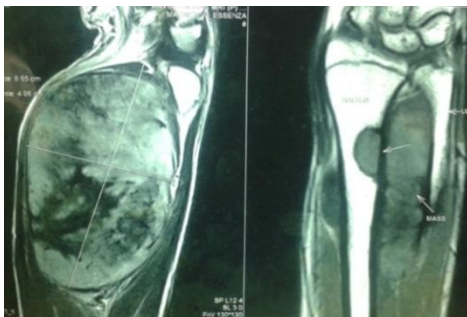

Figure 3. MRI of Left forearm.

MRI of the left forearm revealed a well defined heterogenous parosteal soft tissue mass in the left

The Size Of The Tumor Does Not Determine The Feasibility Of Limb Salvage But The Grade Does

forearm with focal bony erosions suggestive of EWINGS SARCOMA or SOFT TISSUE SARCOMA.

Slide was reviewed And It Was Confirmed As Fibromatosis. Patient Was Planned For An Monoblock Excision Of The Tumour With A Free Flow through Fibular Osteomyocutaneous Flap With Plate Screw Fixation And Wrist Arthrodesis By A Multidisciplinary Team Management.

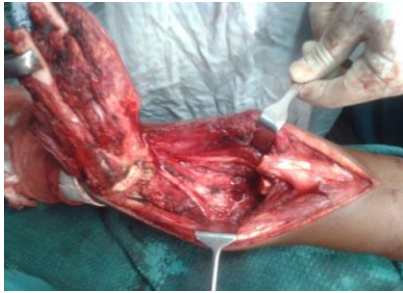

Figure 4. Excision of the tumour and both bones along with wrist disarticulation.

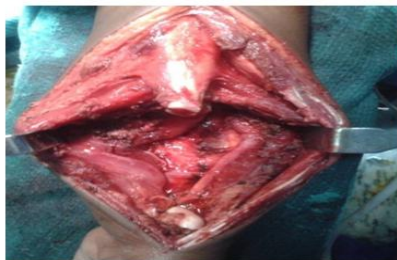

Figure 5. Soft tissue bed with neurovascular structures after tumor excision.

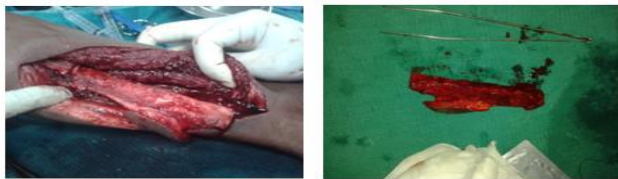

Figure 6. Harvesting Right fibular free flap.

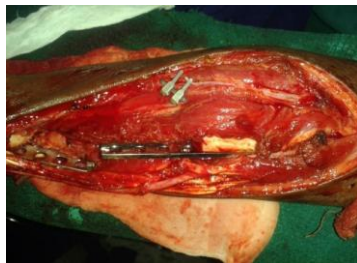


Figure 7. DCP plate fixed to the left radius stump and hand bones.

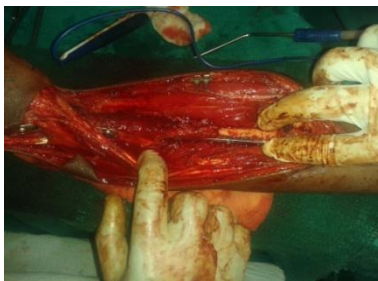

Figure 8. Free Fibula, hand bones and radius stabilized by DCP plates.

Specimen was sent for HPE and it was reported as bundles and whorls of spindle shaped cells with mild to moderate atypia with mitotic activity, collagenous bundles in between the cells. There was evidence of bony destruction. The resected margin of the bone was free of tumour. Immunohistochemistry marker S-100 was negative, but VIMENTIN was strongly positive. With the above picture it was reported as low grade fibrosarcoma.

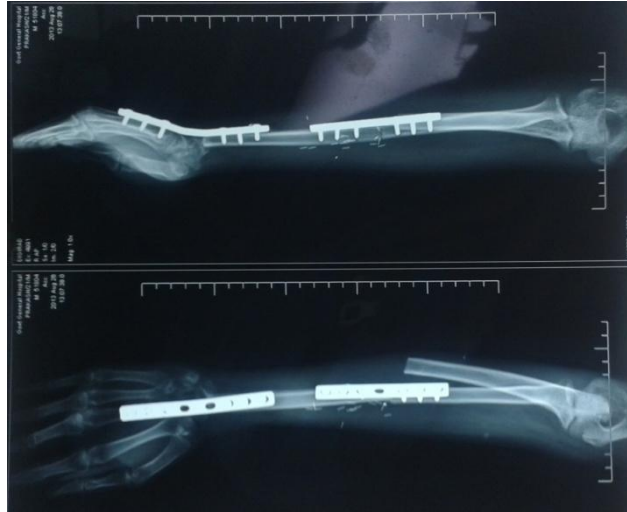


Figure 9. Post-operative X ray of left forearm.

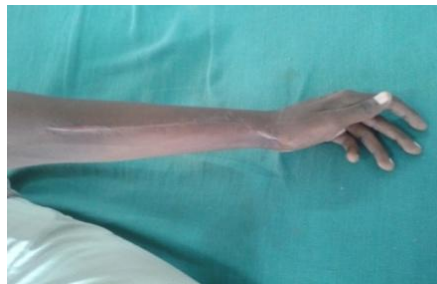

Figure 10. 15th day Post-operative Surgical site.

As the postsurgical HPE reported as Fibrosarcoma Grade-I, patient was subjected to adjuvant radiotherapy (EBRT) .



Figures 11 & 12. Pre-operative patient photo & Post-operative left upper limb function.

I. Discussion

Fibrous soft tissue tumors are soft tissue tumors of mesenchymal cell origin representing a wide spectrum of tumors ranging from benign-fibromatosis, intermediate to malignant tumors-fibrosarcoma.

II. Classification

Fibromatosis is classified as superficial or deep depend on the location. Superficial fibromatosis arise from the fascia or aponeuroses and generally are small and slow growing. The desmoid (deep) fibromatosis are a group of clinically diverse, deep-seated fibrous neoplasms mimicking malignancy. The deep fibromatosis may be abdominal or extra abdominal. The term aggressive fibromatosis is applied to these lesions, when referring to their potential for invasion and progressive growth.

Fibrosarcoma is a soft tissue tumor of mesenchymal cell origin that is composed of malignant fibroblasts in a collagenous background. It is classified as Juvenile or infantile fibrosarcoma, Adult fibrosarcoma - usual type, Low grade fibromyxoid sarcoma (with or without giant rosettes) and Sclerosing epithelioid fibrosarcoma.

III. Epidemiology

Extra Abdominal Fibromatosis is most common between 25 and 55 years of age. The etiology is multifactorial – genetic, endocrine and physical factors.

The Size Of The Tumor Does Not Determine The Feasibility Of Limb Salvage But The Grade Does

Fibrosarcoma represents 10% of musculoskeletal sarcomas. Adult type is common between 3rd and 5th decades. No definite cause is known; genetic mutations may play a role.

IV. Clinical Features

Extra Abdominal Fibromatosis presents as deeply situated firm, poorly circumscribed slow growing mass with little pain, restricted adjacent joint mobility and associated neurological symptoms due to pressure effects. It may be multicentric.

Adult type Fibrosarcoma presents as painless slow growing swelling. It can occur in any soft tissue site in every virtually anatomic site arising in the soft tissues of the thigh and posterior aspect of knee, frequently it is deep to the muscular fascia.

V. Imaging

Both fibromatosis and fibrosarcoma have similar features in imaging. The imaging useful in these conditions are Plain radiographs, CT and MRI of the local parts. CT chest and Bone scan can rule out macrometastasis. Imaging delineates the extent of the tumor, bony erosions and involvement of the neurovascular structures. The lesion appears as a soft tissue mass that interrupts the adjacent intermuscular and soft tissue planes. CT and MRI are helpful in the diagnosis and assessment of the tumor extent before surgery. Occasionally there may be calcification and ossification in fibrosarcoma.

Differential Diagnosis for Fibrosarcoma : Fibrosarcoma is a diagnosis of exclusion.

1. Nodular fasciitis
2. Cellular benign fibrous histiocytoma
3. Fibromatosis
4. Malignant peripheral nerve sheath tumor
5. Pleomorphic undifferentiated sarcoma
6. Monophasic fibrous synovial Sarcoma

Biopsy :

Tissue diagnosis is done by Core needle biopsy or Incisional biopsy. Fine needle aspiration cytology is used in recurrent disease for documentation.

VI. Pathological Features

Microscopically Fibromatosis has elongated slender spindle shaped cells of uniform appearance surrounded and separated from one another by collagen with little or no cell to cell contact. Cells and collagen bundles are arranged in sweeping bundles which are less well defined than fibrosarcoma. Microhemorrhages, Multinucleated cells and focal aggregates of lymphocytes are seen. Nuclei are small pale staining and sharply defined with one to three nucleoli. Deep fibromatosis show typically strong beta-catenin immune reactivity.

Fibrosarcoma has uniform fasciculated growth pattern comprising of spindle shaped cells that vary in size and shape with scanty cytoplasm, indistinct cell borders and parallelly arranged interwoven collagen fibres. Herring bone pattern is classical of fibrosarcoma but not seen in all tumors. Histology grading is based on cellularity and differentiation, mitotic activity and necrosis. It is often difficult to differentiate low grade fibrosarcoma from fibromatosis (Table -1) .

Table 1. Histological features of Low Grade fibrosarcoma and Fibromatosis

| S.no | Parameter | Low Grade fibrosarcoma | Fibromatosis |
|------|--------------------------|------------------------|-----------------|
| 1. | Cellularity | Low to moderate | Low to moderate |
| 2. | Nuclear overlap | Present | Absent usually |
| 3. | Nuclear hyperchromasia | Present | Absent |
| 4. | Nucleoli | Prominent | Inconspicuous |
| 5. | Mitotic figures | 1+ to 3+ | 1+ |
| 6. | Necrosis | Rare | Absent |
| 7. | Vessel wall infiltration | Rare | Absent |

VII. Management

Extra abdominal Fibromatosis is managed mainly by surgery. Surgery with negative microscopic margins is the mainstay of therapy. The goal of surgery is complete tumor removal with preserving function and minimizing morbidity. In situation where wide local excision cannot be performed adjuvant radiation is given. Imatinib and Sorafenib are useful in some cases with evidence of tumor shrinkage.

Fibrosarcoma is managed by Wide local excision and reconstruction. Size of the tumor in the extremities does not determine the feasibility of limb salvage, but it is the grade of the tumor which determines the margin of the clearance. In low grade soft tissue tumors, surgery is the main modality of treatment. The margin of clearance in low grade tumors can be marginal for limb salvage as adjuvant treatment is advised. In regions where conventional 2cm tumor clearance can't be given, tumor is excised one plane beyond the involved plane. In high grade tumors, radical surgery or neo adjuvant therapy is advised.

Neoadjuvant /Adjuvant radiotherapy or/and chemotherapy is given based on the grade, feasibility of limb salvage and operability. The common chemotherapeutic agents used are Doxorubicin, Vincristine, Ifosfamide and Dacarbazine.

VIII. Prognosis

Lung is the principle site of metastasis in fibrosarcoma followed by vertebra and skull. Recurrence rates for fibrosarcoma are as high as 40-60% and it decreases to 25% when post operative brachytherapy or teletherapy is given. Follow up to be done for minimum period of 5yrs. 5 year survival rate in adult Adult Fibrosarcoma is 40% and for Infantile form it is 80%. Recurrence in fibromatosis is common even after presumed complete surgical excision

IX. Conclusion

Size of the tumor in the extremity sarcomas does not determine the feasibility of limb salvage, but the Grade of the tumor does. In low grade soft tissue tumors, surgery is the main modality of treatment. The margin of clearance in low grade tumors can be marginal for limb salvage as adjuvant treatment is advised. In regions where conventional 2cm tumor clearance can't be given, tumor is excised one plane beyond the involved plane. In high grade tumors, radical surgery or neo adjuvant therapy is advised.

References :

- [1]. Devita, Hellman & Rosenberg's Cancer: Principles & Practice of Oncology, 8th Edition.
- [2]. Enzinger and Weiss's Soft tissue tumors Reitamo JJ, Hayry P, Nykyri E, et al. The desmoid tumor. I. Incidence, sex-, age- and anatomical distribution in the Finnish population. Am J Clin Pathol 1982; 77(6):665.
- [3]. Posner MC, Shiu MH, Newsome JL, et al. The desmoid tumor is not a benign disease. Archives of Surgery. 1989;124:191.
- [4].