

## A Hospital Based Prospective Study To Evaluate The Outcome Of Shoulder Hemi-Replacement In Four-Part Fracture And Four-Part Fracture Dislocation Of Proximal Humerus.

Vivek. L. Patel<sup>1</sup>, Prof. Mahantesh. Y. Patil<sup>2</sup>

<sup>1</sup>Postgraduate M.S. Ortho,

<sup>2</sup>M.S.Ortho, MCh Orth.

---

### Abstract:

**Background and objective:** Proximal humerus is the second most common site of fracture in the upper limb. The four-part proximal humerus fractures are severe and complex, make the management challenging especially in elderly. However controversy exists regarding the optimum treatment for four-part fracture and four-part fracture dislocation. The present study describes the efficacy of functional outcome of shoulder hemiarthroplasty in patients with four-part fracture and four-part fracture dislocation.

**Materials and methods:** This one year prospective study was done from January 2014 to December 2014 in the Department of Orthopaedics situated in a tertiary care hospital of north Karnataka, India. A total of 20 patients aged  $\geq 60$  years with four-part proximal humerus fracture with or without dislocation were studied. Patients underwent primary shoulder hemiarthroplasty and were followed at six weeks, three months and six months. The outcome was assessed based on Constant shoulder score.

**Result:** We reviewed 20 shoulders treated with hemiarthroplasty at interval of 6 weeks, 3 months and 6 months. Average Constant score of all 20 patients post-operatively at the end of 6 months was found to be  $71.05 \pm 18.50$ , which was suggestive of good outcome in study population. All patients had painless movements at the shoulder joint and were satisfied with the range of movements. Radiographic evaluation revealed anatomic tuberosity reconstruction in 9 shoulders. Primary causes for poor outcome in terms of pain and range of movements was due to rotator cuff degenerative changes in elderly patients, non-compliance for post op physiotherapy and comminuted proximal humerus fracture with dislocation. Overall functional outcome found to be excellent in 25%, good in 35%, moderate in 30% and poor in 10%.

**Conclusion:** It may be concluded that primary shoulder hemiarthroplasty for the treatment of four-part proximal humerus fracture with or without dislocation leads to a satisfactory functional outcome in most of the patients. The results were comparable to other studies with respect to mechanism of injury, type of fracture, side involved and Neer's classification of proximal humerus. Rotator cuff degenerative changes in these elderly patients was found to be a strong predictor of poor outcome followed by non compliance to post op physiotherapy protocol.

Hence primary shoulder hemiarthroplasty is an ideal treatment for Neer's four-part fracture with or without dislocation in elderly patients hence allowing early mobilization of the shoulder with good range of movements.

**Keywords:** Constant Shoulder Score; Four part proximal humerus fracture; Shoulder dislocation; Shoulder hemi replacement; Rotator cuff.

---

### I. Introduction

Proximal humerus is second most common site of fracture in the upper limb after distal radius. Incidence is about 4-5% of all fractures and over 70% of all proximal humeral fractures occur in patients over 60 years.<sup>1</sup> Four-part proximal humerus fractures and fracture-dislocations are among the most severe and account for only 5% of all proximal humerus fractures.<sup>2</sup>

Proximal humerus fractures are on rise due to sports and road accidents and increase in incidence of osteoporosis. Younger patients are less frequently involved, usually after sport or road accidents.<sup>3</sup>

In the older patient population, these fractures occur often in association with substantial osteoporosis, preexisting rotator cuff pathology, and multiple comorbidities. Further, these fractures are associated with a risk of developing osteonecrosis of the humeral head, with reported rates ranging from 21% to 75% in these fractures.<sup>4</sup>

A wide variety of treatment modalities have been used in the past, depending on fracture pattern, patient's age, general health status, and level of activity which include transosseous suture fixation, tension band wiring, standard plate and screw fixation, percutaneous wire, screw fixation and hemiarthroplasty.<sup>5</sup>

Conservative treatment has limited indications, late functional recovery, but it is noninvasive, and may be efficient in undisplaced or mildly displaced fractures.

With continued advancement of techniques and implants such as locking plates, surgical fixation of proximal humerus fractures has been increasing in popularity. However, the reported complication rates in humeral head preserving procedures continue to be high. In particular, the rate of osteonecrosis remains unchanged even with the most modern of techniques. It is clear that the prevalence of osteonecrosis after proximal humerus fractures increases over time.

Good clinical outcomes range from 92% for ORIF, 87% for conservative treatment, and 87.5% for shoulder arthroplasty. Advantages of ORIF are anatomic restoration, and early mobilization; however, open surgery may be associated with higher rates of infections, avascular necrosis of the humeral head and neurovascular lesions.<sup>3</sup> Fractures with a humeral head split and complex three- and four-part fractures are also at risk for the development of malunion and osteonecrosis after internal fixation.<sup>6,7</sup> Both shoulder hemiarthroplasty and, more recently, reverse total shoulder arthroplasty (RTSA) are indicated for these more complex fractures with high complication rates with humeral head preserving procedures.

Joint replacement has limited indications, strict selection of patients, and significant invasivity, but faster active recovery. The use of hemiarthroplasty for treating displaced three or four-part fracture was initially reported by Neer. Multiple studies subsequently reported inconsistent results for ROM and function. Complications include displacement of the tuberosity fragments, persistent pain, glenohumeral joint space narrowing, and heterotopic ossification.<sup>5</sup>

However, controversy exists regarding the optimum treatment for four-part fracture and four-part fracture dislocation. Recent metaanalyses and larger retrospective and prospective series have not shown an advantage of one treatment modality in the management of all displaced fractures.<sup>8</sup> Hence the present study was planned to assess the efficacy of functional outcome of shoulder hemi replacement in patients diagnosed as four part fracture and four part fracture dislocation in terms of pain, shoulder stability and range of movements at shoulder joint.

## **II. Materials And Methodology**

The present study was a one-year hospital based prospective study conducted at KLES Dr. Prabhakar Kore Hospital and Medical Research Centre, a tertiary care teaching hospital, Belagavi during the period of January 2014 to December 2014.

Patients sustained to have four part proximal humerus fractures based on Neer's classification presenting at the Department of Orthopaedics, KLES Dr. Prabhakar Kore Hospital and Medical Research Centre, Belagavi were included in the study. Sample size of 20 patients was taken based on statistical data of the hospital.

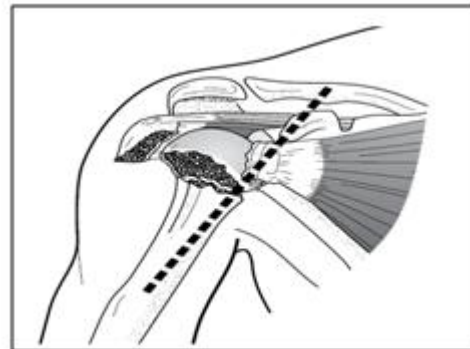
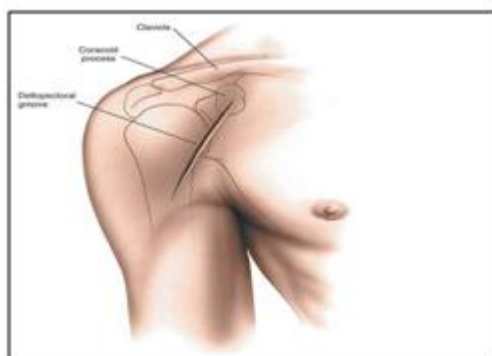
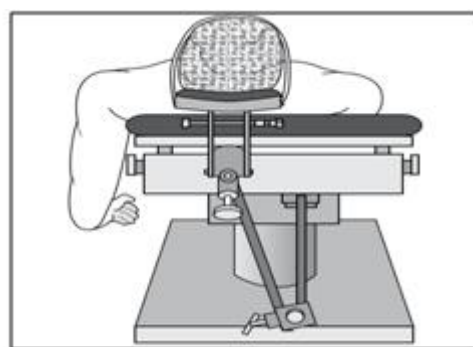
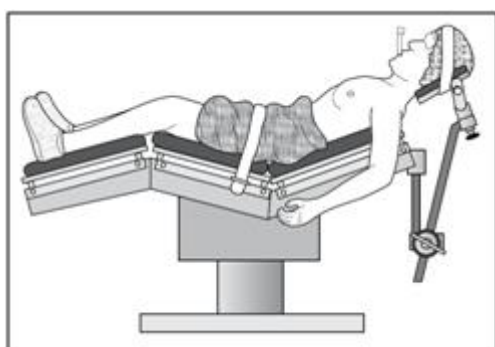
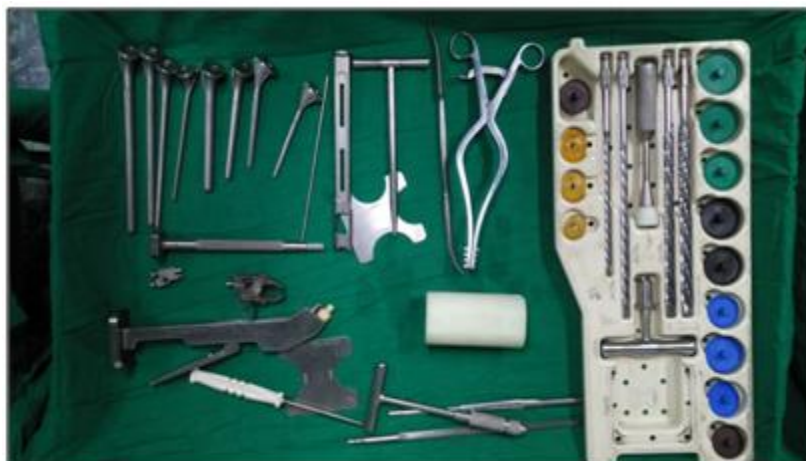Majority of injuries were the result of trivial trauma due to self-fall in elderly osteoporotic patients. (n=12/20). The mean age was  $65.35 \pm 5.58$ . (range 60-70 years)

All patients had a plain radiograph of shoulder (anterior-posterior view), and pre-op CT Scan of the shoulder along with routine blood investigations. Patients with pathological fractures, any associated neurovascular deficit, patients with compound fracture of the shoulder, patients with undisplaced fracture of proximal humerus were not included in this study. Patients presenting with four-part fracture of proximal humerus with or without dislocation with age >60 years and who were willing to take part in this study were included in this work.

## **III. Procedure**

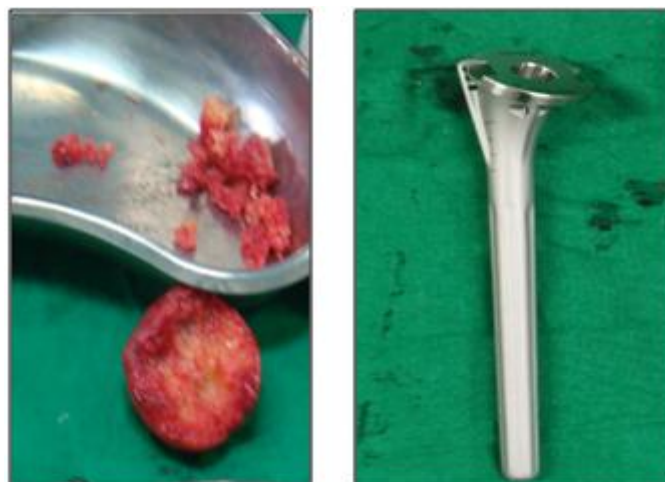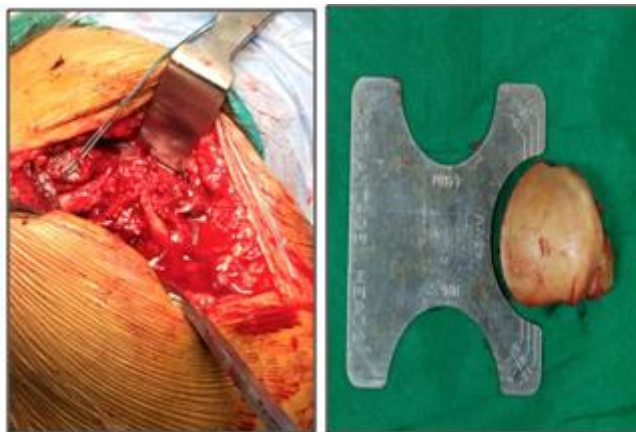
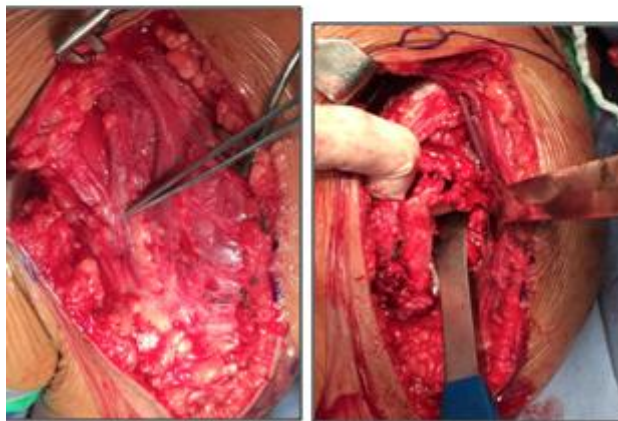
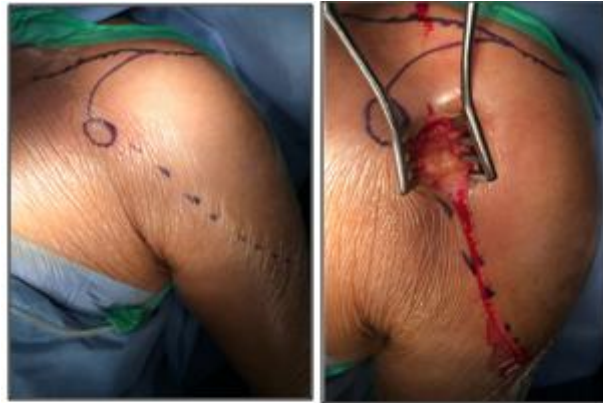Patients were treated with shoulder hemi arthroplasty surgery. All the surgeries were performed in an orthopaedic operation theatre under antibiotic cover and under general anaesthesia. The patient was operated within five days of the injury. (mean-3 days). The local examination of injured shoulder was done to look for the attitude, swelling, deformity and loss of function. Any nerve injury was also carefully looked for and noted. Local neurological deficit of axillary nerve was done. Fracture was stabilized temporarily by POP U- slab and arm sling. A thorough preoperative assessment of the patients was done, which included general condition of the patient and clinical (Inspection, Palpation, Measurements, Movements, Associated injuries) and radiological assessment of the type of the fracture. After initial evaluation for associated medical problem and getting clearance from respective departments, patient was taken for surgery.

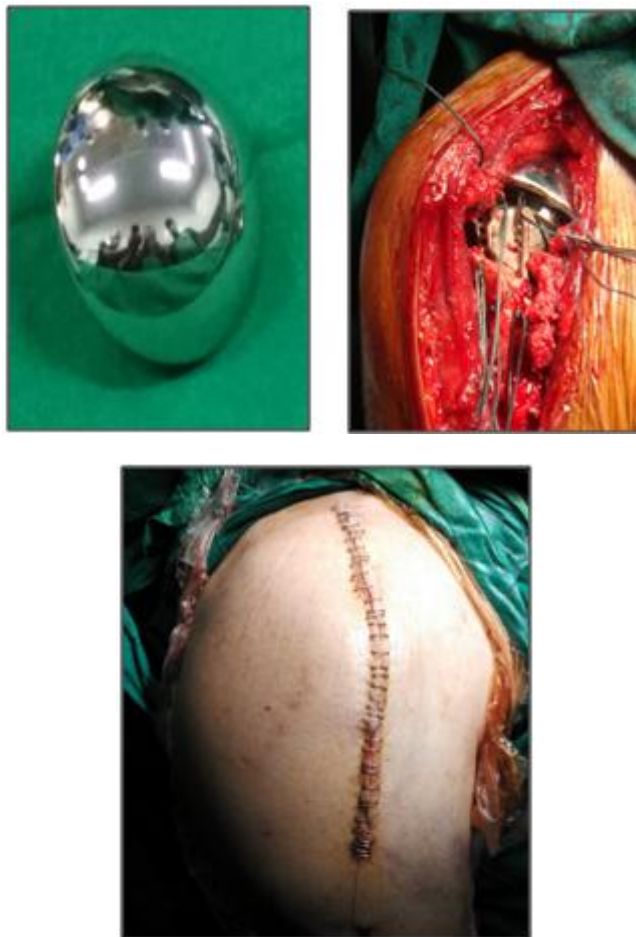
A modular prosthesis (Depuy Global Fx System) was used. Its stem was 130-mm long and 8 mm thick for 8 patients; and 12 received stem size of 140 mm long and 10 mm thick size. Its humeral head thickness was one size less or equal to the extracted humeral head and included 46x18 mm, 46x15 mm, 40x18 mm, and 40x15 mm.



Patients placed in semi Fowler position. Drape the arm free, because it will have to be moved during the approach. For most cases, an extended delto-pectoral incision will be adequate to allow exposure to all involved structures. This begins 3-4cm medial to the acromioclavicular joint coursing distally over the coracoid process and along the delto-pectoral fold. You will note that the cephalic vein is medial to the coracoid. In cases of hemi-arthroplasty alone, a limited exposure coming from coracoid process distally for a length of 8-10cm should allow adequate exposure. With the incision marked, a local anesthetic with Epinephrine was injected into the subcutaneous tissue to limit skin bleeding. The incision was then taken down through subcutaneous tissue to the delto-pectoral interval. The cephalic vein was identified and taken laterally with the deltoid.

The short head of biceps (supplied by the musculocutaneous nerve) and the coracobrachialis muscle (supplied by the musculocutaneous nerve) must be displaced medially before access can be gained to the anterior aspect of shoulder joint. Beneath the tendons lie the transversely running fibers of subscapularis muscle. External rotation to the arm was performed to stretch the subscapularis muscle, bringing the muscle belly into wound and making its superior and inferior borders easier to define. A blunt instrument was passed between the capsule and the subscapularis muscle to divide the subscapularis from insertion onto to the lesser tuberosity of humerus. The capsule was incised longitudinally to enter the joint wherever the selected repair must be performed at the time of closure.





With the greater and lesser tuberosities retracted out of the way by sutures used a bone clamp was used to retrieve the fractured humeral head. We measured the resected humeral head for height and diameter using the Humeral Head Template. The selected humeral head component must be approximate the resected humeral head height and radius of curvature. The Global Advantage Humeral Head trials for the fracture set range from 15,18 and 21mm heights and 44,48 and 52mm diameters are available. After selection of the humeral head component we extracted cancellous graft from the head for secure tuberosity fixation.

We reamed the medullary canal in the cases with blocked canal with the bony fragments to allow the placement of the prosthesis stem. For this four-hand reamer sizes are available in 2mm increments from 6 to 12mm, which were use in accordance of the requirement.

As per the requirement and the measurement of the head and extent of fracture the most appropriate stem size and head size were selected and the trial implant, which is the replica of the original implant, was used for identifying mistake of selection of size of implant or future problem in terms of restriction of movements of shoulder of original implant which may be encountered.

We attached the proper size trial head to a trial stem, and placed it into the intramedullary canal, with the inferior aspect of the head sitting on the proximal humerus shaft. Now with arm held at the patient's side, with elbow in 90-degree flexion and parallel to the floor and in zero degree rotation, a gentle traction was applied and the trial stem was lifted till the level of glenoid fossa. Note was made about the height of implant to be kept by noting the horizontal marks, which were present at the side of the stem.

Implants of appropriate size were selected as per trial implant figures. Stem was placed into the intramedullary canal following bone cement placement (PMMC). Holding the arm in 30-degree of external rotation by the assistant and placing the stem facing medially, into the intramedullary canal properly 30-degree retroversion was achieved. Appropriate size head was then fixed over the stem. Greater and lesser tuberosities were reconstructed over the implant with the help of Ethibond non-absorbable sutures. Layer by layer suturing was done with vicryl and lastly the skin was approximated with skin staplers. Sterile dressing was done and the operated arm was kept in shoulder immobilizer pouch. The mean duration for the surgery was 90 minutes.(range 60-120)

#### IV. Post-Operative Care

Postoperatively, a sling pouch was used. Gravity assisted pendulum exercises and passive motion exercises were allowed on day 1. At week 3, assisted forward elevation and supine external rotation and full elbow range-of-motion exercises were allowed for the next 6 weeks or longer (until adequate tuberosity healing). At weeks 6 to 8, stretching and strengthening of the shoulder with the help of a theraband was allowed under supervision. Daily home exercises were then prescribed for 6 to 10 weeks, and activities of daily living (bathing, eating, and personal hygiene) were allowed. Daily home exercises were encouraged for at least 6 months, and preferably one year.

Follow-up of patients was done at six weeks, three months and six months following the surgery. For all subjects, radiographs were performed at the end of six weeks, three months and six months follow-up. Patients were evaluated based on the, pain at fracture site, abnormal mobility, range of motion, clinical and radiological union of greater tuberosity. Constant Shoulder Score evaluated final outcome.

Category score	Points
<b>1. Pain</b>	<b>15</b>
None	15
Mild	10
Moderate	5
Severe	0
<b>2. Activities of daily living- Activity level</b>	<b>20</b>
Full Work	4
Full Recreation/Sport	4
Unaffected Sleep	2
<b>3. Arm Positioning</b>	
Up to Waist	2
Up to Xiphoid	4
Up to Neck	6
Up to Top of Head	8
Above Head	10
<b>4. Strength of Abduction [Pounds]</b>	<b>25</b>
RANGE OF MOTION	<b>40</b>

<b>5. Forward Flexion</b>	
31-60 degrees	2
61-90 degrees	4
91-120 degrees	6
121-150 degrees	8
151-180 degrees	10
<b>6. Lateral Elevation</b>	
31-60 degrees	2
61-90 degrees	4
91-120 degrees	6
121-150 degrees	8
151-180 degrees	10
<b>7. External Rotation</b>	
Hand behind Head, Elbow forward	2
Hand behind Head, Elbow back	2
Hand to top of Head, Elbow forward	2
Hand to top of Head, Elbow back	2
Full Elevation	2
<b>8. Internal Rotation</b>	
Lateral Thigh	0
Buttock	2
Lumbosacral Junction	4
Waist (L3)	6
T12 Vertebra	8
Interscapular (T7)	10

<b>5. Forward Flexion</b>	
<b>31-60 degrees</b>	<b>2</b>
<b>61-90 degrees</b>	<b>4</b>
<b>91-120 degrees</b>	<b>6</b>
<b>121-150 degrees</b>	<b>8</b>
<b>151-180 degrees</b>	<b>10</b>
<b>6. Lateral Elevation</b>	
<b>31-60 degrees</b>	<b>2</b>

<b>61-90 degrees</b>	<b>4</b>
<b>91-120 degrees</b>	<b>6</b>
<b>121-150 degrees</b>	<b>8</b>
<b>151-180 degrees</b>	<b>10</b>
<b>7. External Rotation</b>	
Hand behind Head, Elbow forward	2
Hand behind Head, Elbow back	2
Hand to top of Head, Elbow forward	2
Hand to top of Head, Elbow back	2
Full Elevation	2
<b>8. Internal Rotation</b>	
Lateral Thigh	0
Buttock	2
Lumbosacral Junction	4
Waist (L3)	6
T12 Vertebra	8
Interscapular (T7)	10
<b>5. Forward Flexion</b>	
31-60 degrees	2
61-90 degrees	4
91-120 degrees	6
121-150 degrees	8
151-180 degrees	10
<b>6. Lateral Elevation</b>	
31-60 degrees	2
61-90 degrees	4
91-120 degrees	6
121-150 degrees	8
151-180 degrees	10
<b>7. External Rotation</b>	
Hand behind Head, Elbow forward	2
Hand behind Head, Elbow back	2
Hand to top of Head, Elbow forward	2
Hand to top of Head, Elbow back	2
Full Elevation	2
<b>8. Internal Rotation</b>	
Lateral Thigh	0
Buttock	2
Lumbosacral Junction	4
Waist (L3)	6
T12 Vertebra	8
Interscapular (T7)	10

The final assessment using Constant Shoulder score for outcome was interpreted as Excellent (86-100 points), Good (71-85 points), Fair (56-70), Poor (0-55 points)

**V. Results:**

The data obtained was analyzed and the final results were tabulated and interpreted as below. In the present study 65% of the patients were males and 35% were females. The male to female ratio was 1.85:1. In this study 95% of the patients were aged between 60 to 70 years and 5% were aged > 70 years. The mean age was 65.35 ± 5.58 years. Out of total 20 patients, 13 patients had right shoulder injury and 7 patients had left shoulder involved. All patients were followed up at 6 weeks, 3 months and 6 months with antero-posterior view. Axillary view was taken where required. Pain was present in 9 patients at the end of 6 weeks while it was present only in two patients at the end of 6 months follow up which was suggestive of good outcome. One patient experienced stiffness of shoulder and one had proximal migration of shoulder at the end of 6 months, which resulted in poor outcome in terms of constant shoulder score.

Complications	Distribution (n=20)	
	Number	Percentage
Excellent	5	25.00
Good	7	35.00
Fair	6	30.00
Poor	2	10.00
<b>Total</b>	<b>20</b>	<b>100.00</b>

**Table 1. Distribution of study population according to final outcome on constant shoulder score**

Variables	6 weeks	3 months	6 months	Mean increase	p value
-----------	---------	----------	----------	---------------	---------

	Mean	SD	Mean	SD	Mean	SD	Mean	SD	
Flexion	59.50	16.38	76.00	15.69	92.00	17.04	32.50	12.93	<0.001
Extension	25.00	8.27	34.50	6.05	43.00	6.57	18.00	5.23	0.019
Abduction	63.00	13.80	80.00	14.87	94.50	15.72	31.50	13.87	<0.001
Adduction	25.50	6.86	35.50	7.59	43.50	6.71	18.00	6.16	0.007
External rotation	31.50	7.45	42.00	8.34	51.50	9.33	20.00	6.49	<0.001
Internal rotation	33.00	8.01	44.50	8.87	57.00	11.74	24.00	10.46	0.012

Table 2. Comparison of range of movements

## VI. Discussion:

The fractures of proximal humerus accounts for 4 to 5% of all fractures; 11% of these entail 3- or 4-part fragments. For comminuted fractures, conservative treatment usually yields poor results, whereas osteosynthesis is often unfavorable in those who are osteoporotic. Improvement in surgical technique for shoulder hemiarthroplasty and the use of modular prostheses has enabled better functional outcomes. Restoration of humeral length and correct positioning of the tuberosities are the keys to success. Better results are usually achieved in primary than secondary hemiarthroplasty, which is the gold standard for nonviable or non-amenable fractures.<sup>2,8</sup> The present study evaluated the efficacy of functional outcome of shoulder hemi replacement in patients diagnosed as four-part fracture and four-part fracture dislocation in elderly patients.

It is reported that, there are marked gender differences, with approximately 70% of fractures occurring in women. Mayo clinic identified a predominance of proximal humerus fracture in women at ratio of 1.5:1 and Lind noted female to male ratio 3:14.<sup>13</sup> however, in the present study male preponderance was noted as 65% of the patients were males and the male to female ratio was 1.85:1.

In the present study most of the patients had history of fall (60%) followed by RTA (40%). Previous studies<sup>9-12</sup> has also reported that, the proximal humeral fractures are usually low-energy osteoporotic injuries in elderly. During impact on the shoulder, the head of the humerus is thought to fracture on the hard-packed bone of the glenoid, which acts as an anvil. Elderly patients, with medical co-morbidities or advanced osteoporosis are more likely to have displaced fractures.

In the present study pain was present in 9 patients (45%) at six weeks follow up and in 2 (10%) patients at three months follow up and persisted in those 2 (10%) patients till six month follow up. The complications of pain observed in the present study were comparable with a study by Kralinger et al.<sup>16</sup> in 2004 who reported moderate to severe pain in 35 out of 167 (21%) patients with mean age of 70 years. Similar pain pattern was also reported by Demirhan et al in 2003. In contrast Christoforakis JJ, et al.<sup>17</sup> in 2004 reported pain in as low as 1 out of 25 patients (3.8%) patients with mean age of 70 years while an earlier study by Zyto K, et al.<sup>14</sup> in 1998 reported pain in as high as 9 out of 27 (33%) patients with mean age of 71 years.

In this study the complications of proximal migration of GT and stiffness were noted in 1 patient each (5% each) at three months follow up and these complications persisted till six months follow up. In patient with GT migration, the patients was advised surgery for re-attachment and patient was non compliant while one patient who had stiffness, he was advised strict regimen of physiotherapy to improve his movement. The complications of tuberosity were reported in several other studies vary widely from 10% to 50%. Least frequency of complications is reported by Zyto et al.<sup>14</sup> where 3 out of 27 patients (11.11%) had greater tuberosity displacement whereas Mighel et al.<sup>18</sup> noted 16 out of 72 patients (22.22%) with tuberosity complications, Kralinger et al.<sup>17</sup> found these complications in 77 out of 167 patients (46%) and Boilcau et al.<sup>15</sup> in 2002 encountered tuberosity complications in as high as 50% of the patients. However, in the present study only one patient had proximal migration of GT (5%), which was substantially low compared to other studies reported in the literature. With regard to the stiffness noted in one patient (5%), studies reporting stiffness, as a complication of hemiarthroplasty in the literature could not be found; hence this could not be commented upon.

In the present study there was steady increase in mean range of movements pertaining to flexion, extension, abduction, adduction, external rotation and internal rotation from six weeks follow up three months and further increase was noted at six months follow up. The increase in mean range of motion observed at six months follow up compared to six weeks follow up was statistically significant (Table 12 in Results section) ( $p < 0.050$ ). The mean active forward flexion at six months follow up was noted as  $92 \pm 17.04$  and external rotation as  $51.5 \pm 9.33$ . The mean active forward flexion noted in the present study was comparable with several other studies by Prakash et al.,<sup>19</sup> Boilcau et al.<sup>15</sup> and Goldman et al.<sup>20</sup> but mean external rotation was high in the present study compared to these studies.

A recent study by Babhulkar A. et al.<sup>21</sup> from Pune India in 2011 on patients aged from 27 to 83 years reported that, at the final follow-up, the mean maximum forward flexion was  $143^\circ$  (SD,  $41^\circ$ ; range,  $45^\circ$ – $180^\circ$ ) and the mean maximum abduction was  $111^\circ$  (SD,  $47^\circ$ ; range,  $30^\circ$ – $180^\circ$ ), and which was  $92 \pm 17.04$  and  $94.50 \pm 15.72$ , in the present study respectively. However, authors did not report the pattern of increase in the range of motion. The difference in variation can be explained by the lower mean age (56 years) in the study by Babhulkar A. et al.<sup>21</sup>



In the present study final outcome at six months was assessed using constant shoulder score. The constant shoulder score at six month follow up ranged between 25 to 93 and mean score were found to be  $71.05 \pm 18.50$  suggestive of good outcome in study population.

Proper prosthetic height, which ultimately decides humeral height is critical to the success of prosthesis proximal humeral replacement and is challenging due to frequent fracture disruption of the medial metaphyseal calcar. Too low or high placement of the prosthesis can cause improper tensioning of the deltoid and supraspinatus. Positioning of the stem is extremely important.

Boileau et al.<sup>15</sup> reported that humeral lengthening  $>10$  mm due to proud prosthesis significantly led to tuberosity detachment and proximal migration of the prosthesis beneath the acromial arch, resulting in limited function. Excessive tension on the supraspinatus was observed following humeral lengthening. Shortening of the humerus was better tolerated clinically. Functional results were not significantly altered until humeral shortening reached or exceeded 15 mm. Intra-operatively, humeral height can be estimated based on the position of the prosthesis in the superior-inferior position where the greater and lesser tuberosity fragments get anatomically reduced and under minimal tension at the prosthetic interface. Cement fixation helps maintain appropriate humeral height. An anatomic approach to determining proper humeral height is performed by placing the proximal border of the prosthetic humeral head approximately 5.6 cm proximal to the superior border of the pectoralis major tendon. When the pectoralis major tendon is used as a guide, it is important to tag the superior border of the tendon humeral insertion with an identifiable unique suture that can be referenced.

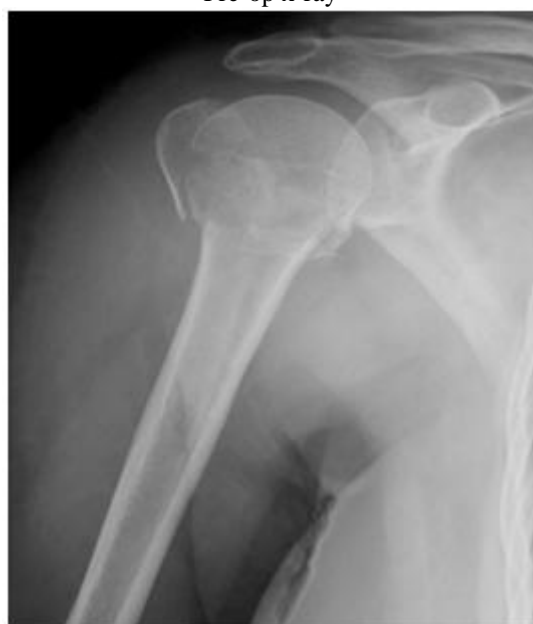Achieving optimal humeral version is another technical challenge related with hemiarthroplasty; the most common error is placing the component in excessive retroversion. Retroversion in excess can force malpositioning of the greater tuberosity in the horizontal plane, thereby creating excessive tension on the tuberosity repair with the arm in internal rotation. Normal humeral retroversion can range from  $15^\circ$  to  $30^\circ$ . It is recommended that, placing the humeral component between  $20^\circ$  and  $30^\circ$  of retroversion is the best practice. Improper version of prosthesis may result in anterior or posterior instability. The bicipital groove and transepicondylar axis can serve as consistent anatomic landmarks when determining humeral head retroversion.<sup>2</sup>

Overall the present study showed that, shoulder hemi arthroplasty in elderly patients diagnosed with four-part fracture and dislocation of proximal humerus is efficacious in terms of favorable functional outcome with lower rate of complications.

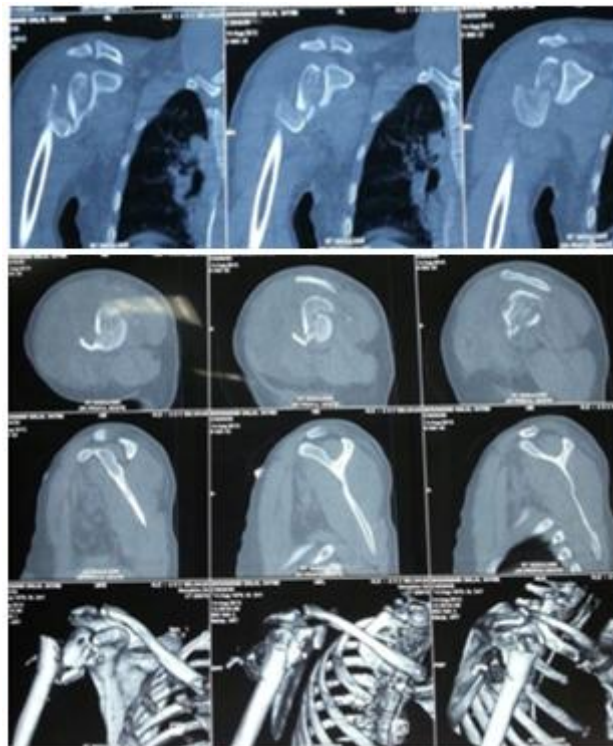
## **VII. Conclusion**

In Conclusion shoulder hemi arthroplasty in elderly patients diagnosed to have with four-part fracture and four-part fracture dislocation of proximal humerus is efficacious and results in favourable functional outcome as measured by constant shoulder score. Further shoulder hemi arthroplasty provides excellent range of movements at shoulder joint with lower rate of complications especially pain and shoulder stability.

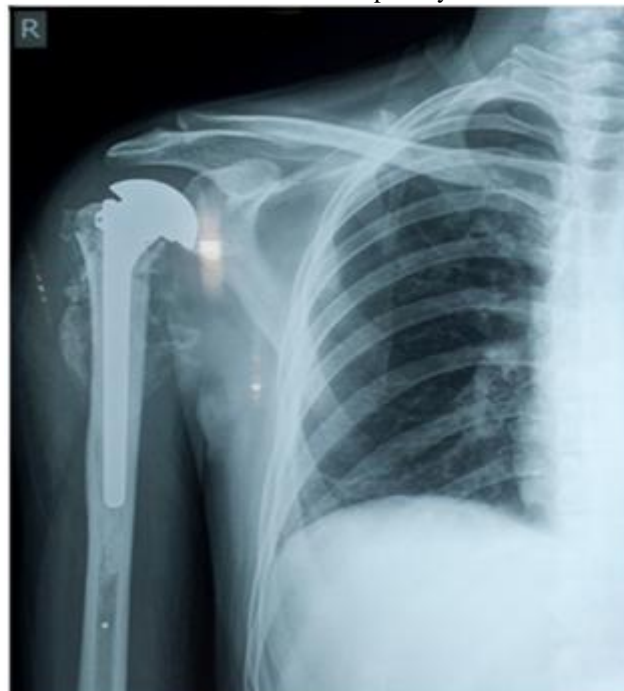Pre-op x-ray



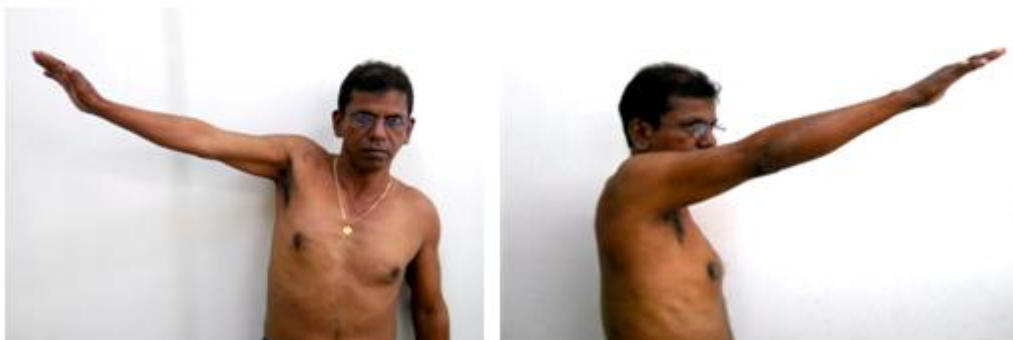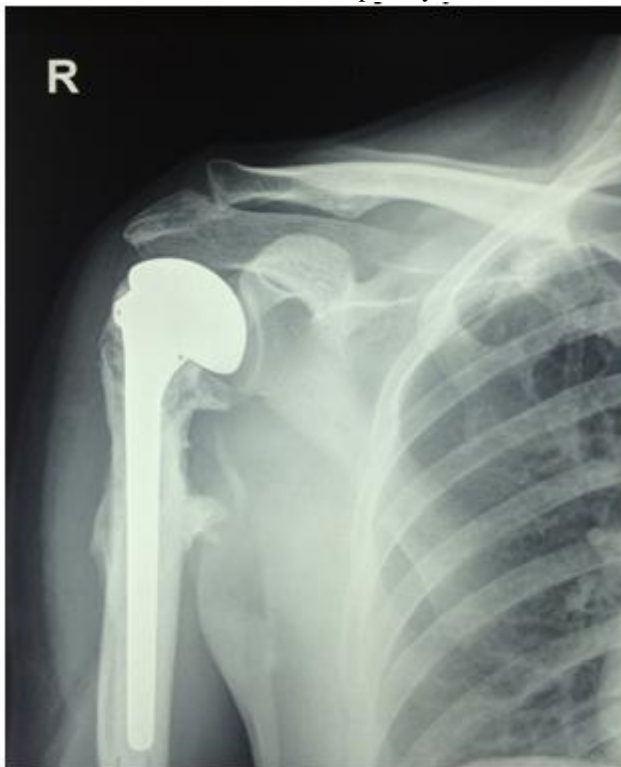CT scan

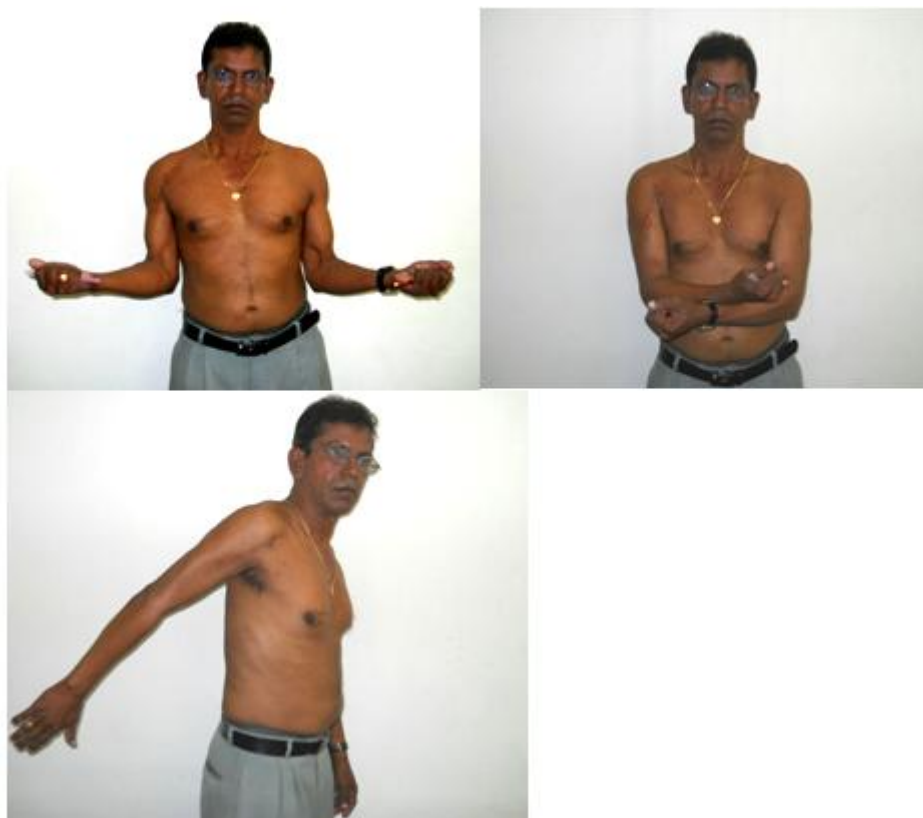

Immediate Post op x-ray



6months Post-op x-ray





### References:

- [1]. Magovern B, Ramsey ML. Percutaneous fixation of proximal humerus fractures. *Orthop Clin North Am* 2008;39:405-16.
- [2]. Cadet ER, Ahmad CS. Hemiarthroplasty for three- and four-part proximal humerus fractures. *J Am Acad Orthop Surg* 2012;20(1):17-27.
- [3]. Muncibi F, Paez DC, Matassi F, Carulli C, Nistri L, Innocenti M. Long term results of percutaneous fixation of proximal humerus fractures. *Indian J Orthop* 2012;46(6):664-7.
- [4]. Lenarz C, Shishani Y, McCrum C, Nowinski RJ, Edwards TB, Gobezie R. Is reverse shoulder arthroplasty appropriate for the treatment of fractures in the older patient? Early observations. *Clin Orthop Relat Res* 2011;469(12):3324-31.
- [5]. Kumar C, Gupta AK, Nath R, Ahmad J. Open reduction and locking plate fixation of displaced proximal humerus fractures. *Indian J Orthop* 2013;47(2): 156-60.
- [6]. Connor PM, Flatow EL. Complications of internal fixation of proximal humeral fractures. *Instr Course Lect* 1997;46:25-37.
- [7]. Gerber C, Werner CM, Vienne P. Internal fixation of complex fractures of the proximal humerus. *J Bone Joint Surg Br* 2004;86(6):848-55.
- [8]. Min W, Davidowitch RI, Tejwani NC. Three- and Four-Part Proximal Humerus Fractures - Evolution to Operative Care *Bulletin of the NYU Hospital for Joint Diseases* 2012;70(1):25-34.
- [9]. Raghuvanshi R, Waikhom S, Singh MA, Singh CA, Datta S, Marbaniang GB, et al. Internal Fixation of Displaced Proximal Humerus Fractures Using PHILOS: A Prospective Study. *International J Sci Res (IJSR)* 2015;4(3):437-41.
- [10]. Kannus P, Palvanen M, Niemi S, Parkkari J, Järvinen M, Vuori I. Osteoporotic fractures of the proximal humerus in elderly Finnish persons: sharp increase in 1970 to 1998 and alarming projections for the new millennium. *Acta Orthop Scand* 2000;71:465-70.
- [11]. Palvanen M, Kannus P, Niemi S, Parkkari J. Update in the epidemiology of proximal humeral fractures. *Clin Orthop Relat Res* 2006;442:87-92.
- [12]. Court Brown CM, Caesar B. Epidemiology of adult fractures: a review. *Injury* 2006;37:691-7.
- [13]. Lind T, Kronerck, JJ. The epidemiology of fractures of proximal humerus. *Arch Orthop Trauma Surg* 1989; 108:285-7.
- [14]. Zyto K. Non-operative treatment of comminuted fractures of the proximal humerus in elderly patients. *Injury* 1998;29(5):349-352.
- [15]. Boileau P, Krishnan SG, Tinsi L, Walch G, Coste JS, Molé D. Tuberosity malposition and migration: Reasons for poor outcomes after hemiarthroplasty for displaced fractures of the proximal humerus. *J Shoulder Elbow Surg* 2002; 11:401-12.
- [16]. Kralinger F, Schwaiger R, Wambacher M, Farrell E, Menth-Chiari W, <http://www.ncbi.nlm.nih.gov/pubmed/?term=Lajtai+G%5BAuthor%5D&cauthor=true&cauthoruid=15046436> Lajtai G, et al. Outcome after primary hemiarthroplasty for fracture of the head of the humerus. A retrospective multicenter study of 167 patients. *J Bone Joint Surg Br* 2004;86(2):217-9.
- [17]. Christoforakis JJ, Kontakis GM, Katonis PG, et al. Shoulder hemiarthroplasty in the management of humeral head fractures. *Acta Orthop Belg.* 2004;70(3): 214-8.
- [18]. Mighell MA, Kolm GP, Collinge CA, Frankle MA. Outcomes of hemiarthroplasty for fractures of the proximal humerus. *J Shoulder Elbow Surg* 2003; 12:569-77.
- [19]. Prakash U, McGurty DW, Dent JA. Hemiarthroplasty for severe fractures of the proximal humerus. *J Shoulder Elbow Surg* 2002;11:428-30.
- [20]. Goldman RT, Koval KJ, Cuomo F, Gallagher MA, Zuckerman JD. Functional outcomes after humeral head replacement for acute three- and four-part proximal humeral fractures. *J Shoulder Elbow Surg* 1995;4:81-6.
- [21]. Babhulkar A, Shyam AK, Sancheti PK, Shah K, Rocha S. Hemiarthroplasty for comminuted proximal humeral fractures. *J Orthop Surg (Hong Kong)* 2011;19 (2):194-9.