

Incidental Gallbladder Carcinoma- A Retrospective Study

Aditi Raina¹, Malay Bajpai², Indubhushan³

^{1,2}(Associate Professor, Department of Pathology, Rama Medical College, Hapur, India)

³(Professor and HOD Department of Pathology, Rama Medical College, Hapur, India)

Abstract: Gallbladder carcinoma is a highly malignant tumor with a poor prognosis; the incidence of incidentally diagnosed gallbladder cancer has increased with the increasing number of patients undergoing cholecystectomy (1-3). We report our experience with gallbladder carcinoma incidentally diagnosed during or after cholecystectomy performed for cholelithiasis. **Aims & Objectives:** We report our experience with gallbladder carcinoma incidentally diagnosed during and after cholecystectomy performed for cholelithiasis. **Observation:** We retrospectively reviewed our surgery records. A total of 464 patients underwent cholecystectomy from January 2014 to January 2016. In 3 of patients adenocarcinoma was present in the pathologic specimens.

Conclusion: A diagnosis of gall- stones is an indication for cholecystectomy as gallbladder cancer runs a short course with a poor prognosis.

Keywords: gall bladder carcinoma, incidental

I. Introduction.

Gallbladder carcinoma is a highly malignant tumor with a poor prognosis; the incidence of incidentally diagnosed gallbladder cancer has increased with the increasing number of patients undergoing cholecystectomy (1-3). The incidence of intra or post-operative incidental gallbladder carcinoma diagnosis is estimated between 0.2 and 2.8%; in this group, 15-30% of patients prove to be asymptomatic at the time presentation, without clinical evidences, intra or pre-operative, of neoplasm(4-6). We report our experience with gallbladder carcinoma incidentally diagnosed during or after cholecystectomy performed for cholelithiasis.

II. Aims And Objectives

To find the incidence of gallbladder carcinoma incidentally diagnosed during or after routine cholecystectomy performed for cholelithiasis.

III. Methods

We retrospectively reviewed our surgery records for the total number cholecystectomies with incidental histological evidence of gallbladder cancer at Rama Medical College Hospital & Research Centre, Hapur. A total of 464 patients underwent cholecystectomy from January 2014 to December 2015. Our inclusion criteria were patients with gallstone disease undergoing cholecystectomy. Patients with a clinical suspicion of malignancy and/or gallbladder polyp detected on pre-operative ultrasonography were excluded. The patients were 54 males and 410 females, mean age was 41.1 years. In 3 of 464 patients adenocarcinoma was present in the pathologic specimens (0.6%).

IV. Results

Of 464 patients who underwent cholecystectomy, incidental carcinoma was diagnosed histopathologically in 3 cases (0.6%). Malignancy was not suspected in any of these patients neither clinically nor on pre-operative ultrasonography. All 3 patients were females (Table 1), and the mean age was 43.3 years old. Tumor staging was determined according to the 6th edition of the TNM staging system of the UICC (7).

Table I- Histological diagnosis & TNM staging of patients with incidental gall bladder carcinoma

Patient	Age/Sex	Ultrasound finding	Histological diagnosis	TNM stage
1	31/F	Wall thickening	Adenocarcinoma	T _{1b} N ₀ M _x
2	41/F	Impacted stone at neck	Papillary Adenocarcinoma	T ₂ N ₁ M _x
3	58/F	Wall thickening	Adenocarcinoma	T ₃ N ₀ M _x

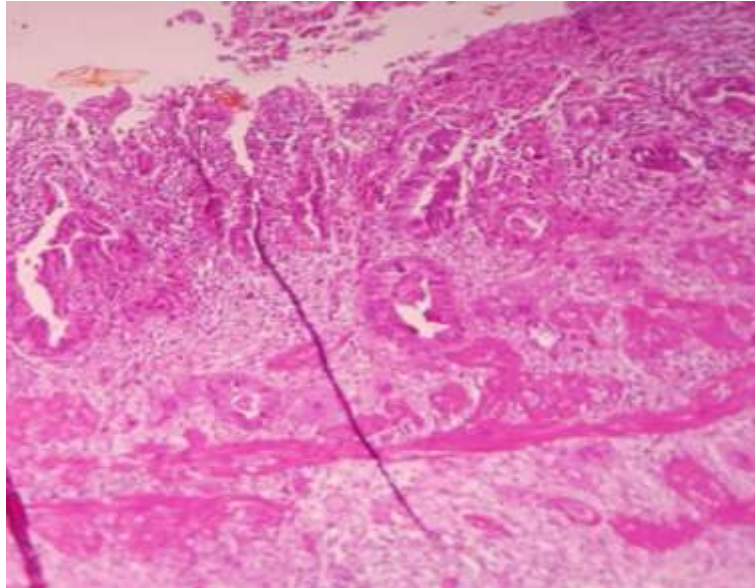
V. Discussion And Conclusions

The incidence of gallbladder carcinoma was found to be of 0.6%, in our study, similar to the incidence in other studies similar to incidence in published literature (8,9). The risk factors widely related to the gallbladder cancer are advanced age and gallstones disease All three of our patients were admitted with a

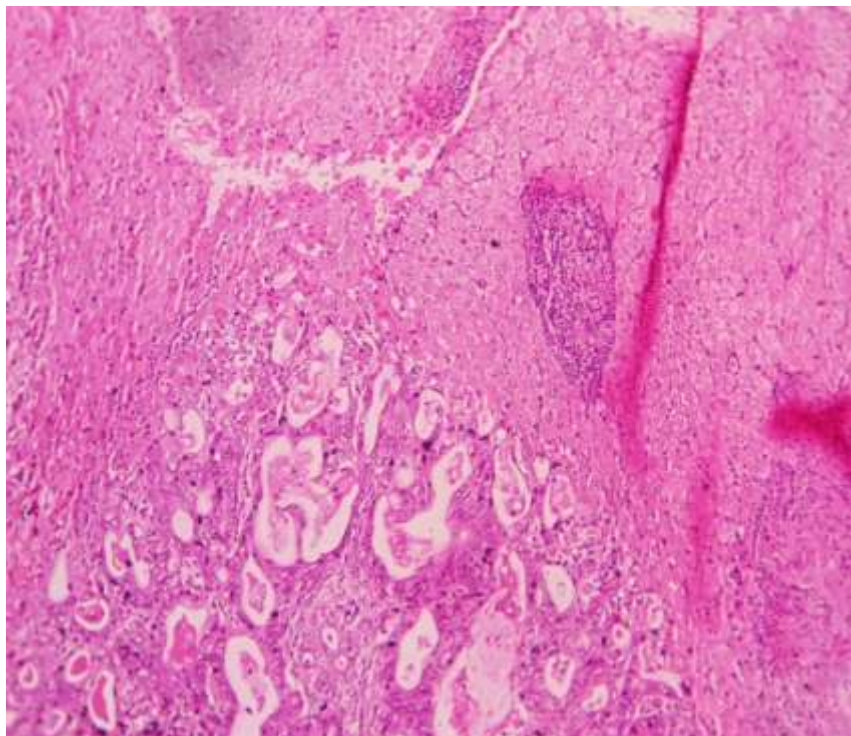
diagnosis of cholecystitis. The risk of GBC increases with increasing size of the gall stones—patients with larger stones (>3 cm) have about a ten times higher risk of having GBC as compared to those with smaller (<1cm) stones (10,11). Other risk factors are female sex, obesity, increasing age, typhus carrier, porcelain gallbladder and a single, large, sessile (> 10 mm. in size) polyp (12). Patients with GBC are around 15–20 years older than patients with gallstones, suggesting that the intra-epithelial evolution takes over 10 years. In the era of laparoscopic cholecystectomy for treatment of benign diseases incidental, gallbladder carcinoma has dramatically increased and allows to detect cancer at early stages with a better prognosis (13-15) In all three of our patients there was no clinical or radiological suspicion of carcinoma. In one of the patients , a 2 cm polyp near neck was identified during surgery that had been erroneously reported as an impacted stone on ultrasonography. The other two patients showed wall thickening on ultrasound examination. A gall bladder wall thickened due to the presence of long standing gall stones can look quite similar to wall thickening due to gall bladder carcinoma and the two may be hard to differentiate. The therapeutic approach to gall bladder cancer is applied according to the stage of tumor. (6,7). Liver bed invasion was observed in one of three patients. The incidence of gallbladder carcinoma was found to be of 0.6%, in our study, similar to the incidence in other studies. Hence, a diagnosis of gall- stones is an indication for cholecystectomy as gallbladder cancer runs a short course with a poor prognosis.

References

- [1]. Glauser PM, Strub D, Kaser SA, Mattiello D, Rieben F, Maurer CA. Incidence, management, and outcome of incidental gallbladder carcinoma: analysis of the database of the Swiss association of laparoscopic and thoracoscopic surgery. *Surg Endo-sc.* 2010;24:2281–2286.
- [2]. Genç V, Kırımker Onur E, Akyol C, Kocaay AF, Karabörk A, Tüzüner A, Erden E, Karayalçın K. Incidental gallbladder cancer diagnosed during or after laparoscopic cholecystectomy in members of the Turkish population with gallstone disease. *Turk J Gastroenterol.* 2011;22(5):512–516.
- [3]. Yildirim E, Celen O, Gulben K, Berbeglou U. The surgical management of incidental gallbladder carcinoma. *EJSO.* 2005;31:45–52.
- [4]. Clemente G, Nuzzo G, De Rose AM, Giovannini I, La Torre G, Ardito F, Giulante F: Unexpected gallbladder cancer after laparoscopic cholecystectomy for acute cholecystitis: a worrisome picture. *J Gastrointest Surg* 2012, (16):1462–8.
- [5]. Benoist S, Panis Y, Fagniez PL: Long-term Results of the curative Resection for carcinoma of the Gallbladder. *The Am J Surg* 1998, 175:118–22.
- [6]. Bertran E, Heise K, Andia ME, Ferreccio C: Gallbladder cancer: Incidence and survival in a high-risk area of Chile. *Int J Cancer* 2010, 127:2446–54.
- [7]. International Union Against Cancer. TNM classification of malignant tumours. 6th edition. Sobin LH, Wittekind Ch. , editors. Wiley-Liss; New York: 2002.
- [8]. Hueman MT, Vollmer CM Jr, Pawlik TM. Evolving treatment strategies for gallbladder cancer. *Ann Surg Oncol.* 2009;16:2101–2115.
- [9]. Mekeel KL, Hemming AW. Surgical management of gallbladder carcinoma: a review. *J gastrointest Surg.* 2007;11:1188–1193.
- [10]. Diehl AK. Gallstone size and the risk of gall bladder cancer. *JAMA* 1983;250:2323–644
- [11]. Lownfels AB, Walker AM, Althaus DP, Townsend G, Domellof L. Gall stone growth, size and risk of gall bladder cancer: An interracial study. *Int J Epidemiol* 1989;18:50–4.
- [12]. Miller G, Jarnagin WR. Gallbladder carcinoma. *EJSO.* 2008;34:306–312.
- [13]. Shimizu T, Arima Y, Yokomuro S, Yoshida H, Mamada Y, Nomura T, Taniai N, Aimoto T, Nakamura Y, Mizuguchi Y, Kawahigashi Y, Uchida E, Akimaru H, Tajiri T. Incidental gallbladder cancer diagnosed during and after laparoscopic cholecystectomy. *J Nippon Med Sch.* 2006;73:136–140.
- [14]. Yokomuro S, Arima Y, Mizuguchi Y, Shimizu T, et al. Occult gallbladder carcinoma after laparoscopic cholecistectomy: a report of four cases. *J Nippon Med Sch.* 2007;74:300–305.
- [15]. Varshney S, Buttirini G, Gupta R. Incidental carcinoma of the gallbladder. *EJSO.* 2002;28:4–10.



Photomicrograph of Patient 1 showing incidental carcinoma



Photomicrograph of Patient 3 showing liver bed involvement