

A Retrospective Evaluation of Forsus Fatigue Resistance Device (FRD) Therapy on Sagittal Airway Dimensions.

Rishabh Gupta

(Department Of Orthodontics, Institute Of Dental Sciences, Jammu, India)

Corresponding Author: Rishabh Gupta

Abstract: Airway dimension is closely related to maintenance of a proper breathing pattern. The aim of this study is to investigate how Forsus FRD affects upper airway dimensions. Pre-and post-treatment lateral cephalograms of 20 patients who had been treated with Forsus FRD were used for this retrospective study. The mean age at the start of treatment was 16.2 +/- 3.8 years. Selected cephalometric variables at the beginning of the FRD phase (T1) and that following completion (T2) as well as the differences between the 2 values were recorded for each variable. The results indicated a palatal tipping of the maxillary incisors and a labial tipping of the mandibular incisors. The SPPS, MPS and IPS width measurements showed a mean increase but this was not found to be statistically significant. The change in SN-CVT showed a significant positive effect on changes in all variables related to the upper-airway dimension. On the other hand, changes in SNA, SNB and SN-MP did not significantly alter the upper-airway dimension. Forsus FRD therapy was not found to contribute to a significant increase in upper airway dimensions.

Keywords: Airway, Class II, Fixed functional appliance, Forsus

Date of Submission: 14 -12-2017

Date of acceptance: 25-12-2017

I. Introduction

Airway dimension is closely related to maintenance of a proper breathing pattern. A constricted upper airway may cause sleep-disordered breathing which in turn may lead to problems in pulmonary ventilation, oxygenation, sleep quality, sweating, and nocturnal enuresis. In addition, such patients, especially children, may show behavioural problems as well as an impaired cognitive performance.¹⁻⁴

Fixed functional appliances have been used extensively in young adults to compensate for a retrognathic mandible by dental movements. Since, significant dental changes are induced in such therapy, it is important to study the potential effect it has on airway dimension.⁵⁻⁷ The aim of this study is to investigate how Forsus FRD, a commonly used Fixed functional appliance, affects upper airway dimensions. The null hypothesis for this study is that there is no change in the upper airway dimensions with Forsus FRD therapy.

II. Materials And Methods

Pre-and post-treatment lateral cephalograms of 20 patients (8 male and 12 female) taken from author's own practice were used for this retrospective study.

Inclusion criteria ;

- ANB more than 4
- Overjet more than 5 mm
- Angle Class II molar and canine relationship
- No significant residual growth potential (CVMI stage 5 and 6)
- Average mandibular plane angle (Gonion-Menton to Frankfurt horizontal plane) of 22 ± 4 degrees.

Exclusion criteria

- Missing teeth
- Previous history of nasal or pharyngeal obstruction or related surgical treatments
- Congenital anomalies or endocrine problems

The patients had been treated with treated with a fixed orthodontic appliance and ForsusFatigueResistant Device (FRD; 3M Unitek, Monrovia, California) which is a semi-rigid class II corrector. The mean age at the start of treatment was 16.2 +/- 3.8 years. Lateral cephalograms made at the start as well as the end of FRD appliance treatment were selected. Mean treatment time with FRD appliance was 5 +/- 1.5 months. All the lateral cephalograms were traced on acetate matte sheet 0.003 inches thick at the same time and by the same operator. Comparable illumination was maintained while tracing all the cephalograms. All the specified

landmarks were located, and marked. The reference planes were drawn and bilateral images were averaged. A customised cephalometric analysis was used for this study (Table 1). In addition, following variables were used to evaluate the sagittal upper-airway dimension and head posture as defined by Hiyama et. al.⁸ (Fig 1):

- a. **SPPS:** The antero-posterior width of the pharynx measured between the posterior pharyngeal wall and the dorsum of the soft palate on a line parallel to the FH plane (the line through Po and Or) that runs through the middle of the line from PNS to P (5).
- b. **MPS:** The antero-posterior width of the pharynx measured between the posterior pharyngeal wall and the dorsum of the tongue on a line parallel to the FH plane that runs through P (6).
- c. **IPS:** The antero-posterior width of the pharynx measured between the posterior pharyngeal wall and the dorsum of the tongue on a line parallel to the FH plane that runs through C2i (7).
- d. **SN-CVT:** The angle formed by the SN plane and CVT (the line through C2 and C4) (8).

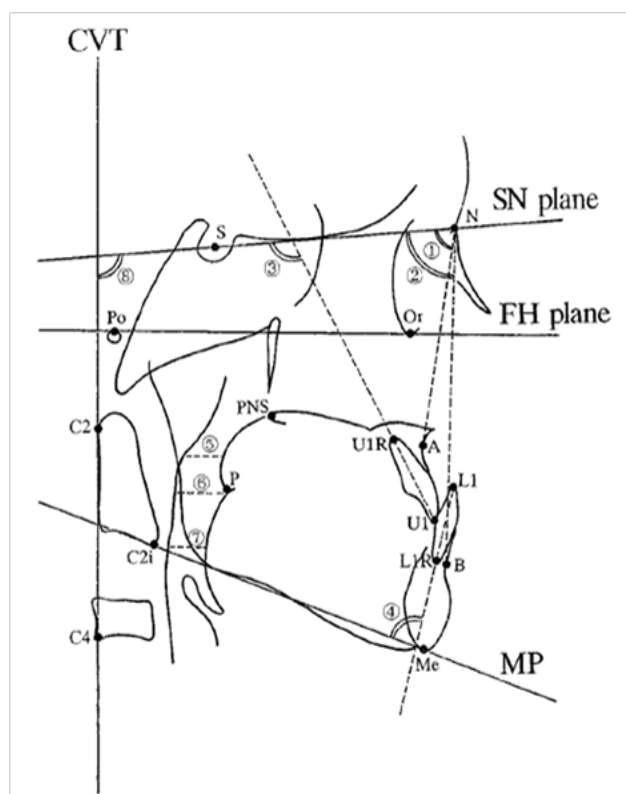


Fig. 1: Cephalometric variables used in the study as defined by Hiyama et. al.⁸

Values at the beginning of the FRD phase (T1) and that following completion (T2) as well as the differences between the 2 values were recorded for each variable. The effects of the FRD appliance on cranio-facial morphology and airway were evaluated by means of a paired t-test. To determine the relationship between the changes in the upper airway dimension and cranio-facial morphology, a multiple regression analysis was used.

III. Results

Table 1 shows the mean and standard deviation of each cephalometric variable measured at the beginning (T1) and at the end (T2) of the FRD phase as well as the differences between them (T2-T1) along with the results of the paired t-test. The mean value of U1-SN significantly decreased from 110.7⁰ to 106.2⁰, which indicated palatal tipping of the maxillary incisors. The mean value of L1 to MP significantly increased from 89.7⁰ to 97.4⁰ ($P < .01$), which indicated labial tipping of the mandibular incisors. The SPPS, MPS and IPS width measurements showed a mean increase but this was not found to be statistically significant. As a result, no significant changes were demonstrated in the upper-airway dimension. The SN-CVT angle also showed a mean increase but it was not a statistically significant change. Table 2 shows the results of correlation analysis performed between the craniofacial and pharyngeal cephalometric variables. Changes in SNA, SNB, SN-MP, and SN-CVT were considered as independent variables while the change in the upper-airway dimension was considered a dependent variable in the multiple-regression analysis. The regression coefficient shows the

magnitude and direction of an independent variable influencing a dependent variable excluding the effect of other independent variables. The change in SN-CVT showed a positive effect on changes in all variables related to the upper-airway dimension. This was found to be statistically significant ($P < 0.05$). On the other hand, changes in SNA, SNB and SN-MP did not significantly alter the upper-airway dimension.

Table 1

Parameter	Mean at T1	SD	Mean at T2	SD	Mean Difference (T2-T1)	SD	Significance
SNA	85.1 ⁰	2.6 ⁰	82.6 ⁰	3.0 ⁰	-2.5 ⁰	1.9 ⁰	NS
SNB	80.8 ⁰	2.8 ⁰	80.3 ⁰	2.5 ⁰	-0.5 ⁰	1.0 ⁰	NS
ANB	4.3 ⁰	2.2 ⁰	4.1 ⁰	2.1 ⁰	-0.2 ⁰	1.5 ⁰	NS
SN-MP	31.5 ⁰	3.2 ⁰	31.8 ⁰	3.7 ⁰	0.3 ⁰	1.3 ⁰	NS
U1-SN	110.7 ⁰	8.1 ⁰	106.2 ⁰	7.9 ⁰	-4.5 ⁰	2.2 ⁰	*
L1-SN	89.7 ⁰	6.4 ⁰	97.4 ⁰	5.8 ⁰	7.7 ⁰	1.3 ⁰	*
SPPS	15.8 mm	2.6 mm	16.1 mm	2.3 mm	0.3 mm	1.1 mm	NS
MPS	13.8 mm	3.2 mm	14.2 mm	2.9 mm	0.4 mm	2.0 mm	NS
IPS	13.6 mm	2.9 mm	13.9 mm	3.0 mm	0.3mm	1.3 mm	NS
SN-CVT	99.7 ⁰	5.0	100.2 ⁰	7.1 mm	0.5 ⁰	1.1 ⁰	NS

*

$P < 0.05$

Table 2

Dependent variables	Change in SPPS	Change in MPS	Change in IPS
SNA(b_1)	0.889(0.259)	0.090(0.054)	0.885(0.551)
SNB(b_2)	0.785(1.04)	1.60(0.995)	1.30(0.821)
SN-MP(b_3)	0.370(0.454)	0.675(0.442)	1.17(0.774)
SN-CVT(b_4)	0.216(0.715)*	0.597(0.738)*	0.758(0.707)*
R	0.92	0.76	0.72
R ²	0.84	0.58	0.52

b_1 - b_4 indicate regression coefficients; numbers in parentheses represent standardized regression coefficients; R, multiple correlation coefficients; R², coefficients of determination; * $P < 0.05$

IV. Discussion

Fixed functional therapy is indicated in young adults to achieve dento-alveolar compensation for Class II skeletal discrepancy. This is done by moving the upper dentition distally and the lower dentition mesially along with a clockwise rotation of the occlusal plane. Sagittal growth potential of maxilla is also sought to be minimised. The effects of the Forsus FRD in our study were recorded as mainly dental changes of maxillary and mandibular teeth. U1-SN angle showed a mean decrease while L1-MP angle showed a mean increase, both of which were statistically significant. No significant changes were observed in the SNA, SNB and ANB angles. SN-MP angle also showed a mean increase though it was not statistically significant. This is in agreement with previous studies which have investigated the effects of fixed functional appliances⁵⁻⁶.

The upper-airway dimensions did not show significant changes during treatment. In a cephalometric study, Kinzinger et al also investigated the effect of two fixed functional appliances on the airway morphology.⁹ The appliances were found to have a similar effect on airway depth. Increases in anterior facial height were found to increase the upper posterior airway width, while increases in posterior facial height and the mandible's forward displacement were related inversely to the decreases in depth in the central and lower posterior airway.

Similar studies also reported changes in incisor inclination at the end of treatment, though they have used different measurement variables¹⁰⁻¹⁵. Few studies have reported no change in the posterior airway dimensions after orthodontic treatment with extractions while others have reported a change in the airway dimensions as a result of incisor movements¹⁰. The results for the latter have been contradictory¹¹⁻¹². In a recent tomography study, Chen et al., found a significant correlation between the amount of incisor retraction and the amount of retraction of the hyoid bone, which supposedly led to the narrowing of the hypopharynx¹³.

Change in SN-CVT was found to have a significantly positive influence on changes in SPPS, MPS, and IPS as indicated by the multiple-regression analysis⁸. A greater change in SN-CVT was associated with a greater change in the upper airway dimension (Table 2). Therefore, head posture should be same while evaluating the relationship between changes in the cranio-facial factors and upper-airway dimension. SN-CVT at T1 and T2 showed no statistically significant changes (Table 1) indicating that the airway passage

measurements were not affected by the positioning of the patients. In addition, skeletal variables such as SNA, SNB, and SN-MP were used as independent variables in this study but they were found to have no significant effect on the change in SPPS (Table 2). Thus, Forsus FRD therapy did not cause significant changes in the upper-airway dimension.

V. Conclusion

The null hypothesis is thus accepted. Forsus FRD therapy does not contribute to a significant increase in upper airway dimensions. This study was a 2-dimensional cephalometric measurement of the upper-airway which is essentially a 3-dimensional structure. Though, a high correlation has been reported between posterior airway size as measured on cephalometric radiographs and the pharyngeal volume as measured on tomographic scans. It is suggested that the clinical effects of Forsus FRD on respiratory function should be evaluated 3-dimensionally for a more complete picture.

References

- [1]. Marcus CL. Pathophysiology of childhood obstructive sleep apnea: current concepts. *Respir Physiol.* 2000;119: 143–154.
- [2]. Katyal V, Pamula Y, Martin AJ, et al Craniofacial and upper airway morphology in pediatric sleep-disordered breathing: systematic review and meta-analysis. *Am J OrthodDentofacialOrthop.* 2013;43:20–30.
- [3]. Carroll JL. Obstructive sleep-disordered breathing in children: new controversies, new directions. *Clin Chest Med.* 2003;24:261–282.
- [4]. Tran KD, Nguyen CD, Weedon J, Goldstein Child behavior and quality of life in pediatric obstructive sleep apnea. *Otolaryngol Head Neck Surg.* 2005;131:52–57
- [5]. Bilgic, F, Hamamci O, Bas,aran G. Comparison of the effects of fixed and removable functional appliances on the skeletal and dentoalveolar structures. *AustOrthod J.* 2011;27: 110–116. 17.
- [6]. Franchi L, Alvetro L, Giuntini V, Masucci C, Defraia E, Baccetti T. Effectiveness of comprehensive fixed appliance treatment used with the Forsus Fatigue Resistant Device in Class II patients. *Angle Orthod.* 2011;81:678–683
- [7]. Jena AK, Singh SP, Utreja AK. Sagittal mandibular development effects on the dimensions of the awake pharyngeal airway passage. *Angle Orthod.* 2010;80: 1061–1067.
- [8]. Hiyama S, Suda N, Suzuki MI, Tsuiki S, Ogawa M, Suzuki S, Kuroda T. Effects of maxillary protraction on craniofacial structures and upper airway dimension. *Angle Orthod.* 2002;72:43–47.
- [9]. Kinzinger G, Czapka K, Ludwig B, Glasl B, Gross U, Lissou J. Effects of fixed appliances in correcting Angle Class II on the depth of the posterior airway space: FMA vs. Herbst appliance—a retrospective cephalometric study. *J OrofacOrthop.* 2011;72:301–320.
- [10]. Valiathan M, El H, Hans MG, Palomo MJ. Effects of extraction versus non-extraction treatment on oropharyngeal airway volume. *Angle Orthod.* 2010;80:1068–1074.
- [11]. Germec-Cakan D, Taner T, Akan S. Uvulo-glossopharyngeal dimensions in non-extraction, extraction with minimum anchorage, and extraction with maximum anchorage. *Eur J Orthod.* 2011;33:515–520. 19.
- [12]. Wang Q, Iia P, Anderson NK, Wang L, Lin J. Changes of pharyngeal airway size and hyoid bone position following orthodontic treatment of Class I bimaxillary protrusion. *Angle Orthod.* 2012;82:115–121. 20.
- [13]. Chen Y, Hong L, Wang CL, et al. Effect of large incisor retraction on upper airway morphology in adult bimaxillary protrusion patients. *Angle Orthod.* 2012;82:964–970.

Rishabh Gupta. "A Retrospective Evaluation of Forsus Fatigue Resistance Device (FRD) Therapy on Sagittal Airway Dimensions." *IOSR Journal of Dental and Medical Sciences (IOSR-JDMS)* 16.12 (2017): 01-04