

Osteosynthesis of Radialhead Fractures

*Dr. N. Krishna Prasad¹, Dr. K. Sunil Kumar², Dr. J. S. S. N. Manohar³

^{1,2} (Assistant Professor, Department of Orthopaedics, Dr. Pinnamaneni Siddhartha institute of medical sciences & research Foundation)

³ (Postgraduate 2nd year, Department of Orthopaedics, Dr. Pinnamaneni Siddhartha institute of medical sciences & research Foundation)

*Corresponding author: *Dr. N. Krishna Prasad1

Abstract: Radialhead is an important stabilizer of the elbow joint. Radialhead fractures are most common fractures of elbow joint. We intended to follow up the functional outcome of newly designed pre - contoured plates and herbet screws in the treatment of radialhead fractures

Materials And Methods: We prospectively reviewed 24 cases of radialhead fractures operated in our institute, out of which 8 cases are type 4 radialhead fractures associated with elbow dislocation that was reduced in emergency room and immobilized with above elbow slab followed by definitive treatment by precontoured plates and 0.8 mm k-wires, 6 cases are type 3 radialhead fractures treated with precontoured plate fixation. 10 cases are type 2 radialhead fractures treated with herbet screw fixation. All the patients were under periodic follow up for every 6 weeks till 1 year.

Results: Patients will be evaluated by clinical scoring system of MAYO ELBOW PERFORMANCE SCORE. 24 patients are followed up periodically and compared using 5 parameters of pain, ROM, stability, daily function, radiological union. Out of 10 type 2 fractures full range of movements are achieved for all 10 patients without any block to forearm rotation or instability of elbow joint. Out of 6 type 3 radialhead fractures 4 patients achieved good functional outcome and two cases had supination block. Out of 8 type 4 fractures 2 cases had valgus laxity

Conclusion: Our study shows better functional outcome of patients treated by osteosynthesis for radialhead fractures. Based on our clinical follow up several key points should be emphasised. CT scan is essential tool in preoperative planning of radialhead fractures

1. Pre-contoured plate should be placed in the safe zone of radialhead.

2. Kochers approach is preferred due to lesser risk of PIN injury.

3. Early ROM of elbow joint in 1st post operative week can be allowed in type 2, 3 radialhead fractures

Date of Submission: 06-12-2017

Date of acceptance: 14-12-2017

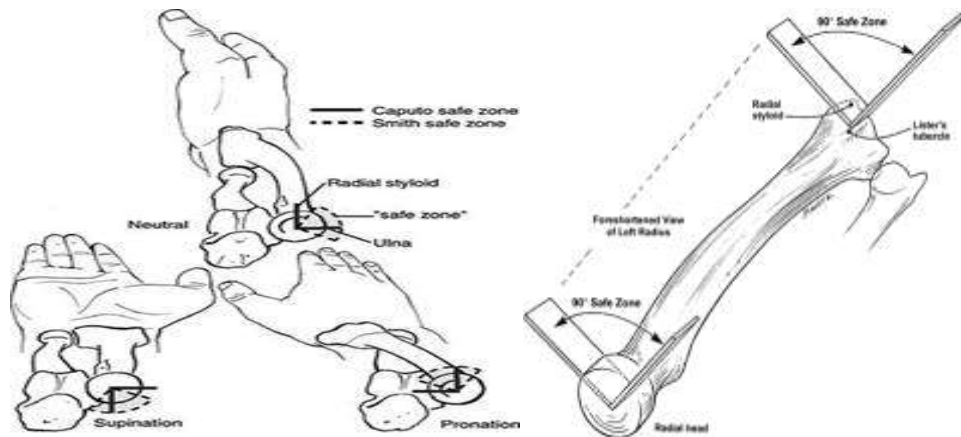
I. Introduction

Radialhead fractures are most common fractures of elbow joint. Mechanism of fracture is fall on outstretched hand due to valgus and axial load of the forearm causing impaction of radialhead on to capitellum and posteriolateral rotation of forearm generally associated with elbow dislocation. In the past excision or conservative management is the only treatment option which may end up in non-union or malunion. Osteosynthesis is done to prevent complications like instability of elbow joint, elbow stiffness, post traumatic arthritis of the elbow joint associated with radialhead fractures. Masons type 3, 4 radialhead fractures are associated with collateral ligament injuries, fractures of coronoid, capitellum and proximal ulna. Various treatment options include radialhead excision, osteosynthesis using precontoured plates and herbet screws, radialhead replacement with prosthesis. The purpose of this study is to analyze our experience with Masons type 2, 3, 4 radialhead fractures managed using precontoured plates and herbet screws.

II. Materials And Methods

We prospectively followed up 24 patients of Masons type 2, 3, 4 radialhead fractures operated from June 2012 to May 2016 in our institute excluding patients who expired due to medical conditions and patients who lost to followup. Out of 24 cases, 10 were type 2 radialhead fractures, 6 were type 3 radialhead fractures, 8 were type 4 radialhead fractures. Elbow dislocation was reduced in emergency and A/E pop slab was applied. All these patients were periodically followed up for every 6 weeks for a period of 12 months. The study included patient aged above 18 years patients with other associated fractures of upper limb were excluded from the study. Out of 24 cases, 14 were males and 10 were females with an average age of 43.6 years. Mechanism of injury is RTA for 16 cases and fall from height for 8 cases. All the patients has AP and lateral view of elbow joint were done at emergency department initially. CT scan was performed to identify the fracture pattern.

Surgery was performed under brachial block or general anesthesia. Tourniquet was used to diminish the blood loss and was deflated after 90 mins. Patient was set up in supine position and Kocher's approach was preferred. Inter-muscular plane was created between ECU and anconeus. Fore arm is kept in pronation during the procedure to protect PIN so that it moves more anteriorly. Several advantages when compared to the lateral approach like lesser risk of PIN injury, collateral ligament protection, good visualization of fracture fragments and elbow joint. Initially fracture reduction was done using 0.8mm K-wires and articular surface congruity is restored. Pre-contoured plate is placed in the safe zone of radial head region. The portion of the radial head that does not articulate with ulna (without interfering with forearm rotation). During surgery safe zone is identified by positioning the forearm in neutral rotation and placing the plate 10 degrees anterior to mid-axial line. Longitudinal line drawn between Lister's tubercle and radial styloid is used as a guide for plate placement.



All the patients were followed up periodically. 8 out of 10 cases of type 2 radial head fractures and 4 out of 6 type 3 radial head fractures early ROM of elbow joint was allowed within the first postoperative week. In type 4 radial head fractures ROM was delayed till 4 postoperative weeks. During the follow up of the cases, elbow AP and lateral radiographs were taken and clinically assessed using Mayo elbow performance score

MAYO ELBOW PERFORMANCE SCORE

Adapted from: Gill DR, JBJS 1998;80A:1327

Criteria	Points	Patient Score
Pain (45 points)		= 45
None	45	
Mild	30	
Moderate	15	
Severe	0	
ROM		
>100 degrees	20	= 20
50-100 degrees	15	
<50 degree	5	
Stability (10 points)		= 10
Stable	10	
Moderate instability	5	
Gross instability	0	
Daily function (25 points)		= 25
Combing hair	5	
Feeding oneself	5	
Hygiene	5	
Putting on shirt	5	
Putting on shoes	5	

Patient Score = 100

> 90 points = excellent, 75 to 89 points = good, 60 to 74 points = fair, and less than 60 points = poor

Stable = no apparent varus-valgus laxity clinically, moderate instability = less than 10 degrees of varus-valgus laxity, and gross instability = at least 10 degrees of varus-valgus laxity.

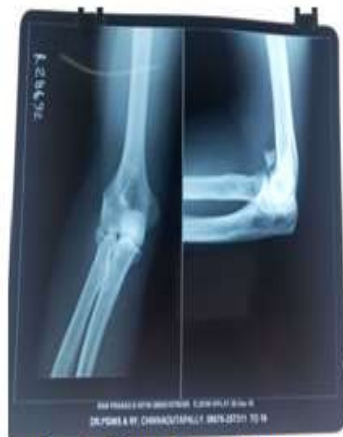III. Results

We followed up 24 patients with Masons type 2,3,4 radialhead fractures operated from June 2012 to May 2016. The scheme of surgical management was designed by visiting staff. 10 cases of type 2 radialhead fractures treated using Herbert screw fixation, 6 cases of type 3 and 8 cases of radialhead fractures treated with precontoured plate. No significant difference existed in gender ratio, mean age, injured limb, mechanism of trauma.

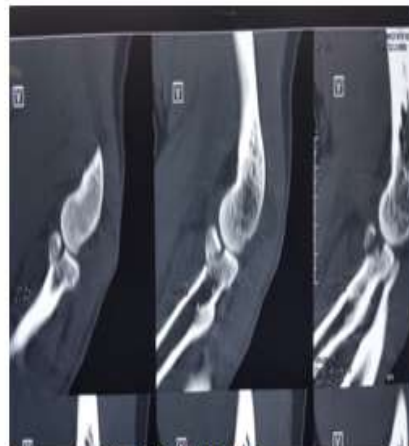MASONS CLASSIFICATION	TYPE 2	TYPE 3	TYPE 4
Case number	10	6	8
M/F ratio	6/4	4/2	4/4
Injured limb(RT/LT)	4/6	2/4	4/4
Trauma mechanism (RTA/Fall from height)	6/4	4/2	6/2
Functional outcome	94	83.33	90.2
pain	42	30	37.5
ROM	17	18.33	19
Stability	10	10	8.7
Daily function	25	25	25

Radiological union was achieved in all the cases. Overall 2 cases faced block in forearm rotation, two cases had valgus laxity, one case had local wound infection after one year of followup. Average functional outcome scores in three groups were 94, 83.33, 90.2 respectively. Case with infection was managed with local wound care, oral antibiotics.

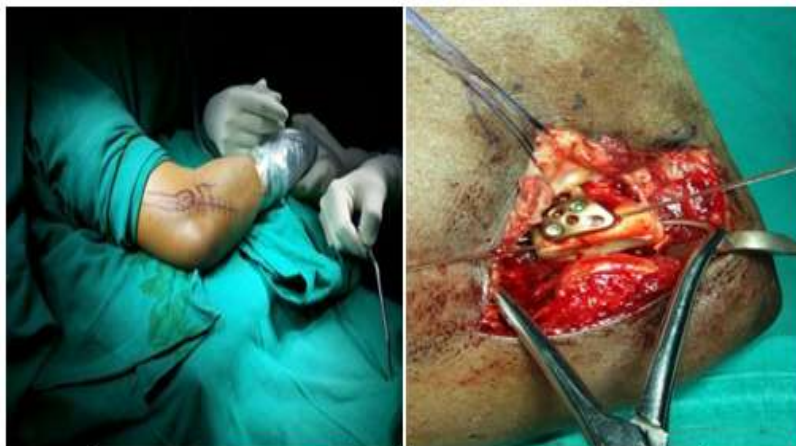ASE 1-45 yr old male patient sustained injury due to RTA



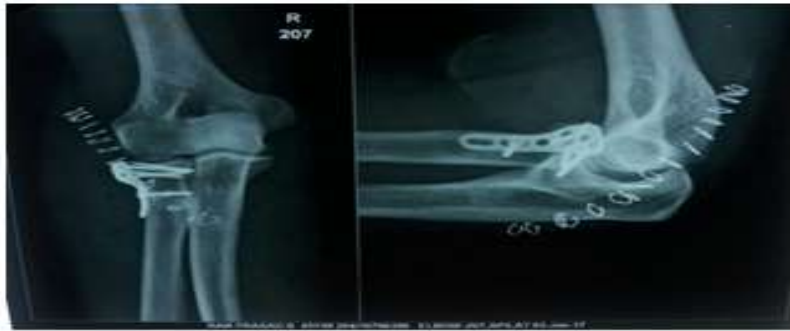Pre Op Xray-Type-3 Fracture



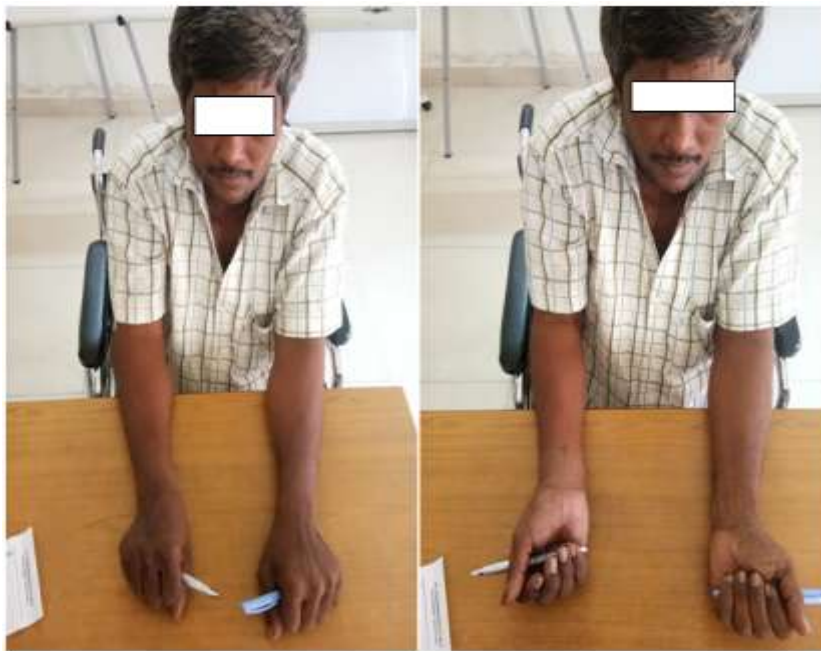CT-SCAN Picture



Intra-op picture showing plate placement in safezone.

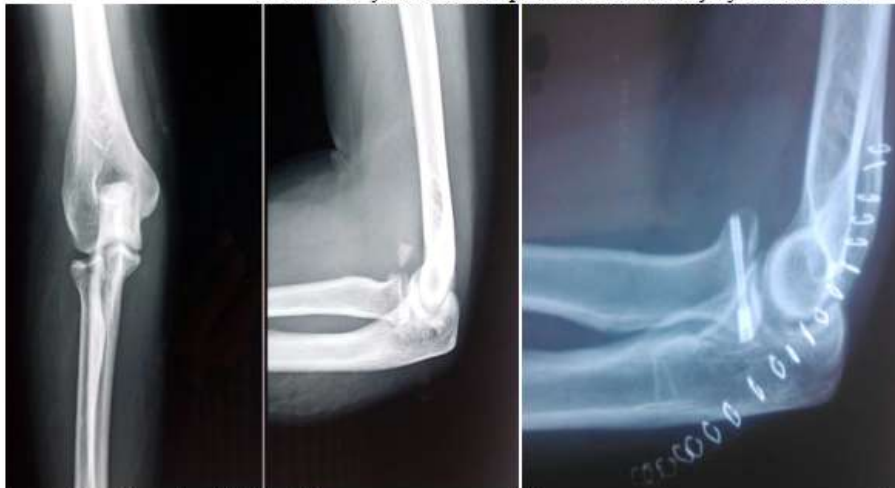

Post Op Xray



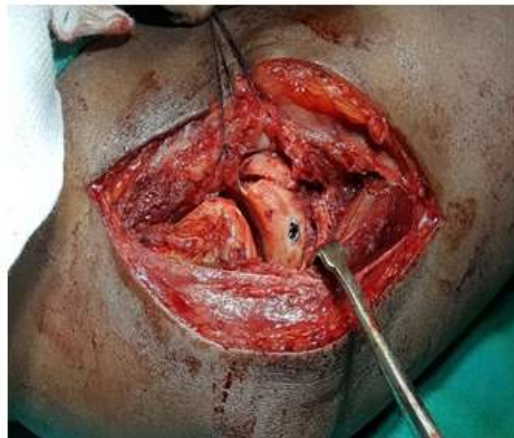
Elbow Rom At 6 Weeks Post Op

CASE 2-39 year old male patient sustained injury due to RTA.



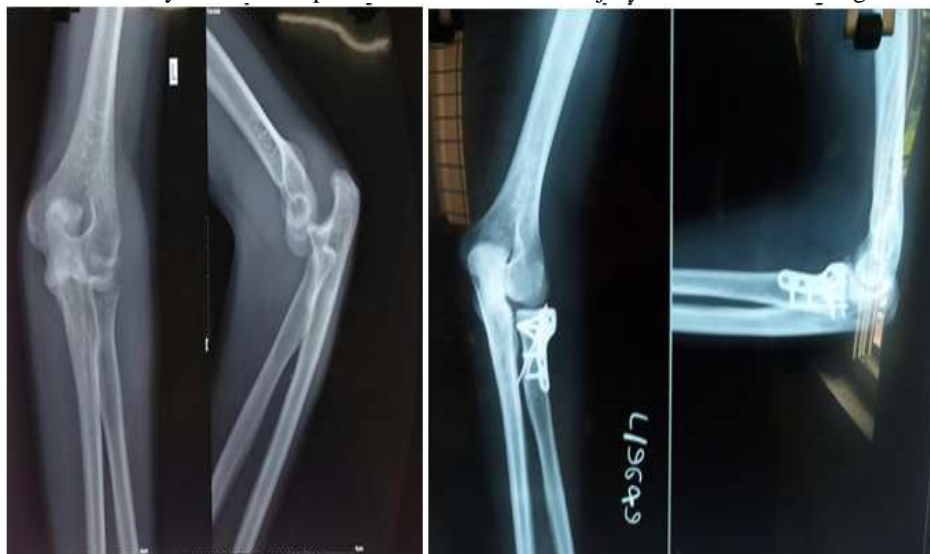Type 2 radialhead fracture-pre op xray

Post op xray

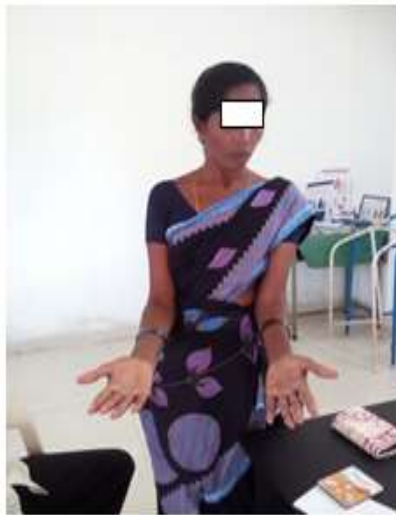
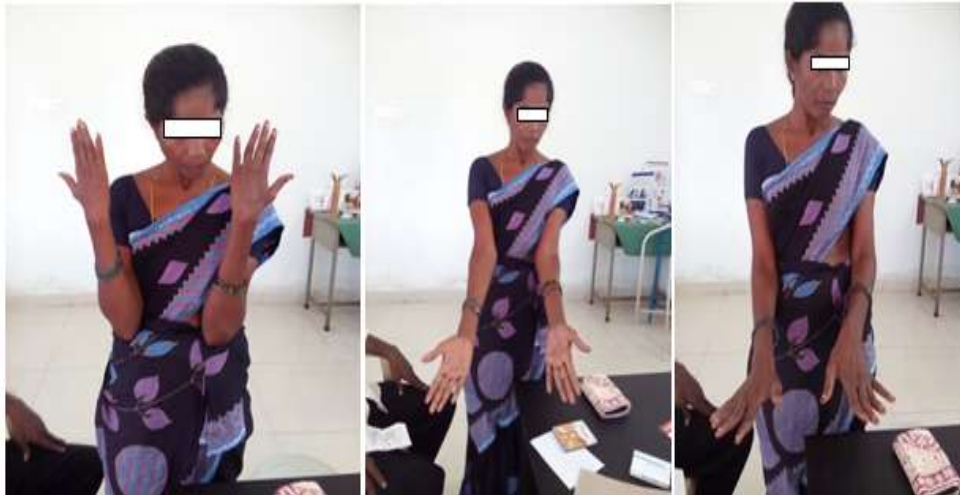
Intra op picture

ASE3-34 yr old female patient treated sustained injury due to fall from height

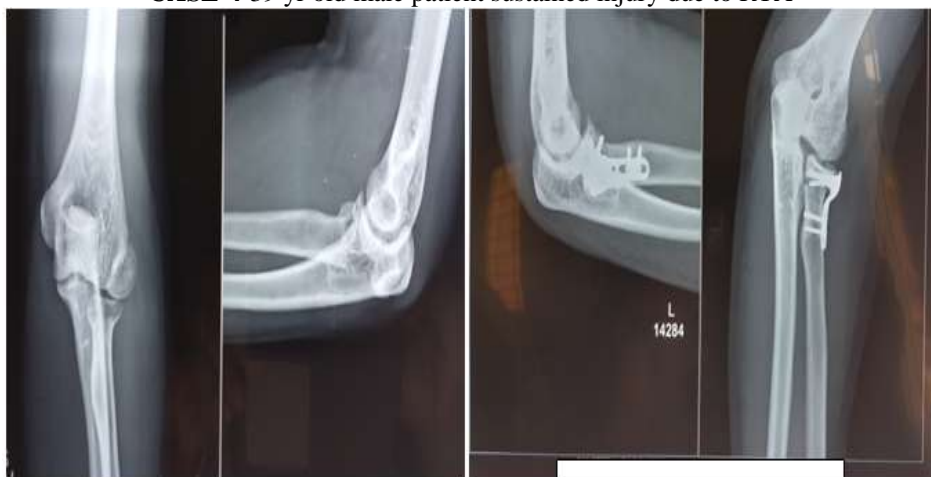

Type 4: radialhead fracture-fixed with precontoured plate and k-wire



Left elbow ROM at 3 months postoperative period

CASE-4-39 yr old male patient sustained injury due to RTA



IV. Discussion

Fixation of radialhead fractures remain a challenge for the surgeon.to achieve a satisfactory outcome, a well designed preoperative surgical strategy with minimal unnecessary soft tissue injury must be designed. Over the past few years, number of treatment modalities were developed like A/E pop cast immobilisation,

radialhead excision, replacement, internal fixation. Radialhead excision has complications like valgus laxity, Distal radioulnar joint instability that can be avoided by ORIF. In this article, precontoured plates, Herbert screws, 0.8mm k-wires were used for fixation. The goals of operative treatment are anatomical reduction especially in restoration of articular congruity, stable fixation for early rehabilitation, avoidance of complications like infection, instability of elbow joint. In our study we included a case series of 24 radialhead fractures followed up for a period of 1 year showed excellent results in terms of functional outcome with greater ROM and better stability of elbow joint.

For type II fractures, the best treatment options seem to be ORIF. Moreover, ORIF has the highest success rate in the treatment of type III fractures and seems to be better than resection as the complications of resection like instability of elbow can be avoided. Here, the ORIF with screws and plates had the best results.

References

- [1]. Clinical results after different operative treatment methods of radialhead and neck fractures. A systematic review and meta-analysis of clinical outcome J. Zwingmann *, M. Welzel, D. Dovi-Akue, H. Schmal, N.P. Su`dkamp, P.C. Strohm
- [2]. Duckworth AD, Clement ND, Jenkins PJ, Aitken SA, Court-Brown CM, McQueen MM. The epidemiology of radialhead and neck fractures. *J Hand Surg* 2012;37A:112–119
- [3]. A comparative study of internal fixation and prosthesis replacement for radialhead fractures of Mason type III Hong-Jiang Ruan & Cun-Yi Fan & Jun-Jian Liu & Bing-fang Zeng, *International Orthopaedics (SICOT)* (2009) 33:249–253
- [4]. Open reduction and internal fixation of comminuted fractures of the radialhead using low-profile mini-plates M. Ikeda, Y. Yamashina, M. Kamimoto, Y. Oka, *J Bone Joint Surg [Br]* 2003;85-B:1040-4.
- [5]. Ikeda M, Sugiyama K, Kang C. Comminuted fractures of radialhead: comparison of resection and internal fixation. *J Bone Joint Surg.* 2005;87(A):76.
- [6]. Lindenhovius AL, Felsch Q, Doornberg JN. Open reduction and Internal fixation compared with excision for unstable displaced fractures of the radialhead. *J Hand Surg.* 2007;32(A):630.
- [7]. Jackson JD, Steinmann SP. Radialhead fractures. *Hand Clin.* 2007;23:185-193.
- [8]. Kaas L, van Riet RP, Vroemen JP, Eygendaal D. The epidemiology of radialhead fractures. *J Shoulder Elbow Surg.* 2010;19:520-523.
- [9]. Duckworth AD, Clement ND, Jenkins PJ, Aitken SA, Court-Brown CM, McQueen MM. The epidemiology of radialhead and neck fractures. *J Hand Surg Am.* 2012;37:112-119.
- [10]. Kaas L, Sierevelt IN, Vroemen JP, van Dijk CN, Eygendaal D. Osteoporosis and radialhead fractures in female patients: a case-control study. *J Shoulder Elbow Surg.* 2012;21:1555-1558.

*Dr. N. Krishna Prasad. "Osteosynthesis of Radialhead Fractures." *IOSR Journal of Dental and Medical Sciences (IOSR-JDMS)* 16.12 (2017): 27-33