

## A Morphometric Study of the Mandibular Foramen in Dry Adult Human Mandibles - A Study in RIMS, Imphal.

Rajkumari K<sup>1</sup>, Nongthombam SS<sup>2</sup>, Chongtham RS<sup>3</sup>, Huidrom SD<sup>4</sup>,  
Tharani P<sup>5</sup>, Sanjenbam SD<sup>6</sup>.

<sup>1</sup>Post Graduate Trainee, <sup>2</sup>Professor, <sup>3</sup>Professor & HOD, <sup>4</sup>Post Graduate Trainee,

<sup>5</sup>Post Graduate Trainee, <sup>6</sup>Senior Resident.

Department of Anatomy, Regional Institute of Medical Sciences, Imphal, Manipur, India.

Corresponding Author: Rajkumari K

### Abstract:

**Background/ Introduction:** The mandibular foramen is present on the medial surface of the mandibular ramus. It leads into the mandibular canal which contains the inferior alveolar neurovascular bundle. It is an important landmark for inferior alveolar local anaesthetic block injection prior to dental surgeries on lower jaw. Inaccurate localization of mandibular foramen may lead to failure and injury to the inferior alveolar neurovascular bundle. Therefore, this study is aimed to determine the precise position of the mandibular foramen from various anatomical landmarks.

**Methods and Materials:** 50 dry adult mandibles of unknown sex and age were obtained from Department of Anatomy, Regional Institute of Medical Sciences, Imphal, Manipur. Distances from mandibular foramen to 1) Anterior border of ramus 2) Posterior border of ramus 3) Mandibular notch 4) Gonial angle and 5) Mandibular base were measured using a digital vernier calliper to determine the position of the mandibular foramen. Data obtained was statistically analysed.

**Results:** A total of 100 mandibular foramina and 13 accessory mandibular foramina were observed. The mean distance of Mandibular foramen to 1) Anterior border of the ramus is 16.9±1.92 mm (Left side) and 16.77±1.92 mm (Right side) 2) Posterior border of the ramus is 11.21±1.40 mm (Left side) and 11.05±1.24 mm (Right side) 3) Mandibular notch is 23.15±3.65 mm (Left side) and 22.93±3.88 mm (Right side) 4) Gonial angle is 21.8±3.09 mm (Left side) and 21.02±3.43 mm (Right side) 5) Mandibular base is 23.64±3.29 mm (Left side) and 22.96±3.21 mm (Right side).

**Conclusion:** Precise position of the mandibular foramen for successful inferior alveolar neurovascular block is essential for performing various dental surgeries.

**Keywords:** Mandibular foramen, Inferior alveolar nerve, local anaesthesia, neurovascular block, dental surgeries.

Date of Submission: 07-12-2017

Date of acceptance: 16-12-2017

### I. Introduction

The mandibular foramen is an irregular foramen present on the medial surface of the mandibular ramus and is sited midway between the anterior and posterior borders of the ramus about level with the occlusal surfaces of the teeth. Mandibular foramen leads into the mandibular canal through which inferior alveolar nerve and vessels traverses and comes out through the mental foramen as mental vessels and nerve.[1] The inferior alveolar nerve innervates the lower jaw, teeth, periodontal tissues and buccal soft tissues of the premolars and anterior teeth, the skin of the chin and the mucosa of the lower lip.[2] The inferior alveolar nerve block is the most commonly used technique in dentistry and involves the insertion of a needle near the mandibular foramen in order to deposit a solution of local anaesthetic near to the nerve before it enters the foramen. The failure rate of inferior alveolar nerve block has been reported to be 20-25%.[3]

The most frequent technique failure in anaesthesia of the inferior alveolar nerve lies in the inappropriate setting of the needle, due to the inaccurate location of mandibular foramen [4] and presence of accessory mandibular foramina's which indicates the presence of additional branches of inferior alveolar nerves or vessels which is responsible for failure of inferior alveolar nerve block.[5] Furthermore, description of the location of mandibular foramen are described by various author and reveals the importance of mandibular foramen in inferior alveolar nerve block, dentoalveolar surgery like osteotomy, orthonagthic reconstructive surgeries of the mandible, dental implant procedures and anthropometric assessment.[5,6,7,8] Therefore, the

present study has been conducted to investigate the exact location of mandibular foramen and its distances from various bony landmarks on the internal surface of dry mandibular ramus.

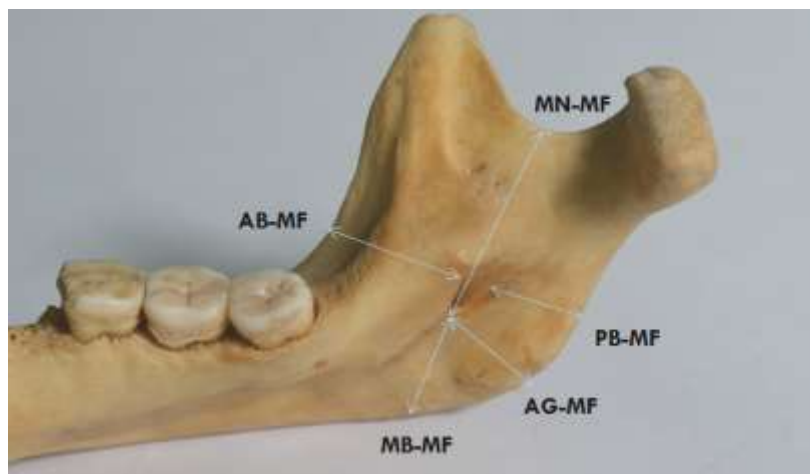
## II. Materials And Method

The study was carried out in the Department of Anatomy, Regional Institute of Medical Sciences, Imphal, Manipur. A total number of 50 dry adult human mandibles consisting of 100 mandibular foramina (50 right and 50 left) of unknown sex and age were collected and studied. Mandibles which are damaged and with abnormalities were excluded from the study. A Digital Vernier Calliper of 0.001mm accuracy was used for taking the measurements. The position of the mandibular foramen was measured from various landmarks as shown in Fig 1.

(Observations were noted using the following legends: MF- Mandibular Foramen; AB – Anterior border of the mandibular ramus; PB – Posterior border of the mandibular ramus; MN – Mandibular Notch of the mandibular ramus; AG – Angle of the mandible; MB – Mandibular Base.)

1. AB – MF - A distance from the centre of the anterior limit of the MF to the nearest point on AB of mandibular ramus.
2. PB – MF - A distance from the centre of the posterior margin of MF to the nearest point on the PB of mandibular ramus.
3. MN – MF - A distance from the lowest point of mandibular notch to the inferior limit of the MF.
4. AG – MF - A distance from the inferior limit of the MF to the angle of the mandible.
5. MB-MF - A distance from the inferior limit of MF to the mandibular base.

Further observations was done for the presence of accessory mandibular foramen. The measurement were taken by two individuals independently and the mean was taken to remove observer's bias. Measurements were recorded to the nearest millimetre. The mean and SD were calculated separately for right and left sides and tabulated.



**Figure 1.** Showing various measurements from different landmarks on the mandible.



**Figure 2.** Showing distance from Mandibular foramen to Anterior border. (MF-AB)



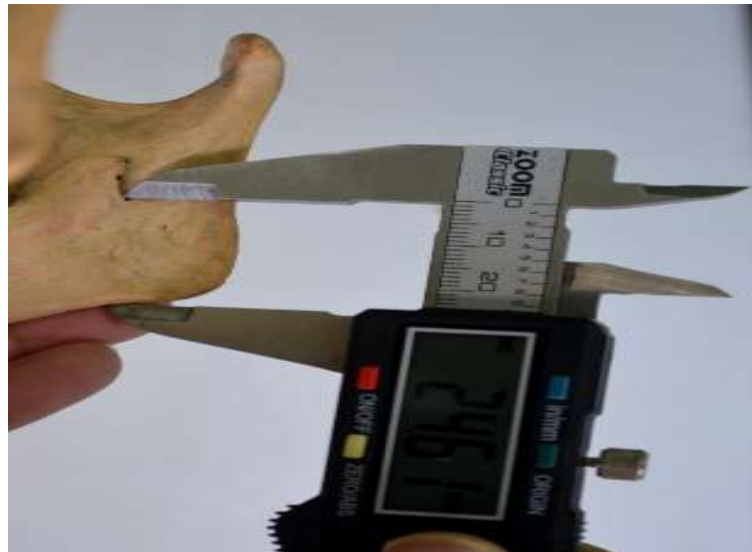**Figure 3.** showing distance from Mandibular foramen to Posterior border. (MF-PB)



**Figure 4.** Showing Distance from Mandibular foramen to Mandibular Notch. (MF- MN)



**Figure 5.** Showing distance from Mandibular foramen to angle of mandible.(MF - AG)



**Figure 6.** Showing distance from Mandibular Foramen to Mandibular Base. (MF - MB)

### III. Results

A total of 100 mandibular foramina (50 right and 50 left) were studied for the position of mandibular foramen from various landmarks. The mean, standard deviation values and P values of various parameters studied are shown in Table 1. The mean distance of Mandibular foramen to Anterior border of mandibular ramus is  $16.9 \pm 1.92$  mm (Left side),  $16.77 \pm 1.92$  mm (Right side), from the Posterior border of the mandibular ramus is  $11.21 \pm 1.40$  mm (Left side),  $11.05 \pm 1.24$  mm (Right side), from the Mandibular notch of the mandibular ramus is  $23.15 \pm 3.65$  mm (Left side),  $22.93 \pm 3.88$  mm (Right side); from the Gonial angle is  $21.8 \pm 3.09$  mm (Left side),  $21.02 \pm 3.43$  mm (Right side); from the Mandibular base is  $23.64 \pm 3.29$  mm (Left side),  $22.96 \pm 3.21$  mm (Right side) respectively.

The study also found that the mandibular foramen is mostly located at the level or below the level of the occlusal plane.

Accessory mandibular foramina (AMF) were present in 13 (26 %) of mandibles. Out of these, in 9 (18 %) of mandibles, AMF were found to be observed bilaterally and in 5 (10%) of mandibles, AMF were observed to be unilateral.

**Table 1.** Measurement Of The Mandibular Foramen (MF) From Various Parameters From The Medial Surface Of The Mandibular Ramus.

Parameters	Side	Mean(mm)	$\pm$ Sd(mm)	P-Value
Ab - Mf	Right	16.77	1.92	0.49 Ns
	Left	16.90	1.92	
Pb - Mf	Right	11.05	1.24	0.30 Ns
	Left	11.21	1.40	
Mn - Mf	Right	22.93	3.88	0.53 Ns
	Left	23.15	3.65	
Ag - Mf	Right	21.02	3.43	0.69 Ns
	Left	21.80	3.09	
Mb - Mf	Right	24.96	3.21	0.28 Ns
	Left	24.64	3.29	

(Following legends have been used where MF- Mandibular Foramen, AB – Anterior border of the mandibular ramus, PB – Posterior border of the mandibular ramus, MN – Mandibular Notch of the mandibular ramus , AG – Angle of the mandible, MB – Mandibular Base.)

### IV. Discussion

The location of the mandibular foramen is essential for achieving inferior alveolar block, dentoalveolar surgery like osteotomy, orthonagthic reconstructive surgeries of the mandible, dental implant procedures and anthropometric assessment.[5,6,7,8,9,10]

In the present study, the position of the mandibular foramen were located by measuring the distances of the Mandibular foramen from various parameters from the mandibular ramus and the findings of this study may be utilized by the dental surgeons in assessing the position of the MF in the local population while using the inferior alveolar block for local anesthesia. This study was compared with other studies done by various authors in India and also study done in other countries to know any geographical difference as shown in Table 2.

Padmavathi G et al[8] studied on mandibles from South Indian population found that the distance of mandibular foramen from various landmarks are  $16.9 \pm 2.5$ mm (R),  $16.8 \pm 2.8$ mm (L) from anterior border;  $12.1 \pm 2.4$ mm (R),  $11.7 \pm 2.0$  (L) from posterior border;  $22.3 \pm 3.4$ mm (R),  $22.0 \pm 3.0$  (L) from mandibular notch;  $22.2 \pm 2.9$ mm (R),  $22.6 \pm 3.4$  (L) from the angle of mandible. This finding was consistent with the findings of the present study.

According to Shenoy V et al[11], in a study on mandibles of Indian population found that the distance of mandibular foramen from various landmarks are  $16.14 \pm 2.0$ mm (R),  $16.34 \pm 1.8$ mm (L) from anterior border;  $11.68 \pm 2.1$ mm (R),  $11.30 \pm 1.9$ mm (L) from posterior border;  $23.58 \pm 3.1$ mm (R),  $23.56 \pm 3.1$ mm (L) from mandibular notch.

According to Oguz O, Bozkir MG[12], in a study of human mandibles of Turkish population found the distance of the mandibular foramen to the anterior border of ramus were 16.9 mm on the right and 16.78 mm on the left. The distance to the posterior side of the ramus was 14.09 mm on the right, and 14.37 mm on the left. The distance of the lowest point of mandibular notch to the foramen was 22.37 mm on the right and 22.17 mm on the left. The distance from the mandibular foramen to the inferior border of the ramus in the mid position of the ramus was 30.97 mm on the right and 29.75 mm on the left.

Ennes J.P et al[13], studied in Brazilian human mandibles and found the distance of the mandibular foramen to the anterior border of the ramus were 14.6 mm on the right and left. The distance to the posterior border of the ramus was 12.1 mm on the right, and 12.3 mm on the left. The distance of the lowest point of mandibular notch to the foramen was 24.3 mm on the right and 24.4 mm on the left. The distance from the mandibular foramen to the inferior border of the ramus was 22.3 mm on the right and on the left.

According to Md Mesbahul Haque et al[14], a study in mandibles of Bangladesh population, found that the distance of mandibular foramen from various landmarks are  $16.34 \pm 1.9$ mm (R),  $16.27 \pm 1.9$ mm (L) from anterior border;  $14.1 \pm 2.3$ mm (R),  $14.04 \pm 2.3$ mm (L) from posterior border;  $22.29 \pm 3.4$ mm (R),  $22.18 \pm 3.3$ mm (L) from mandibular notch.

According to Kilarkaje et al[15], a study in mandibles of Kuwait population, found that the distance of mandibular foramen from various landmarks are  $18.5 \pm 1.9$ mm (R),  $18.5 \pm 2.6$ mm (L) from anterior border;  $21.6 \pm 3.1$ mm (R),  $21.6 \pm 3.4$ mm (L) from mandibular notch;  $25.1 \pm 4.2$ mm (R),  $24.7 \pm 4.4$ mm (L) from gonial angle.

According to Thangavelu K et al[7], the mandibular foramen was always located at the level of the occlusal plane or below the occlusal plane which is similar to the findings of this present study, however, according to Nicholson ML[19], the mandibular foramen was predominantly located at the center of the mandibular ramus. Thangavelu K et al[7] also stated that in the IANB (inferior alveolar nerve block) technique, insertion of needle 10mm above the occlusal plane (posterior to anterior border in the medial side of ramus) and deposition of anaesthetic solution at a distance of 19mm from the anterior border should anaesthetize the inferior alveolar nerve. Therefore, when a patient opens the mouth, the inferior alveolar nerve moves a few mm posteriorly, therefore, 23 mm (19mm plus 4mm) distance of needle insertion inside the tissues from the anterior border of ramus would take the needle tip nearer to the alveolar nerve.

According to the results of this present study, it was concluded that the right and left mandibular rami presented symmetry in the location of the mandibular foramen which is similar to the findings of Padmavathi et al[8] and Ennes JP et al[13], however, according to Nicholson ML[16] and Hetson et al[17], there is variability of the mandibular foramen of the two mandibular rami in the same person. Significant differences in the location of Mandibular foramen has been reported in different ethnic groups, which could be due to differences in the age, sex, population and methodologies used in the studies conducted by various authors.[8,18] Therefore, the variability of the position of the mandibular foramen makes it difficult to anaesthetize the inferior alveolar nerve.[19]

The presence of accessory mandibular foramen could be associated with additional branches of inferior alveolar nerve which may be a cause for the failure of inferior alveolar nerve block. Branch arising from inferior alveolar nerve proximal to the mandibular foramen or in the infratemporal fossa will transmit through this foramen to supply the 3rd molar teeth. Hence it will escape local anesthesia and result with inadequate or failure to achieve nerve block. Also accessory mandibular foramina may provide a route for the spread of infections and tumor following radiotherapy.[19] Our present study is mainly concentrated on identifying the specific location of the mandibular foramen by measuring the mean distances of the mandibular foramen from various bony landmarks on the mandible. It was found that the location of the mandibular foramen maintains bilateral symmetry of both sides of the ramus.

Parameter	Side	Padmavati G et al[8] (South Indian)	Oguz et al[12] (Turkish)	Ennes JP, Medeiros RM[13] (Brazil)	Md Masbahul Haque et al[14] Bangladesh	Shenoy V et al [11] Indian population	Prajna Paramita et al[18] Indian population	Kilarkaje et al[15] (Kuwait)	Present study Indian population
AB - MF	R	16.8±2.8	16.9	14.6±2.9	16.34±1.9	16.14±2.0	15.72±2.9	18.5±1.9	16.7±1.9
	L	16.9±2.5	16.78	14.6±3.2	16.27±1.9	16.34±1.8	16.23±2.8	18.5±2.0	16.9±1.9
PB - MF	R	12.1±2.4	14.09	12.1±2.3	14.14±2.3	11.68±2.1	13.29±1.7	-	11.2±1.4
	L	12.1±2.4	14.37	12.3±2.3	14.04±2.3	11.30±1.9	12.73±2.0	-	11.2±1.4
MN - MF	R	22.0±3.0	22.37	24.3±3.3	22.29±3.4	23.58±3.1	22.7±3.0	21.6±3.1	22.9±3.8
	L	22.3±3.4	22.17	24.4±3.6	22.18±3.3	23.56±3.1	21.2±2.9	21.6±3.4	23.1±3.6
AG - MF	R	22.6±3.4	-	-	-	-	21.5±2.9	25.1±4.2	21.0±3.4
	L	22.2±2.9	-	-	-	-	21.13±3.4	24.7±4.4	21.1±3.0
MB - MF	R	25.0±3.2	-	22.3±4.8	-	-	-	-	24.9±3.2
	L	24.8±3.8	-	22.4±5.1	-	-	-	-	24.6±3.2

**Table 2.** Showing the comparison of the findings of different authors with the present study.

### V. Conclusion

In the present study, the mean distance of Mandibular foramen to :- 1) Anterior border of ramus is 16.9±1.92mm (Left side), 16.77±1.92mm(Right side), 2) Posterior border of ramus is 11.21±1.40mm (Left side), 11.05±1.24mm(Right side), 3) Mandibular notch is 23.15±3.65mm (Left side), 22.93±3.88mm (Right side), 4) Gonial angle is 21.80±3.09mm (Left side), 21.02±3.43mm (Right side),5) Mandibular base is 23.64±3.29mm (Left side), 22.96±3.21mm (Right side). The position of mandibular foramen was mostly found at the level of the occlusal plane or below the level of the occlusal plane. Also, the position of the mandibular foramen was at same distance from each anatomical landmark on both sides demonstrating bilateral symmetry. The present study also observed the presence of Accessory Mandibular Foramina (AMF) in 13 (26%) mandibles.

Owing to variability in the position of MF, it is essential to have a thorough knowledge of the precise location of MF to determine the accurate site of local anaesthesia prior to dental surgeries on lower jaw. Therefore, in inferior alveolar nerve block technique, insertion of needle about 10mm above the level of occlusal plane [7] and deposition of anaesthetic solution at a distance of 20.77mm on the right ramus (mean 16.77 mm + 4 mm for posterior movement of inferior alveolar nerve in open position of mandible) and 20.90 mm on the left ramus (mean 16.90 mm + 4 mm for posterior movement of inferior alveolar nerve in open position of mandible ) from the anterior border of the mandibular ramus would anaesthetize the inferior alveolar nerve. The dental surgeons can utilize this information during the local anesthesia involving the inferior alveolar nerve (IAN) for different procedures such as dental extraction, placement of mandibular implants, and other therapeutic procedures involving mandibles. Also awareness of the presence of accessory mandibular foramen is important as it may lead to the failure of inferior alveolar nerve block and may serve as an alternate route for spread of tumor cells.[7,8,9,10]

Therefore, the present study concludes that the precise position of MF is essential to dental surgeons, oro- maxillofacial surgeons for performing successful dental surgeries (IAN block, reconstructive surgeries etc) and also helps prevent damage to the neurovascular bundles.

### References

- [1]. Beale TJ, Robinson PD. Infratemporal and pterygopalatine fossa and temporomandibular joint. In: Stranding S, Borley NR, Healy JC, Collins P, Johnson D, Crossman AR, et al eds. Gray's Anatomy: The anatomical basis of clinical practice. 40th ed. UK: Elsevier Churchill Livingstone 2016. 534-555.
- [2]. Apostolos N, Elaides, Kalliopi H, Manta, Anastasios T, Tsiirlis. Neurovascular content of the mandibular canal and its clinical relevance: A literature review of the Related Anatomical and Radiological studies. Balk J Dent Med, 2014; 18: 124-132.
- [3]. Hesham Khalil. A basic review on the inferior alveolar nerve block techniques. Anaes Essays Res, 2014; 8(1): 3-8.
- [4]. Hetzon G, Share J, Frommer J, Kronman JH. Statistical evaluation of the position of the mandibular foramen. Oral Surg. Oral Med. Oral Pathol, 1988; 65(1): 4-32.
- [5]. Qudesia Sultana, Shariff M.H, Ramakrishnan Avadhani. Study of surgical landmarks of mandibular foramen for inferior alveolar nerve block: An osteological study. Indian Journal of Clinical Anatomy and Physiology. 2016; 3(1): 37-40.
- [6]. Lalitha B, Sridevi NS, Rao EKV. Morphometric Analysis of mandibular foramen in adult human mandibles. International Journal of Scientific study. July 2016; 4(4): 20-23.
- [7]. Thangavelu K, Kannan R, Kumar NS, Rethish E, Sabitha S, Sayee Ganesh N. Significance of localization of mandibular foramen in an inferior alveolar nerve block. Journal of Natural Science, Biology, and Medicine. 2012; 3(2):156-160.
- [8]. Padmavathi G, Suman T, Varalakshmi KL, Roopashree R. An anatomical study of mandibular and accessory mandibular foramen in dry adult human mandibles of south indian origin. IOSR J Dent Med Sci 2014; 13:83-8.
- [9]. Reitzik, M.; Griffiths, R. R. & Mirels, H. Surgical anatomy of the ascending ramus of the mandible. Br. J. Oral Surg., 14:150-5, 1976.
- [10]. Kaffe, I.; Ardekian, L.; Gelerenter, I. & Taicher, S. Location of the mandibular foramen in panoramic radiographs. Oral Surg. Oral Med. Oral Pathol., 78:662-9, 1994
- [11]. Shenoy V, Vijayalakshmi S, Saraswathi P. Osteometric analysis of the mandibular foramen in dry human mandibles. Journal of clinical and Diagnostic Research 2012;6:557-560.

- [12]. Oguz O, Bozkir MG. Evaluation of the location of the mandibular and mental foramina in dry, young, adult human male, dentulous mandibles. *West Indian Med. J* 2002;51(1):6-14.
- [13]. Ennes, J. P. & Medeiros, R. M. Localization of mandibular foramen and clinical implications. *Int. J. Morphol.*,27(4):1305-11, 2009.
- [14]. Hoque MM, Ara S, Begum S, Kamal M AHM, Momen AM. Study of Morphometric Analysis of Mandibular Foramen in Bangladeshi Dry Adult Human Mandible. *Bangladesh J. Anat.*2013;11(2):58-61.
- [15]. Kilarakaje N, Nayak SR, Narayan P, Prabhu LV. The location of the mandibular foramen maintains absolute bilateral symmetry in mandibles of different age-groups. *Hong Kong Dental Journal* 2005;2:35-37.
- [16]. Nicholson ML. A study of the position of the mandibular foramen in the adult human mandible. *Anat Rec* 1985;212(1): 110-12.
- [17]. Hetson, G.; Share, J.; Frommer, J. & Kronman, J. H. Statistical evaluation of the position of the mandibular foramen. *Surg.Oral Med. Oral Pathol.*, 65:32-4, 1988.
- [18]. Prajna Paramitha S, Poonam K. Morphometric analysis of mandibular foramina and incidence of accessory mandibular foramina in adult human mandibles of an Indian population. *Rev Arg de Anat Clin* 2013;5(2):60-66.
- [19]. Gopalakrishna K, Deepalaxmi S, Somashekara S.C, Rathna B.S. An anatomical study on the position of mandibular foramen in 100 dry mandibles. *Int J Anat Res* 2016, 4(1):1967-71.

Rajkumari K. "A Morphometric Study of the Mandibular Foramen in Dry Adult Human Mandibles - A Study in RIMS, Imphal." *IOSR Journal of Dental and Medical Sciences (IOSR-JDMS)* 16.12 (2017): 39-45