

## A Rare Case of Hemifacial Hypertrophy- Orthodontic Perspective

Dr.Falguni Mehta<sup>1</sup>, Dr.Renuka Patel<sup>2</sup>, Krutarth Trivedi<sup>3</sup>,  
Hardik Suvagiya<sup>4</sup>, Nisarg Yagnik<sup>5</sup>

<sup>1</sup>(Prof. And HOD, Dept Of Orthodontics And Dentofacial Orthopaedics, GDCH, Ahmedabad, India)

<sup>2</sup>(Assistant Prof., Dept Of Orthodontics And Dentofacial Orthopaedics, GDCH, Ahmedabad, India)

<sup>3</sup>(Postgraduate Student, Dept Of Orthodontics And Dentofacial Orthopaedics, GDCH, Ahmedabad, India)

<sup>4</sup>(Postgraduate Student, Dept Of Orthodontics And Dentofacial Orthopaedics, GDCH, Ahmedabad, India)

<sup>5</sup>(Postgraduate Student, Dept Of Orthodontics And Dentofacial Orthopaedics, GDCH, Ahmedabad, India)

**Abstract:** Hemifacial hypertrophy is a rare congenital malformation characterized by unilateral excess development of hard and soft tissues of the face. Hemifacial Hypertrophy (HFH) is usually evident at birth and accentuates during puberty. It stabilizes once growth ceases. Asymmetry is a law of nature but when it exceeds a certain limit it is disfiguring to facial aesthetic. Hemihypertrophy is one such condition where there is marked asymmetry of entire half of body or face which causes marked facial deformity which leaves a major impact on child's psychology. There are very few cases reported in the literature.

**Keywords:** Asymmetry, Hypertrophy

### I. Introduction

Congenital hemihypertrophy is a rare developmental disorder characterized by unilateral overgrowth of one or more body parts resulting in marked asymmetry. Rowe[1] in 1962 classified hemihypertrophy of three types. :

1. complex hemihypertrophy involving the entire half of the body,
2. simple hemihypertrophy affecting one or both limbs, and
3. hemifacial hypertrophy (HFH) affecting the teeth and bones of the face including soft tissues of the face.

Although definite aetiology of HFH is not known, it is frequently associated with other conditions, such as acromegaly and pituitary gigantism, or with hypertrophy of other parts of the body. Many theories have been proposed as a cause for HFH like chromosomal aberration, hormonal imbalance, diseases involving the neural system, vascular conditions such as hemangiomas, lymphatic abnormalities such as lymphangioma, abnormal intrauterine environment, somatic mutations, mechanical influences and congenital syphilis. A grossly perceptible asymmetry of the face as seen in hemifacial hypertrophy can be highly disconcerting to the patient. The treatment of this condition is unpredictable with an uncertain prognosis and remote chances of patient satisfaction. But, the asymmetry usually remains constant after the end of adolescence, and as the skeletal maturation occurs the condition tends to stabilize. This report describes a rare case of congenital Hemifacial hypertrophy of a 12 year old female child, its clinical features, radiographic and cbct findings and different treatment options.

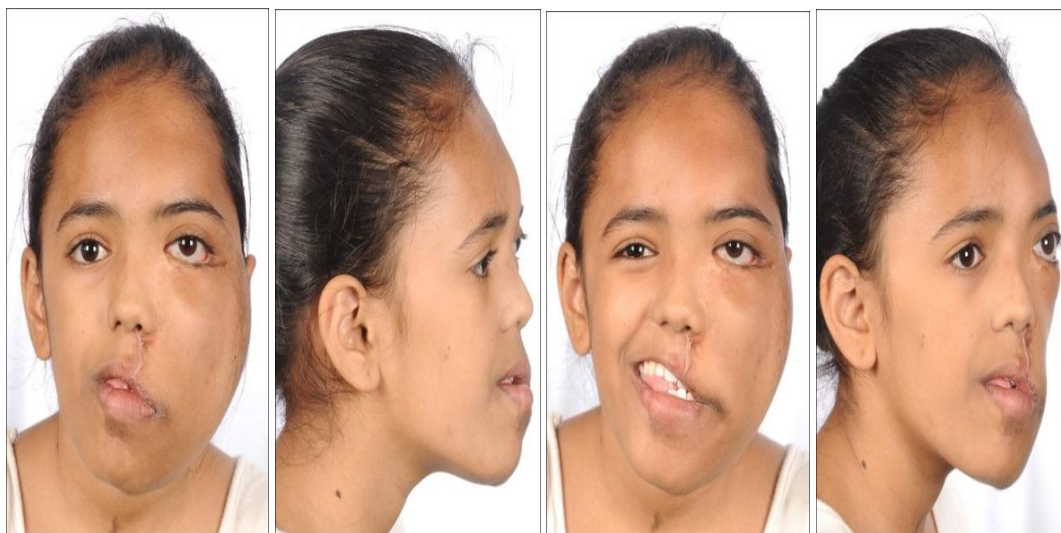### II. Case Report

A 12 year female child presented to the Department of Orthodontics, GDCH, Ahmedabad with the chief complaint of painless swelling on the left side of face since birth. She presented with anterior open bite which led to difficulty in chewing. The swelling had increased in size with age causing gross facial asymmetry. The child was the second of two siblings born by normal delivery. The older sibling has a history of paralysis of both legs since birth. The patient had swelling on left side for which she was operated twice, once at 8 years and then at 11 years for debulking of the left side; where lymphomatous tissue was excised. General examination of the patient showed normal gait, well built, adequately nourished with all the vital signs within normal limits.

Extra-oral examination [Fig.1] :

- Asymmetry of the left side of face over the cheek region
- The swelling extended antero-posteriorly from midline to the left pre-auricular region and supero-inferiorly from the supra-orbital ridge to the inferior border of mandible
- Brownish macules were noted on the left side of face suggestive of café-au-lait spots
- Proptosis was seen on the left side
- Nose, parotid gland and TMJ showed enlargement on the left side
- The left half of the lower lip was hypertrophied, with the mouth tilted downwards.
- Post-surgical scar was present on the pre tragus area on the left side and on the philtrum.

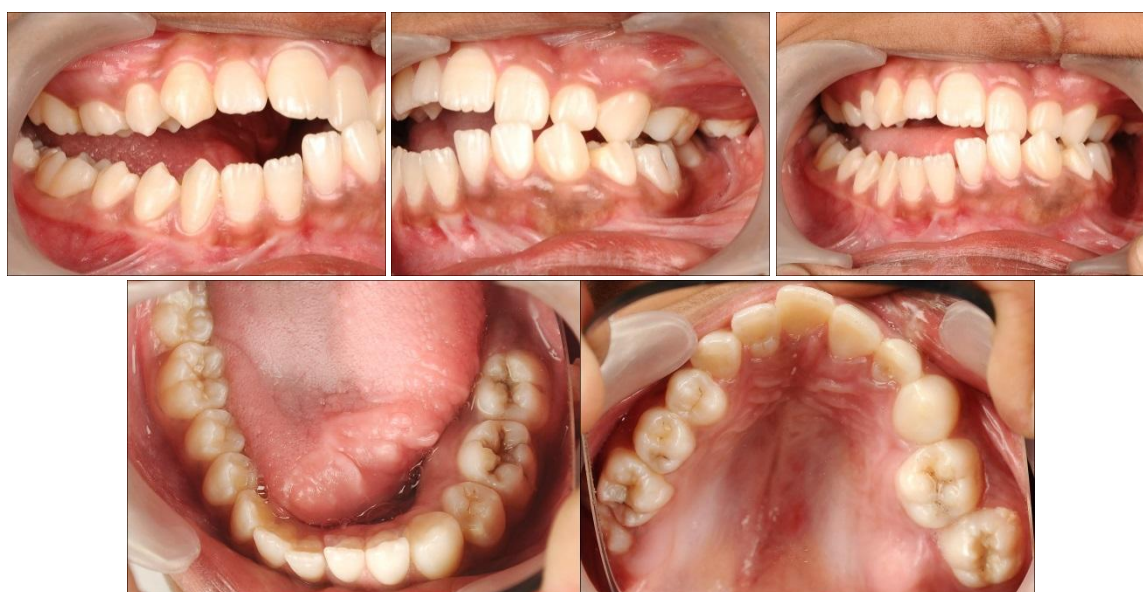- On palpation, the swelling was bony-hard in consistency, non-compressible and non-reducible.
- Muscles of mastication were non-tender and no lymph nodes were enlarged.



**Figure1:** Extra-oral photographs

Intra-oral examination [Fig.2]:

- Multiple papules were present on the left buccal mucosa.
- Palate was enlarged on the left side.
- Left half of the tongue was also enlarged with multiple papules.
- Left upper and lower alveolus showed hyperplasia.
- Macrodontia was seen in upper left quadrant (involving 22, 23, 26, 27) with the absence of premolars.
- Macrodontia was also seen involving all teeth in the lower left quadrant with absent second premolar.
- Upper midline shift was evident towards the left side.
- Cross-bite seen in 21,22,23 and 26 with 27 in Buccal non occlusion.
- Class III molar relation was seen on the left side
- Open bite on the right side.

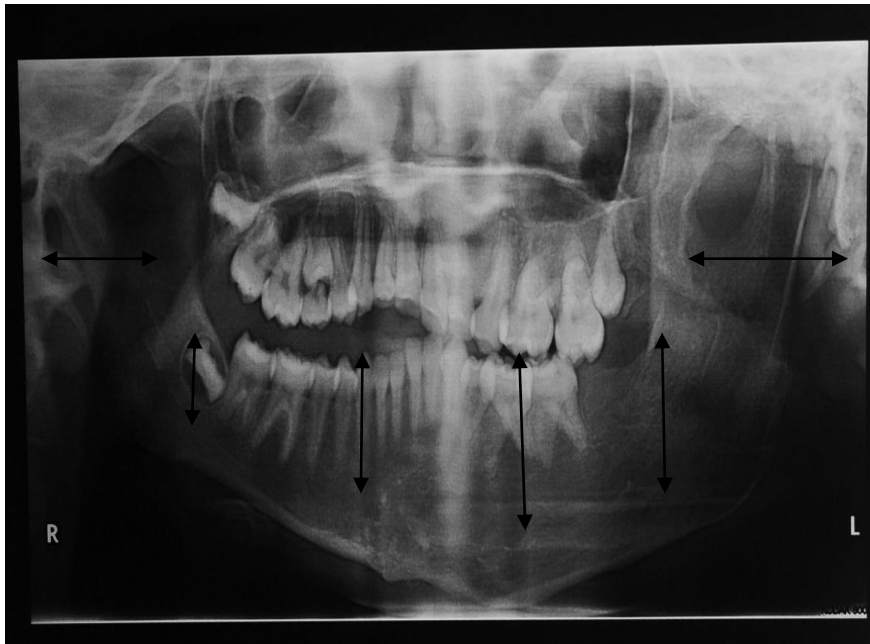


**Figure2:** Intra-oral photographs

Orthopantomogram findings [Fig.3]:

- Marked enlargement of teeth and their roots on left side.
- Absence of 24, 25, and 34.

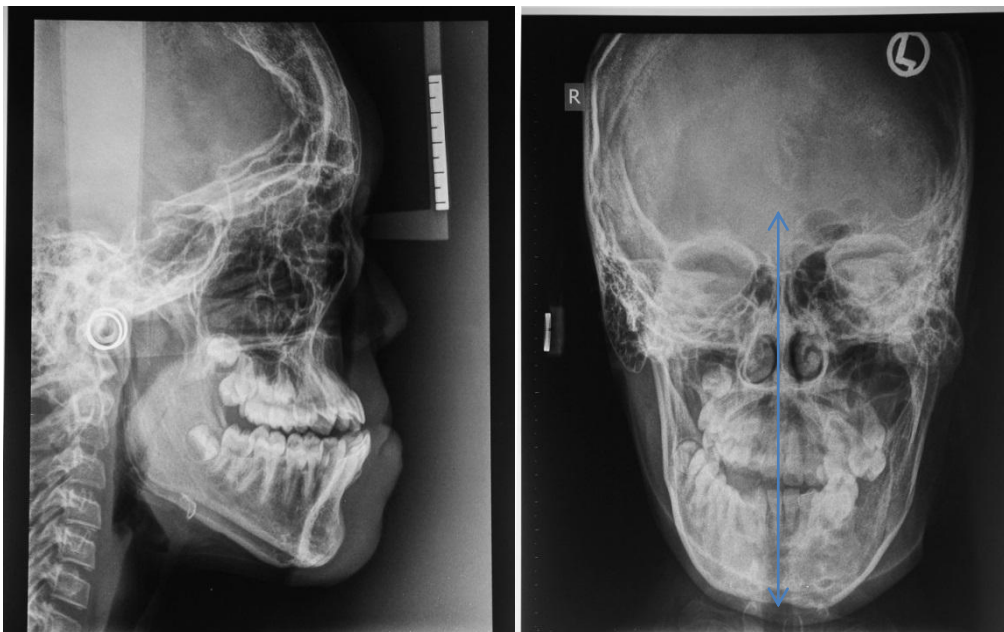
- Presence of 55 clinically with 15 present radiographically.
- Marked mandibular enlargement seen involving the condylar, coronoid processes, ramus as well as the body of the mandible.



**Figure3:** Orthopantomogram

Posteroanterior View Of Skull findings [Fig.4]:

- Enlarged frontal sinus and Maxillary sinus on left
- Enlarged teeth on left side
- Enlarged Maxillary and Mandibular dimensions on left
- Maxillary Midline shift towards left



**Figure4:** Lateral and Postero-Anterior cephalogram

CBCT findings [Fig.5,6]:

To better define the facial deformity, a CBCT scan was performed which showed enlarged maxilla and mandible on left including palatal shelf bone. An enlarged maxillary sinus, frontal sinus and the mandibular canal including teeth were seen on left side.

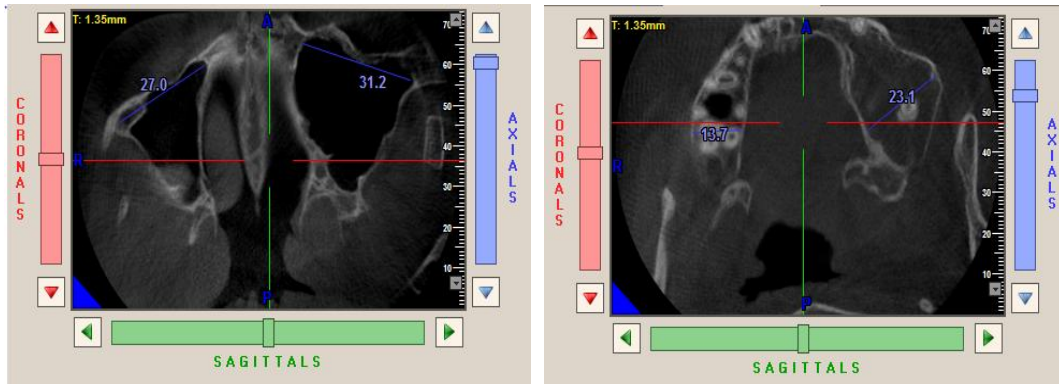


Figure5: CBCT of the maxillary sinus and at the sinus level of maxilla

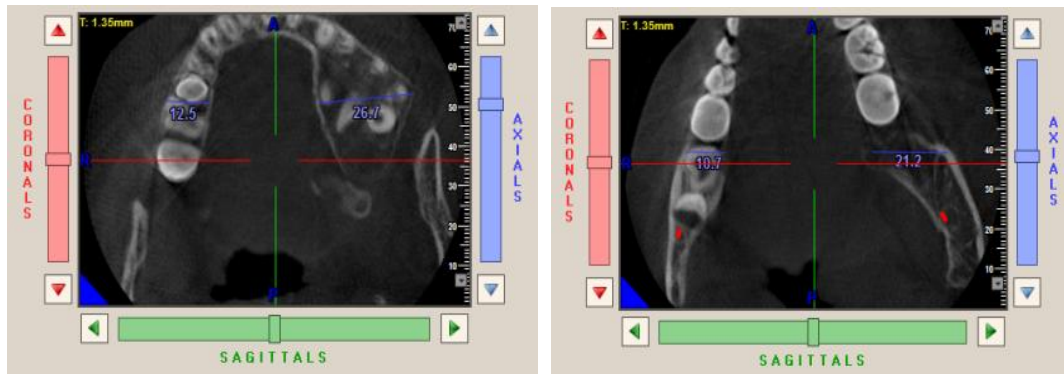


Figure6: CBCT of maxilla and mandible at cervical levels

Table1: Comparison of bone dimensions of right and left side on cbct

|                 |                | Right  | Left   |
|-----------------|----------------|--------|--------|
| Maxillary sinus | Anterior wall  | 27.0mm | 31.2mm |
| Maxilla         | Sinus level    | 13.7mm | 23.1mm |
|                 | Cervical level | 12.5mm | 26.7mm |
| Mandible        | Cervical level | 10.7mm | 21.2mm |

Provisional diagnosis: Benign neurofibromatosis with manifestation of hemifacial hypertrophy.

### III. Discussion

Hemifacial hypertrophy (HFH) was first reported by Friedreich in 1863[3].The prevalence rate of HFH is 1:86000 live births[4]. This condition worsens with age, especially around puberty and stabilizes after growth completion. The disorder occurs more commonly in females as compared to males with ratio of 3:2. Right side of the face is more commonly affected[5] than the left.

Rowe describes abnormalities in the dentition of the abnormal side in three respects; the crown size, the root size and shape, and rate of development[6,7]. He observes that not all teeth are similarly affected. In the deciduous dentition, the second molar and in the permanent dentition the cuspids are the most commonly affected teeth followed by the first molars and premolars[7,8]. This enlargement, however, does not exceed 50% over their normal counterpart[8]. Early shedding of deciduous teeth, delayed eruption of permanent teeth, prematurely developed teeth with short roots and congenitally missing teeth are often seen on the affected side. The alveolar bone is larger and thicker on the affected side with the largest bulk distal to the largest tooth. There is also a propensity for an open bite as both posterior ridges develops exostoses which contact each other during jaw closure. Radiographically, the mandibular canal may also be increased in size[9]. The tongue enlargement has also been described to be uniform with multiple papules.

In the present case, the buccal mucosa on the affected side showed lipomatous growths; the tongue, lip, and palate were uniformly enlarged; the teeth appeared to be abnormal in size.

Hemifacial hypertrophy tends to worsen during pubertal growth spurt so active treatment carried out during this period tends to relapse as bone and alveolar process are growing at rapid rate. So treatment is planned once growth ceases completely.

The occlusal deformities should be corrected by orthodontic therapy but increased thickness and increased density of cortical bone makes it very difficult to correct the malocclusion increasing chances of root resorption. Thus for correction of dental deformity along with underlying skeletal problem, Orthognathic



surgeries are best choice of treatment. During osteotomy one should preserve the mandibular canal which is enlarged .Bone which has been cut can be transplanted on the unaffected side[10] or tissue fillers [11] can be used to improve facial symmetry after surgery for facial reconstruction.

The treatment modalities extend from subtle soft tissue contouring to extensive surgeries to correct the underlying bony defect and reshape the overlying soft tissues. The surgical treatment includes Orthognathic Surgeries and Osteotomies. The hard tissues can be treated by a combination of Condylar recontouring and Osteotomies of the Maxilla and Mandibular body as well as ramus to achieve the required shape, followed by Debulking of soft tissues, Rhytidectomy, and Cheiloplasty.

#### **IV. Conclusion**

Sometimes painless lesion becomes painful for life if it leads to gross facial asymmetry. Hemifacial hypertrophy is a developmental disorder in which one side of face appear larger than other. Not only soft tissue, underlying bone also shows growth discrepancy and appears larger than its normal counterpart. It has not only marked impact on patient's facial esthetics but also on their psychology .Treatment should be carried out once growth has ceased completely .Treatment of choice would be Orthognathic surgery, Osteotomies, Soft tissue debulking along with psychological counselling.

#### **References**

- [1] Rowe NH. Hemifacial hypertrophy--review of the literature and addition of four cases. *Oral Surg Oral Med Oral Pathol* 1962;15:572-87.
- [2] Siponen M, S ndor G, Ylikontiola L, Salo T, Tuominen H. Multiple orofacial intraneural perineuromas in a patient with hemifacial hyperplasia. *Oral Surg Oral Med Oral Pathol Oral Radiol Endod* 2007; 104(1):38-44.
- [3] N.Friedreich, "Ueber congenitale halbseitige Kopfhypertrophie,," *Archiv f rPathologischeAnatomie undPhysiologie undf ur Klinische Medicin*, vol. 28, no. 5-6, pp. 474-481, 1863.
- [4] R. E. Marx and D. Stern. *Oral and Maxillofacial Pathology: A Rationale for Diagnosis and Treatment* (Quintessence, Chicago, Ill, usa, 1st edition, 2003)
- [5] Rudolph CE, Norvold R W. Congenital paltial hemihypertrophy involving marked malocclusion. *Dent Res* 1944;23: 133.
- [6] Khanna JN, Andrade NN. Hemifacial hypertrophy. Report of two cases. *Int J Oral Maxillofac Surg* 1989 Oct;18(5):294-297.
- [7] R Nayak, MS Baliga, Crossed hemifacial hyperplasia: A diagnostic dilemma, *J Indian Soc Pedod Prev Dent* 2007 Vol 25 Issue : 1 Page : 39-42
- [8] Lawoyin JO , Daramola JO, Lawoyin DO. Congenital Hemifacial hypertrophy: Report of two cases. *Oral Surg Oral Med Oral Pathol* 1989;68:27-30
- [9] Verma P, Gupta K, Rishi S, Triwedi A. Hemifacial hypertrophy: A rare case report. *Med Radiol* 2012;24:338- 41
- [10] Richard Pollock . Congenital hemifacial hyperplasia: an embryologic hypothesis and case report. *cleft palate journal* july 1985 vol 2 no 3.
- [11] Mutaz B. Habal .Computer-Assisted Planning and Navigation for the Treatment of True Hemifacial Hyperplasia. *The Journal of Craniofacial Surgery* , Volume 26, Number 2, **March 2011**