

## Treatment of Intra and Extra Articular Pilon Fracture of Distal Tibia By Distraction Method: Functional Outcome

Dr Soudip Sinha<sup>1</sup> \*Dr Apurba Gorain<sup>2</sup> Dr Soumya Ghosh<sup>3</sup>  
Dr Pradip Kumar Ghosh<sup>4</sup> Dr Sourav Chatterjee<sup>5</sup>

<sup>1</sup>Department of Orthopaedics, Burdwan Medical College and Hospital, West Bengal University Of Health Sciences, India

<sup>2</sup> Department Of Orthopaedics, Burdwan Medical College and Hospital, West Bengal University Of Health Sciences, India

<sup>3</sup>Department Of Orthopaedics, Burdwan Medical College and Hospital, West Bengal University Of Health Sciences, India

<sup>4</sup>Department Of Orthopaedics, Burdwan Medical College and Hospital, West Bengal University Of Health Sciences, India

<sup>5</sup>Department Of Orthopaedics, Burdwan Medical College and Hospital, West Bengal University Of Health Sciences, India

\*Corresponding author Dr Apurba Gorain

### Abstract

**Background:** Surgical management of tibialpilon fractures have always posed a challenge to orthopaedic surgeons due the high incidence of complications in the conventional surgical options.

**Aims:** The aim of this study is to observe the surgical outcome of distal tibialpilon fractures treated according to the concept of combined external fixation and limited internal fixation.

**Materials And Methods:** This pilot study was conducted in a tertiary care centre of eastern India with institutional ethical clearance and informed consent of the subjects. Twenty patients were treated and they were followed up after operative management in the institution for 12 months.

**Results:** A total of 20 patients with an average age of 39.25 years, were treated, out of which, extra articular (AO type A) were 8 in number, accounting for 40% of the sample size. Partially articular (AO Type B) were 5 in number accounting for 25%. The remaining 7 were of the Intra articular variety (AO Type C) making up 35%. 7 cases were treated with percutaneous screws and External fixation (35%). 5 were treated with fibular plating and external fixation accounting for 25% of the cases. For the remaining 8 cases (40%) only External fixation was done. The patients were followed up over a period of 12 months and at the end of this period the outcome was studied. 3 patients presented with malunion of the varus type (15%). Infection at operative wound site was reported in 2 cases (10%), while one case was reported for pin tract infection (5%). Post operative osteoarthritis of the ankle joint was looked for at the end of the 12 months of follow up and it was found that 5 cases presented with its features (25%). The functional outcome of the patients was measured using the Maryland Foot score. 5 of the patients had a "good" score while the remaining 15 had "excellent" scores.

**Conclusion:** It was observed that following the principle of combined external fixation and limited internal fixation, although the rate of malunion was higher, yet the overall outcome was excellent with lesser soft tissue complications.

Date of Submission: 08-01-2018

Date of acceptance: 25-01-2018

### I. Introduction

The treatment of fractures of the distal part of the lower leg is challenging for orthopaedic surgeons and often leads to serious complications such as infection, malunion, nonunion and post-traumatic arthritis. The published results are often difficult to compare because of significant heterogeneity of bone and soft-tissue injuries, the small number of patients in reported series, the retrospective nature of many investigations and the absence of a control group in most studies. Fractures of the distal tibial metaphysis, with extension into the articular region, or pilon fractures, are commonly due to vertical compression trauma, or, more rarely, to torsional forces which result in a spiral fracture of the distal tibia with extension into the ankle joint. The recommended surgical treatment for these fractures has for many years been open reduction coupled with rigid internal fixation with plates and screws. There is, however, a high incidence of complications associated with this method of treatment, and reports of wound breakdown, superficial and deep infection and osteomyelitis are common.

Recently, several authors have reported decreased complication rates in severe pilon fractures using external fixation. In response to reports of unacceptable results with plating, of high energy tibial pilon fractures with traditional technique, external fixation combined with limited internal fixation of fibula and articular surface of tibia has been advocated as alternative approach. Delayed union in fractures with severe metaphyseal comminution, and varus malunions are also noticeable in many literature. Fibular fixation is proved to decrease these complications. Delayed second staged bone grafting for severe metaphyseal comminution is also efficacious.

## II. Classification

According to the AO/OTA classification the term ‘distal tibial fracture’ includes a heterogeneous group of fractures that involve the distal part of both tibia and fibula. The term ‘pilon fracture’ was originally introduced by Etienne Destot and indicates the involvement of the weight-bearing surface of the ankle joint which usually results from an axially directed force.

AO/OTA classification used:

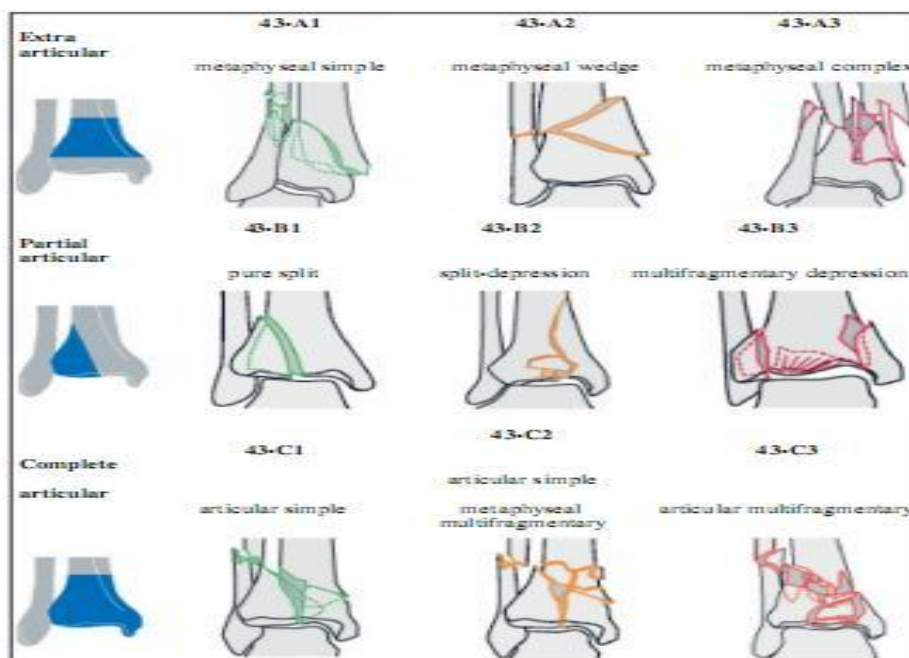


Figure 1. AO classification system, type 43 – distal tibial fractures.

## II. Materials And Methods

We have treated 20 patients with distal tibia fracture according to the concept of combined external fixation and limited internal fixation. For external fixation we have used half pin fixator, mostly spanning fixator to span the ankle joint. Different constructs were used. Limited internal fixation was done for fibula. We have used plating for distal fibula. Open fractures and fractures with poor skin condition were excluded from the study. We opted for distraction as early as possible. AO external fixator in form of half pins and rods used in most cases. For fibular plating 3.5 mm DCP, 1/3 tubular plates and recon plates were used. We have opted this treatment for all types of fractures including AO/OTA A3, B3, C3. Second stage bone grafting for fracture type A3, B3, and C3 was done routinely. Post operative removal of fixator was done after union was achieved. Follow up for clinical outcome was done at 1 month, 2 month, 6 months and after 1 year. 100% radiographs were used for post operative displacement assessment. More than 2 mm displacement at articular surface have been classified as poor reduction. Maryland foot score was assessed at 1 year follow up.

## III. Results

A total of 20 patients with an average age of 39.25 years, were treated, out of which, extra articular (AO type A) were 8 in number, accounting for 40% of the sample size. Partially articular (AO Type B) were 5 in number accounting for 25%. The remaining 7 were of the Intra articular variety (AO Type C) making up 35%. Various modalities of treatment were chosen for the cases depending on the fracture patterns after discussion between the authors. 7 cases were treated with percutaneous screws and External fixation (35%). 5 were treated with fibular plating and external fixation accounting for 25% of the cases. For the remaining 8

cases (40%) only External fixation was done. The patients were followed up over a period of 12 months and at the end of this period the outcome was studied. 3 patients presented with malunion of the varus type (15%). Infection at operative wound site was reported in 2 cases (10%), while one case was reported for pin tract infection (5%). Post operative osteoarthritis of the ankle joint was looked for at the end of the 12 months of follow up and it was found that 5 cases presented with its features (25%). The functional outcome of the patients was measured using the Maryland Foot score. 5 of the patients had a "good" score while the remaining 15 had "excellent" scores.

#### IV. Discussion

The purpose of this article is to study the outcome of surgical treatment of distal tibia fracture according to the concept of combined external fixation and limited internal fixation. A study by Weiner, Bergman et al in 1993 prospectively evaluated the use of limited internal fixation and the application of a hybrid external fixator in the treatment of severe pilon fractures and concluded that soft tissue complications were infrequent and early motion and fracture stability maintained. Pugh, Wolinsky et al published a retrospective review in 1999 of surgically treated pilon fractures and concluded that although malunion continues to be a problem with external fixation as a treatment modality yet it offers an advantage in soft tissue associated with pilon fractures. Marsh, Lawrence et al, in 1995 concluded that early complications related to severe pilon fractures and their treatment can be reduced with an external fixator combined with limited internal fixation.

#### V. Conclusion

The operative procedures performed on the 20 cases have less soft tissue complications like infection. Although rate of malunion was comparatively higher, the functional outcome of the cases were mostly excellent. Rate of osteoarthritis did not majorly affect the overall functional outcome of the cases. No cases of heterotopic ossification were reported. When the patients were screened for stiffness at 3 months, the prevalence for the same was found to be increased. However after the follow up period of 12 months, this rate was found to have come down resulting from effective physiotherapy and passage of time. It was observed that following the principle of combined external fixation and limited internal fixation, although the rate of malunion was higher, yet the overall outcome was excellent with lesser soft tissue complications.

#### VI. Acknowledgements

It is my privilege to have this opportunity to make this study under the auspices of the institution Burdwan Medical College and Hospital, Burdwan. One of my dreams has been fulfilled.

With great honour and due respect, I wish to express my gratitude to Professor Dr **Sukumar Basak, Principal, burdwan medical college, burdwan**, for kindly allowing to conduct the present study in this institution.

I record my sincere appreciation and gratitude and help extended by **Prof (Dr) Chinmay De, professor and head department of orthopaedics, burdwan medical college, burdwan**.

I wish to express my gratitude to **Dr soumya Ghosh, associate professor, department of orthopaedics, burdwan medical college** for his guidance, and **Dr Pradip Kumar Ghosh, associate professor BMCH**, for his continuous support and **Dr Sourav Chatterjee** for helping the work to progress.

#### References

- [1]. Matthew I. Rudloff. Tibial pilon fractures, Fractures Of The Lower Extremity, Campbells Operative Orthopaedics 13e 2017.
- [2]. David P. Barei. Pilon Fractures, Rockwood and Green's Fractures in adults, 8e
- [3]. Pugh, Kevin J. MD; Wolinsky, Philip R. MD; McAndrew, Mark P. MD; Johnson, Kenneth D. MD. Tibial Pilon Fractures: A Comparison of Treatment Methods, Journal of Trauma and Acute Care Surgery: November 1999 - Volume 47 - Issue 5 - p 937
- [4]. Müller ME, Nazarian S, Koch P, Schatzker J. The comprehensive classification of fractures of long bones. New York: Springer-Verlag, 1990
- [5]. Tornetta Paul III; Weiner, Lon; Bergman, Marc; Watnik, Neil; Steuer, Jeff; Kelley, Mark; Yang, Edward. Pilon Fractures: Treatment With Combined Internal and External Fixation, Journal of Orthopaedic Trauma: December 1993
- [6]. Ego KA, Wolinsky P, Koval KJ. Open reduction and internal fixation of tibial pilon fractures. Foot and Ankle Clinics [01 Dec 2000, 5(4):873-885]
- [7]. Bone L, Stegemann P, McNamara K, Seibel R. External fixation of severely comminuted and open tibial pilon fractures. Clinical Orthopaedics and Related Research [01 Jul 1993(292):101-107]
- [8]. Marsh, J. Lawrence MD; Bonar, Susan MD; Nepola, James V. MD; Decoster, Thomas A. MD; Hurwitz, Shepard R. MD. Use of an Articulated External Fixator for Fractures of the Tibial Plafond. JBJS: October 1995 - Volume 77 - Issue 10 - p 1498-1509
- [9]. Boraiah, Sreevathsa MD; Kemp, Travis J. MD; Erwtaman, Andrew BS; Lucas, Paul A. PhD; Asprinio, David E. MD. Outcome Following Open Reduction and Internal Fixation of Open Pilon Fractures. JBJS: February 2010 - Volume 92 - Issue 2 - p 346-352
- [11]. Philip A. McCann, Mark Jackson, Steve T. Mitchell, Roger M. Atkins. Complications of definitive open reduction and internal fixation of pilon fractures of the distal tibia. PubMed Int Orthop. 2011 Mar;35(3):413-8. doi: 10.1007/s00264-010-1005-9. Epub 2010 Mar 30
- [12]. Susan K. Bonar M.D., J. Lawrence Marsh, M.D. Unilateral External Fixation for Severe Pilon Fractures, Journal of American orthopaedic foot and ankle society. Volume: 14 issue: 2, page(s): 57-64. Issue published: February 1, 1993
- [13]. Krettek C, Bachmann S. Pilon- fractures. Part 1: Diagnostics, treatment strategies and approaches. Chirurg 2015; 86:87-

Dr Apurba Gorain. "Treatment of Intra And Extra Articular Pilon Fracture of Distal Tibia By Distraction Method: Functional Outcome." IOSR Journal of Dental and Medical Sciences (IOSR-JDMS), vol. 17, no. 1, 2018, pp. 72-74