

## Diffuse Idiopathic Skeletal Hyperostosis: An Anatomical Study in Dried Vertebrae.

\*Mamata Sar<sup>1</sup>, Sarita Behera<sup>2</sup>, Dibya Prabha Bara<sup>3</sup>, Arpita Soy<sup>4</sup>

<sup>1,2,3,4</sup>(Department of Anatomy, VSS Institute of Medical Science and Research, Odisha, India, Email

\*Corresponding author: Mamata Sar

### Abstract

**Background:** Diffuse idiopathic skeletal hyperostosis (DISH) is a disorder characterised by excessive ossification at ligamentous and tendinous attachment sites to the bone. Bony proliferation results in a distinctive pattern of ossification involving the spine and extra spinal structures. Aim: Because axial skeleton is most commonly affected we conducted an anatomical study in dried vertebrae to observe the exact anatomical changes occurring in spine and compare with radiological changes studied in patients.

**Materials and methods:** The vertebrae collected in osteology section of anatomy department of our institute were taken as study material. After excluding damaged, degenerated and unossified specimen we included 392 cervical, 1114 thoracic and 399 lumbar vertebrae and examined for ossification at the attachment sites of ligaments. We estimated the frequency of involvement and severity of pathological changes in different regions and compared them with findings of studies done in patients.

**Results:** Lower cervical, lower thoracic and upper lumbar vertebrae were typically affected by the ossification process. The lower thoracic vertebrae were most commonly affected but involvement of other vertebrae was not rare. C<sub>1</sub>, C<sub>2</sub> and T<sub>1</sub> vertebrae were never affected. Segmental ossification was more common than continuous ossification joining adjacent vertebrae. Bony exostosis was typically found along the lower border of cervical, upper border of lumbar and anterolateral aspect of thoracic vertebrae.

**Discussion:** It has been typically described that DISH involves lower thoracic spine most commonly. We observed in our study that though lower thoracic spine is most frequently affected, involvement of cervical and lumbar vertebrae is not uncommon.

**Keywords:** Anterior longitudinal ligament, hyperostosis, periosteal ossification, exostosis, bony spur

Date of Submission: 12-01-2018

Date of acceptance: 30-01-2018

### I. Introduction

Diffuse idiopathic skeletal hyperostosis (DISH) or forestier's disease is a fairly common disorder, predominantly of older men, characterised by widespread ossification of ligaments and tendon insertions. X-rays show pronounced but asymmetrical intervertebral spur formation and bridging throughout dorsovertebral spine. This is an idiopathic abnormality in which exuberant ossification occurs throughout the body but most notably the anterior longitudinal ligament of spine<sup>1</sup>. DISH most commonly involves the axial skeleton but the thoracic spine in particular is almost always affected. The 7<sup>th</sup> through 11<sup>th</sup> thoracic vertebral level is most frequently involved. Extensive cervical and lumbar vertebral changes may rarely occur in absence of thoracic involvement. In the cervical region, 4<sup>th</sup> through 7<sup>th</sup> vertebral level are most frequently involved<sup>2</sup>. Two types of spinal lesions occur in diffuse idiopathic skeletal hyperostosis. The first type consists of calcification and ossification of fibres of anterior longitudinal ligament. On the lateral radiograph this deposition results in bumps occurring anterior to the disc spaces as the anterior longitudinal ligament passes over the inter vertebral disc. The second type of abnormality occurs due to anterior extension of disc material secondary to tears and defects in anterior annulus fibrosus. Stretching of fibres of anterior longitudinal ligament by the protruding disc material stimulates periosteal new bone formation and results in large umbrella like or claw like periosteal hyperostosis. Periosteal hyperostosis is seen at the anterior aspect of involved vertebral body corresponding to the site of attachment of anterior longitudinal ligament<sup>3</sup>. The hyperostotic excrescences in cervical region usually arise from inferior vertebral margin and extend downward across the disc spaces. In contrast to cervical spine in the lumbar region they extend upward around the disc spaces<sup>3</sup>.

The ossification of anterior longitudinal ligament is again classified into segmental, continuous and mixed type according to whether hyperostosis involves vertebrae individually, continuously or both the variety in same patient<sup>4</sup>. They often produce radiological appearance of "wax dripping from a candle"<sup>4</sup>. Though many studies have been done on this disease in living patients, we found limited literature on anatomical studies. With

an objective of describing the exact anatomical changes occurring in spine we have conducted this observational anatomical study in dried vertebrae collected and preserved in osteology section of our institute.

## **II. Methods**

All the adult intact vertebrae from cervical, thoracic and lumbar regions were included in our study. Vertebrae with incomplete ossification, those with gross degenerative changes and all damaged vertebrae were excluded from our study. We examined 392 cervical, 1114 thoracic and 399 lumbar vertebrae. Vertebrae with ossification of anterior longitudinal ligament, vertebrae with hyperostosis in the form of bony spurs projecting from the margins of vertebral bodies and vertebrae fused with adjacent ones due to ossification of anterior longitudinal ligaments were picked up and examined in detail. We estimated the frequency with which vertebrae from different regions are affected by ossification of ligaments or new bone formation. The nature of hyperostosis, its severity and site of involvement were observed and compared with other radiological studies done in patients.

## **III. observations**

We observed mainly two types of abnormal ossifications. The first type was ossification of anterior longitudinal ligament with fusion of adjacent vertebrae and bumps occurring anterior to the disc spaces where the anterior longitudinal ligament crosses the disc. This type of ligamentous ossification was found only in five cases confined to lower thoracic and first lumbar vertebrae (fig. 1<sub>a</sub> & 1<sub>b</sub>). The second type was periosteal ossification in the form of large umbrella like or claw like growth of osteophytes corresponding to the site of attachment of anterior longitudinal ligament to the upper and lower margins of involved vertebral bodies. The second variant was more commonly observed. Here the adjacent vertebrae did not fuse but remained separate from each other (fig.2-4). Lower thoracic and upper lumbar vertebrae were most commonly affected with a rate of 9% and 8.36% respectively. The atlas, axis and first thoracic vertebrae were not affected. The changes seen in upper thoracic vertebrae were less severe compared to that of other regions. The hyperostotic changes in upper thoracic region were limited to a small area in the midline of vertebral bodies. The bony spurs are projected from upper, lower or both the margins of vertebral bodies. We observed extensive exostosis along the upper & lower margin of cervical vertebrae. In the lower thoracic region they typically affected the anterolateral surface. In lumbar region they were mostly confined to upper margin of vertebral bodies. These changes also give the gross appearance of “wax dripping from a candle”, a radiological sign described in DISH (fig.4)

### **3.1 Observation-1 (in cervical spine)**

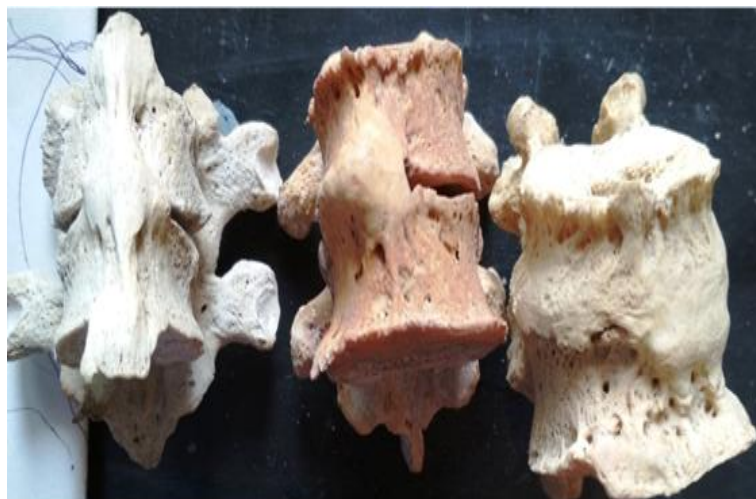Number of vertebrae studied 392  
Atlas -32 (not affected)  
Axis- 39 (not affected)  
C<sub>3</sub>- C<sub>7</sub> – Hyperostosis seen in 24/318 (7.5%)  
Hyperostosis affecting upper margin of vertebral body -4  
Hyperostosis affecting lower margin -10  
Hyperostosis affecting both upper and lower margins- 10

### **3.2 Observation-2 (in thoracic spine)**

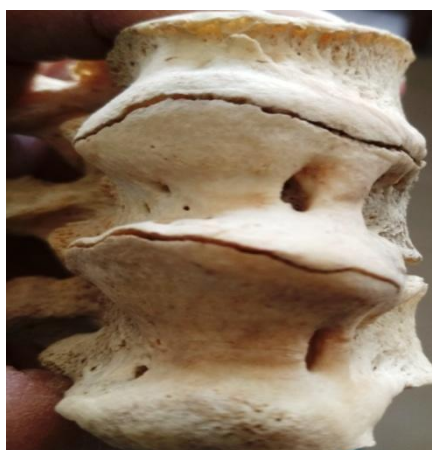Total number of vertebrae studied- 1114  
T<sub>1</sub> - 30 in number. (not affected)  
Anterior longitudinal ligament ossification with fusion of vertebrae- 5  
Typical thoracic Vertebrae (T<sub>2</sub> – T<sub>8</sub>)- hyperostosis seen in 62/785(7.8%)  
Atypical thoracic Vertebrae (T<sub>9</sub>-T<sub>12</sub>)- hyperostosis seen in 27/300 (9%)  
Hyperostosis affecting upper margin- 10  
Hyperostosis affecting lower margin- 15  
Hyperostosis affecting both the margins- 34

### **3.3 Observation 3 (in lumbar spine)**

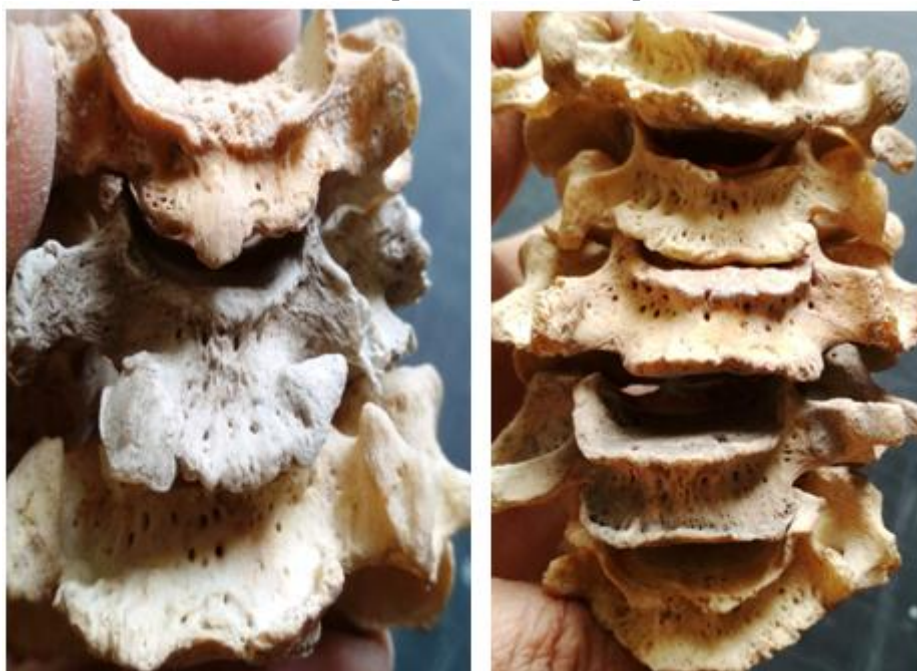Total number of vertebrae studied- 399  
Typical lumbar (L<sub>1</sub> to L<sub>4</sub>)- hyperostosis seen in 25/299(8.36%)  
Atypical lumbar(L<sub>5</sub>)- hyperostosis seen in 5/100 (5%)  
Hyperostosis affecting upper margin of vertebral body-22  
Hyperostosis affecting lower margin- 02  
Hyperostosis affecting both the margins- 06



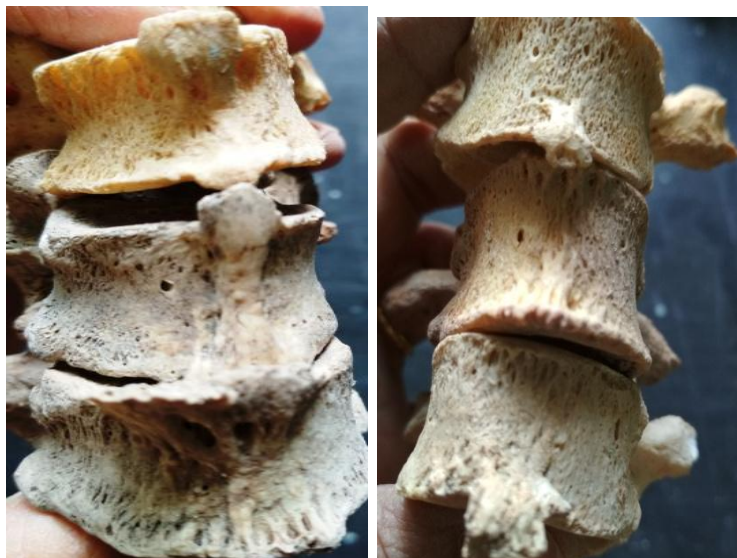**Fig 1a:** Ossification of Anterior Longitudinal Ligament with bumps opposite the intervertebral disc



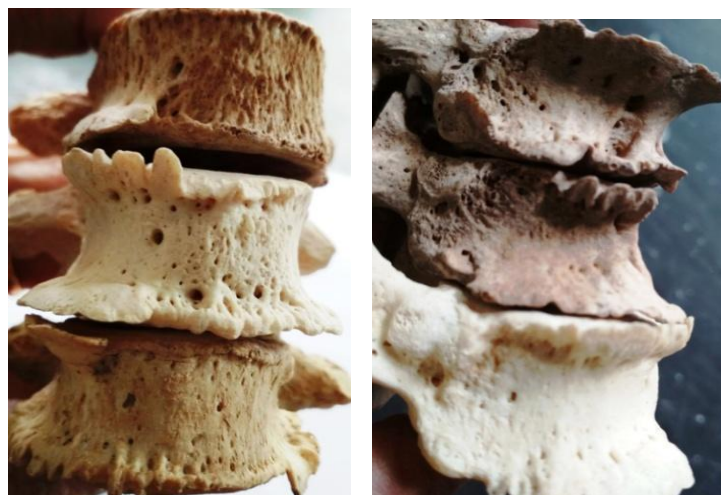**Fig.1b:**Excessive ossification of ALL complicated with acute spinal fracture (chalk stick fracture )



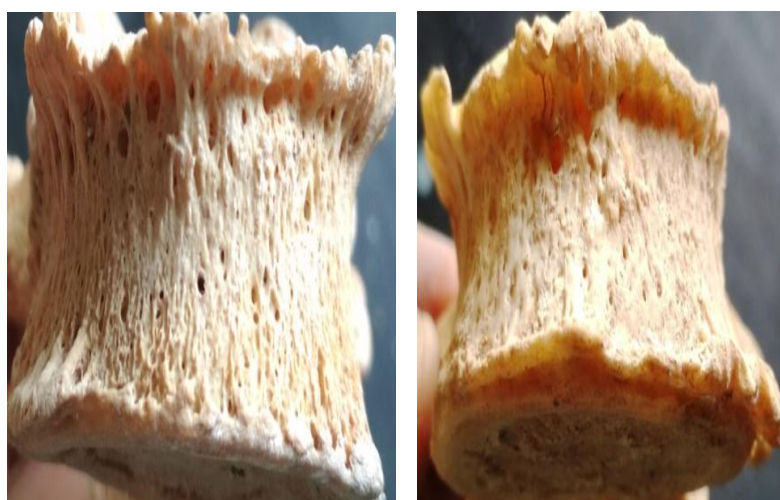
**Fig 2:** Cervical Vertebrae showing hyperostosis along the lower margin (in the left Fig) and both the margins (in the right Fig).



**Fig 3:** Upper thoracic vertebrae with small midline exostosis from upper (left fig.) and lower margins (right fig.)



**Fig 4:** Lower thoracic vertebrae with hyperostosis along the right antero lateral surface, giving appearance of wax dripping from a candle.



**Fig 5:** Lumbar vertebrae with hyperostosis more marked along the upper border.

#### IV. Discussion

Anterior longitudinal ligament is a strong band extending along the anterior surface of the vertebral bodies. It is broader caudally and thicker and narrower in the thoracic than cervical and lumbar regions. It is also relatively thicker and narrower opposite vertebral bodies than at the level of intervertebral symphysis. Its longitudinal fibres are strongly adhered to the intervertebral disc, hyaline cartilage end plates and margins of adjacent vertebrae and loosely attached to the intermediate level of bodies. At these various levels ligamentous fibres blend with subjacent periosteum, perichondrium and periphery of annulus fibrosus<sup>5</sup>In diffuse idiopathic skeletal hyperostosis there is a tendency for ossification of ligaments, tendons and joint capsule insertion, most commonly affecting the spine. Hyperostosis is a type of repair reaction to mechanical stress of ligaments and tendons. In this case osteoblasts originate from mesenchymal precursor cells which cover the intact periosteum. These osteoblasts lay down new bones<sup>6</sup>Studies show that hyperostosis most commonly affects the thoracic spine. According to Talijanovic et al. 7<sup>th</sup> thoracic to 11<sup>th</sup> thoracic vertebrae are involved more frequently than any other region<sup>7</sup>. Resnick et al reported that the thoracic spine classically involved in DISH is 7<sup>th</sup> -10<sup>th</sup> thoracic vertebrae, with a lower incidence in upper thoracic vertebra. In the present study lower cervical, lower thoracic and upper lumbar vertebrae were involved almost uniformly with very little difference in frequency ( 7.5%, 9% & 8.36% respectively). In upper thoracic region the changes were very minimal, marked as small midline exostosis from upper and/ or lower margin. Anterior longitudinal ligament ossification extending over two or more vertebrae was found only in lower thoracic and 1<sup>st</sup> lumbar vertebrae whereas periosteal hyperostosis along the attachment of anterior longitudinal ligament was present all throughout. Hyperostosis affected mostly lower margin of cervical vertebrae in contrast to upper margin of lumbar vertebrae. Resnick et al also reported that the hyperostotic excrescences in cervical region arise from inferior vertebral margin and extend downward across the disc spaces. In contrast to cervical spine in the lumbar region they extend upward around the disc space. Belanger T A et al described florid ossification along the anterior or right anterolateral aspect of contiguous vertebrae<sup>7</sup>. We observed midline ossification in upper thoracic region and right anterolateral ossification in lower thoracic region. In 56 cases the changes were seen on the right anterolateral surface of vertebral bodies in contrast to only 3 cases showing changes on the left anterolateral surface.

#### V. Conclusion

Diffuse idiopathic hyperostosis has not been widely described because it is rarely symptomatic and often discovered by chance on X- ray, CT or MRI. Symptoms may include pain, stiffness and restriction of movements in affected areas. Reduced vertebral column flexibility predisposes to acute spinal fracture known as "chalk stick fracture"<sup>8</sup>. Overgrowth of ligamentous ossification may rarely impinge on other structures like oesophagus producing symptoms like dysphagia<sup>9</sup>. In contrast to earlier studies the present study in dried vertebrae demonstrates that lower cervical and upper lumbar vertebrae are also affected by this process of ossification with almost equal frequency to that of thoracic region. Through this study we are able to clearly demonstrate the changes occurring in different parts of vertebral column affected by diffuse hyperostosis. The anterior longitudinal ligament becomes wider in upper and lower part of vertebral column with a wider area of attachment to cervical and lumbar vertebrae. Possibly this could be the reason why the new bone formation affects the entire upper and/or lower margin of cervical and lumbar vertebrae extensively but in thoracic region they are projecting from a narrow area either from the anterior midline or from antero lateral margin.

#### References

1. Apley's system of orthopaedics and fracture, 9<sup>th</sup> edition. Pg. 69,Luis Solomon, David Warwick,Sevladurai Nayagam, CRC press, Tailor & Francis group, London & New York.
2. Resnick D, Shapiro R F, Wisner K Bet al. Diffuse idiopathic skeletal hyperostosis. Semin arthritis Rheum 1978;7:153-187
3. Resnick D,Niwayama G. Radiographic and pathologic features of spinal involvement in diffuse idiopathic skeletal hyperostosis. Radiology. 1976;119:559-568.
4. J Mijuno, H Nakagawa, J Song. Symptomatic ossification of anterior longitudinal ligament with stenosis of cervical spine: A report of 7 cases. The journal of bone and joint surgery.
5. Standerling S. Gray's Anatomy. The Anatomical basis of clinical practice. Ligaments of vertebral column 40<sup>th</sup> ed. London: Elsevier, Churchill Livingstone Edinburgh; 2008: pg-728
6. Benjamin M et al. Where tendons and ligaments meet the bone, in relation to exercise and mechanical load.J. Anat 2006;208:471-490
7. Talijanovic MS, Hunter TB, Wisneski RJ et al imaging charecteristics of diffuse idiopathic skeletal hyperostosis with an emphasis of acute spinal fracture: review.AJR AMJ Roentgenol.2009;193(3)
8. Belanger TA,Rowe DE. Diffuse idiopathic hyperostosis: musculoskeletal manifestation. J Am Acad orthop surg 9(4) 258-67.
9. Kerr, Roger et al, Diffuse idiopathic skeletal hyperostosis: Radiologic case study. Orthopaedics. November 1985;8(11)

Mamata Sar "Diffuse Idiopathic Skeletal Hyperostosis: An Anatomical Study in Dried Vertebrae.?" IOSR Journal of Dental and Medical Sciences (IOSR-JDMS), vol. 17, no. 1, 2018, pp. 37-41.