

## Assessment of Liver Fibrosis by Transient Elastography and APRI (AST to Platelet Ratio) in patients with Chronic Liver Disease.

Ajay Pratap Singh<sup>1</sup>, Ravi Misra<sup>1</sup>, Ruchika Tandon<sup>1</sup>, Ashim Ghatak<sup>2</sup>, Vivek Bhosale<sup>2</sup>, Kriti Singh<sup>3</sup>

*1(Department of Medicine, King George's Medical University, India)*

*2(Scientist Clinical & Experimental Medicine, CSIR-CDRI, India)*

*3(Department of Obstetrics & Gynecology, King George's Medical University, India)*

*\*Corresponding author: Ajay Pratap Singh*

**Abstract:** Liver biopsy being the 'gold standard' is an invasive investigation; many non-invasive markers are being investigated for prediction of hepatic fibrosis. We aim at assessing the liver fibrosis by Transient Elastography and APRI (AST to PLATELET RATIO) in Chronic Liver Disease. 64 patients of CLD and 64 healthy subjects were included in the study. Transient Elastography was done using FIBROSCAN® and APRI score was calculated. Predominant etiology was CALD (50%) followed by HBV (32.8%) and HCV (17.2%). The mean LSM and APRI score for cases and control was  $36.06 \pm 24.18$  kPa,  $2.47 \pm 2.05$  and  $3.96 \pm 0.97$  kPa,  $0.45 \pm 0.16$  respectively. AUC (95%CI) for diagnosis of significant fibrosis by Transient Elastography and APRI was 0.99 (0.98-1.01) and 0.91 (0.85-0.96) respectively. The optimal LSM value was 4.5 kPa for diagnosis of significant fibrosis with specificity, sensitivity, PPV and NPV of 70.3%, 98.4%, 76.8%, 97.8% respectively. The optimal APRI score was  $>0.70$  for diagnosis of significant fibrosis with specificity, sensitivity, PPV and NPV of 90.6%, 81.3%, 89.7%, 82.9%. Correlation value of  $r = +0.379$  was established between Fibroscan® and APRI score in cases. TE is superior to APRI for non-invasive diagnosis of fibrosis. TE and APRI score are positively correlated with fibrosis in patients with CLD. (10 Italic)

**Keywords:** APRI, Liver Biopsy, Liver Fibrosis, LSM, Transient Elastography.

Date of Submission: 12-01-2018

Date of acceptance: 31-01-2018

### I. Introduction

Cirrhosis is defined anatomically as a diffuse process with fibrosis and nodule formation. It is the end result of the fibrogenesis that occurs with chronic liver injury. [1] Progressive liver fibrosis is a characteristic feature of chronic liver diseases, and its implication is evolution toward cirrhosis, liver failure, and hepatocellular carcinoma with advancement of the primary disease with time.[2] Although Liver biopsy is the gold standard for diagnosis [3] it has several disadvantages and limitations including risks due to its invasive nature and associated stress for patients and physicians, and sampling error, even in diseases that affect the liver uniformly [4]. Noninvasive tests for assessment of liver fibrosis have been proposed and have been used in the past.[5] These tests rely on distinct but complementary approach and include a biologic method, which quantifies serum levels of biomarkers, and a physical method that measures liver stiffness by ultrasound or magnetic resonance imaging.[6] Although no single noninvasive test or model developed to date can match the information obtained from actual histology, combination of two independent noninvasive tests (two blood tests or a blood test + Elastography) can be used and if the results agree, liver biopsy is not needed.[7] Liver stiffness measurement (LSM) by Transient Elastography (TE) is a new upcoming, noninvasive and attractive alternative for staging of fibrosis by noninvasive tests. Many studies have assessed the diagnostic value of TE for accurately predicting fibrosis and have confirmed the excellent diagnostic performance for fibrosis in CLD patients. [8] Liver stiffness values may also be associated with complications and prognosis of disease. [9] The aspartate aminotransferase to platelet ratio index (APRI) has been proposed as a noninvasive and readily available tool for the assessment of liver fibrosis in chronic Liver disease. [10]. APRI as a simple bedside diagnostic tool has been evaluated as a simple and accurate test for detection of significant fibrosis or cirrhosis in the western population.[11] Few studies have been done on correlation of APRI and FIBROSCAN® for detection of fibrosis, hence in this study we aim to evaluate and correlate APRI and FIBROSCAN® for prediction of fibrosis in CLD.

## II. Methods

In a cross-sectional analysis from July 2016 to July 2017 patients admitted in King George Medical University Department of Medicine were screened and 64 patients with Chronic Liver Disease were selected, LSM and APRI score was computed for them. ALD was defined as >60gms of alcohol per day for 10 years, Chronic Hepatitis C was defined as detection of HCV RNA by quantitative real-time polymerase chain reaction (RT-PCR) assay (Roche Diagnostic), with a limit of detection of  $\geq 15$  IU/ml. Chronic Hepatitis B was defined as detection of HBeAg by quantitative real-time polymerase chain reaction (RT-PCR) assay (Roche Diagnostic), with continued evidence of inflammation and necrosis >6 months. The exclusion criteria used was Pregnancy, any cardiac comorbid condition, history of smoking, Chronic kidney disease (creatinine clearance <90ml/min), Obesity (BMI greater than 30), high triglyceride levels (> 200mg/dl), Familial hypercholesterolemia and anti-Fibrotic treatment. 64 age and sex matched controls were also enrolled. The study was approved by institutional ethics committee for assessing the routine clinical data with informed consent.

### 2.1 Transient Elastography AND APRI Score

Transient Elastography is done using FIBROSCAN® (Echosens, France) performed using transducer-induced vibrations at a low frequency (50Hz) and amplitudes. The transmitted shear waves propagate through the liver parenchyma. Pulse-echo ultrasound acquisition is used to follow the propagation of the shear wave and to measure its average speed. Results are expressed in kPa (kilopascal) and can range from 2.5 to 75 kPa [12]. A measurement of liver stiffness was performed on the right lobe of liver through intercostal space while the patients were lying in the dorsal decubitus position with the right arm in maximum abduction. Ten successful measurements were performed on each patient and the median value was considered representative of elastic module of the liver. LSM was considered reliable when it included  $\geq 10$  valid measurements with success rate  $\geq 60\%$  and IQR/M < 0.3 as per usual definition. [13] LSM was categorized referencing the METAVIR fibrosis scoring and cut off values of Fibroscan® [14-16]. Fibroscan score card is a color coded grading scale used to categorize the LSM against Metavir fibrosis Grading for different etiologies, (fig 1) which was used to categorize the cases in fibrosis grading. Liver function test comprised of parameters like SGOT, SGPT, Alkaline phosphatase, and serum bilirubin, performed using a fully automatic HITACHI-912 Auto Analyzer. Platelet count was determined by the fully automatic SYSMEX KX 21 Auto analyzer using the principle of optical impedance and flow cytometry.

## III. Statistical Analysis

The results are presented in frequencies, percentages and mean $\pm$ SD. The Chi-square test was used to assess the association between categorical variables. Kruskal-Wallis test followed by Tukey's post-hoc tests was used to compare more than 2 means. The binary logistic regression was used to find the strength of associations. The odds ratio with its 95% confidence interval (CI) was calculated. The sensitivity, specificity, positive predictive value (PPV) and negative predictive value (NPV) with 95% CI was calculated. The Spearman correlation coefficient was calculated to find the correlation among various parameters. The p-value < 0.05 was considered significant. All the analysis was carried out on SPSS 16.0 version (Chicago, Inc., USA).

## IV. Results

A total 64 patients and 64 controls were enrolled for fibrosis analysis in this study. The mean age for cases and controls were  $45.84 \pm 13.20$  and  $41.23 \pm 11.08$  respectively. Majority of sex in cases (76.6%; n=49) and controls (89.1%; n=57) were males. The predominant etiology in the cases group was CALD (n=32; 50%), HEPATITIS B (n=21; 32.8%) and HEPATITIS C (n=11; 17.2%). The mean liver stiffness for cases and controls was  $36.06 \pm 24.18$  and  $3.96 \pm 0.97$  kPa. 75% (n=48) of cases were of F4 grade fibrosis as per the score card. Mean LSM was calculated in each of the etiological category which showed that it was highest in CALD ( $41.70 \pm 25.30$ ) followed by HEP B ( $32.40 \pm 24.57$ ) and HEP C ( $26.62 \pm 16.23$ ). A cutoff value of 4.5 kPa was obtained in our study and it had AUC (95% CI) of 0.99 (0.98-1.01) and was able to diagnose significant fibrosis with sensitivity, specificity, PPV, and NPV of 98.4%, 70.3%, 76.8% and 97.8% respectively. Table 1 (Fig.2) The mean APRI score for cases and controls was  $2.47 \pm 2.05$  and  $0.45 \pm 0.16$ . APRI score was maximum in F4 ( $3.03 \pm 2.06$ ) grade fibrosis followed by F3 ( $1.27 \pm 0.85$ ), F2 ( $0.66 \pm 0.24$ ) and minimum in F1 ( $0.48 \pm 0.23$ ). A cutoff value of 0.70 was obtained in our study and it had AUC (95% CI) of 0.91 (0.85-0.96) and was able to diagnose significant fibrosis with sensitivity, specificity, PPV, and NPV of 81.3%, 90.6%, 89.7% and 82.9% respectively. Table 2 (Fig 3) A positive significant correlation was obtained between TE fibrosis grading and APRI score with R value = +0.379. (Fig 4)

## V. Discussion

In clinical practice, the determination of fibrosis stage is important to decide whether the patient has mild or advanced liver disease.[6] Since patients with advanced fibrosis have faster progression to cirrhosis, any intervention like abstinence or antiviral therapy must be advised to these patients in order to delay the progression. Needle biopsy of the liver remains the gold standard and provides much useful information. Unfortunately, liver biopsy has some limitations, including sample errors and it is only about 80% accurate in fibrosis staging: it may miss advanced fibrosis in 30% of patients. [17]Over the past two decades, a number of noninvasive approaches have been validated to provide such information. In the present study, we used TE to access fibrosis, because it has been shown to provide a reproducible (intra- and interobserver variability approximately 3%). [18] Overall, for diagnosing significant fibrosis ( $F \geq 2$ ), it has an estimated sensitivity of 70 percent and an estimated specificity of 84 percent. [8]

In our study Transient Elastography was done using FIBROSCAN® (echosens,France) for the grading of fibrosis in patients which showed that 75% (n=48) belonged to grade F4 as per fibroscan color coded scale suggesting that most of the patient approached the hospital in a relatively advanced stage of liver disease, followed by 9.4%(n=6) patients in F2 grade and 7.8%(n=5) patients in each F1 and F3 grade respectively. The mean value of fibrosis as per Transient Elastography in the cases were  $36.06 \pm 24.18$  kPa and in controls it was  $3.96 \pm 0.97$  kPa . The fibroscan value was statistically significantly raised(p value<0.05) in F4 grading of fibrosis than F1, F2 and F3 grade fibrosis with mean values of  $44.97 \pm 21.32$  kPa in F4 and  $7.14 \pm 1.73$  kPa ,  $8.08 \pm 0.65$  kPa and  $12.94 \pm 5.05$  kPa in F1, F2 and F3 respectively. Thus showing that the Fibroscan® fibrosis grading increases with the grade of Fibrosis as per liver biopsy[18] .The mean value of fibroscan fibrosis was calculated in each group of disease(CALD , HEP B and HEP C) in the cases and it came out that fibrosis value (kPa) was maximum in patients with chronic alcoholic liver disease  $41.70 \pm 25.30$  kPa followed by Hepatitis B  $32.40 \pm 24.57$  kPa and Hepatitis C  $26.62 \pm 16.23$  respectively, showing that Cirrhotic patients with alcoholic liver disease had higher liver stiffness values than cirrhotic patients with chronic hepatitis C. [19] In the present study we found that Fibroscan® (echosens, France) was able to detect fibrosis with a sensitivity and specificity of 98.4 and 70.3%. The diagnostic accuracy of Fibroscan was AUC 0.99 (0.98-1.01) for diagnosis of cirrhosis at a cutoff value of 4.5kPa which was obtained comparing the fibroscan values within cases and controls.

Serum biomarkers have also been used as an alternative to liver biopsy for the staging of liver fibrosis. [20] Such one biomarker is Combined score of APRI a simple bedside tool to predict significant fibrosis in patient of Chronic liver disease. It is obtained by the formula: (1). The mean value of APRI in cases was calculated to be  $2.47 \pm 2.05$  and in controls it was calculated as  $0.45 \pm 0.16$  this difference was statistically significant (p value <0.001) showing that values of APRI was increased in the case group than the control group this was in concordance with the study done by **Princi et al** [21] where the mean APRI score of the case cohort and control cohort were  $2.178 \pm 1.224$  and  $0.364 \pm 0.137$  respectively. We obtained a cutoff value of 0.70 in our study and it was able to diagnose significant fibrosis with sensitivity, specificity, PPV, and NPV of 81.3%, 90.6%, 89.7% and 82.9% respectively. This was in concordance with **Lin ZH et al** [22] they concluded that for significant fibrosis, an APRI threshold of 0.7 was 77% sensitive and 72% specific. Comparing the APRI score with the fibrosis grading according to the FIBROSCAN® grading showed that APRI was maximum in patients with the F4 grade fibrosis with the mean value of  $3.03 \pm 2.06$  followed by  $1.27 \pm 0.85$ ,  $0.66 \pm 0.24$  and  $0.48 \pm 0.23$  respectively in F3, F2, and F1 which was statistically significant (p value<0.01) signifying that APRI score increases as the fibrosis grade increases (correlation value =0.379). This was in concordance with **Mattos AZ et al** [23] they concluded that both APRI and Transient Elastography have high diagnostic odds for detecting fibrosis and cirrhosis in patients with HepC. We obtained a positive significant correlation value = +0.379 between Transient Elastography fibrosis grading and APRI signifying that as the fibrosis increase the APRI score increases.

## VI. Conclusion

This study shows that LSM measurement by Transient Elastography(FIBROSCAN®) and APRI score can be used with fair reliability to predict fibrosis in patients with Chronic Liver Disease. TE is superior to APRI for diagnosis of fibrosis and both are positively correlated to each other.

$$APRI = \frac{\left( \frac{AST}{AST \text{ upper normal level}} \right)}{\text{Platelet Count } (10^9/L)} \times 100$$

Equation 1: Formula to calculate APRI(AST to Platelet ratio)

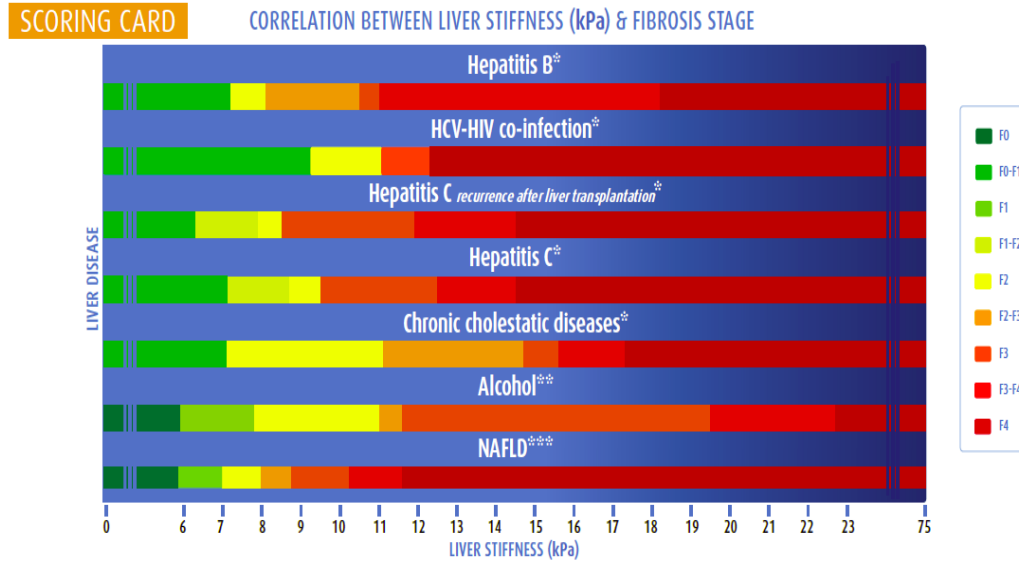


Fig 1 FIBROSCAN COLOR CODED SCORING CARD[14-16]

FIBROSCAN VALUE	Cases		Controls		Total	
	No.	%	No.	%	No.	%
Cutoff						
>4.75	63	49.2	19	14.8	82	64.1
≤4.75	1	0.8	45	35.2	46	35.9
Total	64	50.0	64	50.0	128	100.0
<b>Diagnostic values, % (95%CI)</b>						
Sensitivity	98.4 (95.4-101.5)					
Specificity	70.3 (59.1-81.5)					
PPV	76.8 (67.7-86.0)					
NPV	97.8 (93.6-102.0)					
AUC (95%CI)	0.99 (0.98-1.01)					

Table 1. Fibroscan® in prediction of fibrosis with cut off value of 4.5kPa.

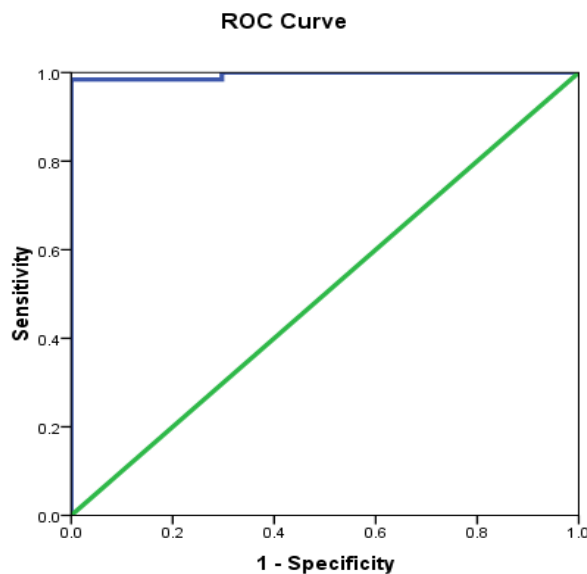
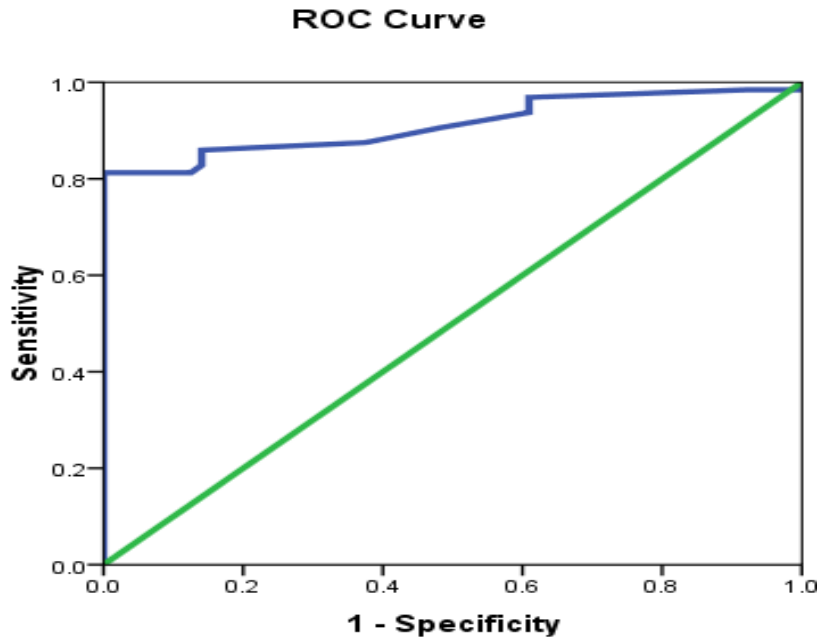


Fig 2. ROC curve showing sensitivity and specificity of Fibroscan® for detection of Fibrosis.

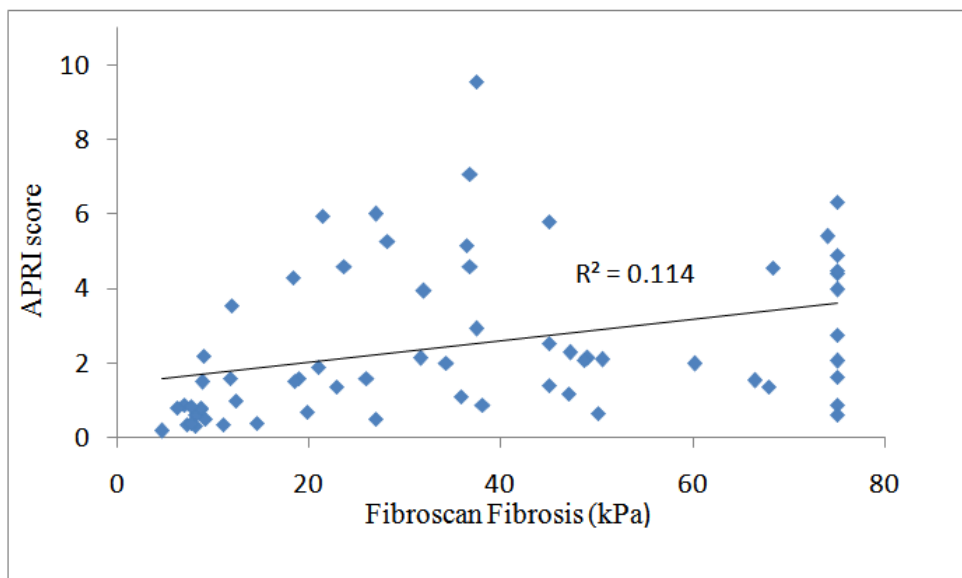
APRI score	Cases		Controls		Total	
	No.	%	No.	%	No.	%
Cutoff						
>0.70	52	40.6	6	4.7	58	45.3
≤0.70	12	9.4	58	45.3	70	54.7
Total	64	50.0	64	50.0	128	100.0
<b>Diagnostic values, (95%CI)</b>						
Sensitivity	81.3 (71.7-90.8)					
Specificity	90.6 (83.5-97.8)					
PPV	89.7 (81.8-97.5)					
NPV	82.9 (74.0-91.7)					
AUC (95%CI)	0.91 (0.85-0.96)					

**Table 2.** APRI score in prediction of fibrosis with cutoff score of 0.70.



Diagonal segments are produced by ties.

**Fig 3.** ROC curve showing sensitivity and specificity of APRI score for detection of Fibrosis



**Fig 4.** Correlation of Fibroscan Fibrosis value (kPa) and APRI score showing Positive correlation( $r=0.379$ )

## References

- [1]. Sherlock S. Hepatic Cirrhosis : Disease of the liver and biliary system , ed 12<sup>th</sup> oxford: Blackwell scientific publication, 1993;103-120
- [2]. Iwaisako K., Brenner D.A., and Kisseleva T.: What's new in liver fibrosis? The origin of myofibroblasts in liver fibrosis. *J GastroenterolHepatol* 2012; 27: pp. 65-68
- [3]. Cross Ref (<http://dx.doi.org/10.1111/j.1440-1746.2011.07002.x>)
- [4]. RockeyDC , Caldwell SH , Goodman ZD et al. Liver Biopsy:AASLD position paper . *Hepatology*2009 ;49: 1017 – 1044 .
- [5]. RockeyD , Bissell D . Noninvasive measures of liver fibrosis. *Hepatology*2006 ;43: S113 – S20 .
- [6]. Bruno R., Sacchi P., Cima S., et al: Correlation between FIB4, liver stiffness and metabolic parameters in patients with HIV and hepatitis C virus co-infection. *Dig Liver Dis* 2011; 43: pp. 575-578Cross Ref (<http://dx.doi.org/10.1016/j.dld.2011.03.009>)
- [8]. Castera L.: Noninvasive methods to assess liver disease in patients with hepatitis B or C. *Gastroenterology* 2012; 142: pp. 1293-1302Cross Ref (<http://dx.doi.org/10.1053/j.gastro.2012.02.017>)
- [9]. Paul Calès ,FrédéricOberti, Sophie Michalak, Isabelle Hubert-Fouchard, Marie-Christine Rousselet, AnselmeKonaté et al. A novel panel of blood markers to assess the degree of liver fibrosis.*JHepatology* 2005; Volume 42, Issue 6 December 2005 Pages 1373–1381 DOI:10.1002/hep.20935
- [10]. Talwalkar JA, Kurtz DM, Schoenleber SJ, et al. Ultrasound-based transient elastography for the detection of hepatic fibrosis: systematic review and meta-analysis. *ClinGastroenterolHepatol* 2007; 5:1214.
- [11]. Castéra L, Le Bail B, Roudot-Thoraval F, et al. Early detection in routine clinical practice of cirrhosis and oesophagealvarices in chronic hepatitis C: comparison of transient elastography (FibroScan) with standard laboratory tests and non-invasive scores. *JHepatol* 2009; 50:59.
- [12]. Loaeza-del-Castillo A, Paz-Pineda F, Oviedo-Cárdenas E, Sánchez- Avila F, Vargas-Vorácková F. AST to platelet ratio index (APRI) for the noninvasive evaluation of liver fibrosis.*AnnHepatol* - October 1, 2008; 7 (4);350-7
- [13]. Lieber C.S., Weiss D.G., Morgan T.R., et al: Aspartate aminotransferase to platelet ratio index in patients with alcoholic liver fibrosis. *Am J Gastroenterol* 2006; 101: pp. 1500-1508 CrossRef(<http://dx.doi.org/10.1111/j.1572-241.2006.00610.x>)
- [14]. Castéra L, Vergniol J, Foucher J, et al. Prospective comparison of transient elastography, Fibrotest, APRI, and liver biopsy for the assessment of fibrosis in chronic hepatitis C. *Gastroenterology* 2005; 128:343.
- [15]. Boursier J., Zarski J.P., de Ledinghen V., et al: Determination of reliability criteria for liver stiffness evaluation by transient elastography. *Hepatology* 2013; 57: pp. 1182-1191 Cross Ref (<http://dx.doi.org/10.1002/hep.25993>)
- [16]. Transient elastography(Fibroscan®):V.de ledinghen, J. Vergniol, *GastroenterologieClin Bio* (2008),32,58-67.
- [17]. Wong et al. Diagnosis of fibrosis and cirrhosis using liver stiffness measurement. *Hepatology* (2010)51, 454-62
- [18]. Nahon P et al. Assessment of liver fibrosis using transient elastography in patients with alcoholic liver disease. *J Hepatol*. 2008 Dec;49(6):1062-8
- [19]. Maharaj B, Maharaj RL, Leary WP et al. Sampling variability and its influence on the diagnostic yield of Percutaneous needle biopsy of the liver. *Lancet* 1986; 1: 523-525.
- [20]. Fraquelli M, Rigamonti C, Casazza G, et al. Reproducibility of transient elastography in the evaluation of liver fibrosis in patients with chronic liver disease. *Gut* 2007; 56:968
- [21]. J Foucher, E Chanteloup, J Vergniol, L Castéra, B Le Bail, X Adhoute et al. Diagnosis of cirrhosis by transient elastography (FibroScan): a prospective study *Gut*. 2006 Mar; 55(3): 403–408. doi: 10.1136/gut.2005.069153
- [22]. Crisan D., Radu C., Lupsor M., Sparchez Z., Grigorescu M.D., and Grigorescu M.: Two or more synchronous combination of noninvasive tests to increase accuracy of liver fibrosis assesment in chronic hepatitis C; results from a cohort of 446 patients. *Hepat Mon* 2012; 12: pp. 177-184
- [23]. Princi Jain, B.K. Tripathi, B. Gupta, BhartiBhandari, and DiveshJalan. Evaluation of Aspartate Aminotransferase-to-Platelet Ratio Index as a Non-Invasive Marker for Liver Cirrhosis. *J ClinDiagn Res*. 2015 Nov; 9(11): OC22–OC24. doi: 10.7860/JCDR/2015/13944.6814
- [24]. Lin ZH , Xin YN, Dong QJ, Wang Q, Jiang XJ, Zhan SH et al. Performance of the aspartate aminotransferase-to-platelet ratio index for the staging of hepatitis C-related fibrosis: an updated metaanalysis. *Hepatology*. 2011 Mar;53(3):726-36. doi: 10.1002/hep.24105
- [26]. Mattos AZ, MattosAA . Transient Elastography vs. Aspartate Aminotransferase to Platelet Ratio Index in Hepatitis C: A Meta-Analysis *Ann Hepatol* - May 1, 2017; 16 (3); 349-357

Ajay Pratap Singh "Assessment of Liver Fibrosis by Transient Elastography and APRI (AST to Platelet Ratio) in patients with Chronic Liver Disease." *IOSR Journal of Dental and Medical Sciences (IOSR-JDMS)*, vol. 17, no. 1, 2018, pp. 42-47.