

A Study on Numeric Variation of Gonadal Veins in Eastern India: Embryological Aspect and Its Application

Dr Soumedhik Dey¹, Dr Banani Kundu², Dr Abhijit Bhakta³

¹Dr Soumedhik Dey, Assistant professor, Dept of Anatomy, Nil Ratan Sircar medical college and hospital, Kolkata

²Dr Banani Kundu, Assistant professor, Dept of Anatomy, R. G. Kar Medical College and hospital, Kolkata

³Dr Abhijit Bhakta, Associate Professor, Dept of Anatomy, Nil Ratan Sircar Medical College and Hospital, Kolkata.

Corresponding Author: Dr Soumedhik Dey

Abstract

Introduction : The gonadal veins are anatomically asymmetric. They are single in number on each side but they drain differently.

Aim : Our aim is to analysis the percentage of dual gonadal veins on both sides.

Material And Method: We explore 67 well embalmed bodies during our routine undergraduate and post graduate teaching at various medical colleges over a period of three and a half year.

Result : In our present study, male is to female ratio was found 46 :21. Though we do not found any variation in ovarian veins but in the 2 cases(4.34%)left sided testicular vein shows duplication and both the veins drain into left renal vein.

Discussion : Duplication on left side may be due to the alteration in anastomotic channel of postcardinal, supracardinal and subcardinal veins.

Conclusion : The gonadal vein present in numeric variation and its knowledge is essential during various renal and gonadal surgical operations.

Date of Submission: 20-01-2018

Date of acceptance: 01-02-2018

I. Introduction

One of the essential organs is testis or ovary in our body. The testes are a pair of male reproductive organ, where left testis lies about 1 cm below the right one⁽¹⁾. A sound knowledge regarding the variations of blood vessels is important during operative, diagnostic and endovascular procedures in the abdomen. Knowledge of the variations in the renal vein and gonadal vein is important for urologists also. The objective of our study is to bring awareness to the clinician regarding the abnormal venous pattern of gonad. The report is also useful for surgeons to perform surgery. Normally, right gonadal vein drains directly into the inferior vena cava and left gonadal vein drains into left renal vein. The left testicular vein drains in the left renal vein at a straight angle, whereas the right testicular vein drains directly in the inferior vena cava producing an oblique angle⁽²⁾. This anatomical difference is also considered responsible for frequent left varicocele⁽³⁾. The ovarian veins are similar to the testicular veins in origin and termination. They originate from the plexus in the broad ligament near the ovary and fallopian tube, then left ovarian vein drains in the left renal vein and right one drains directly in the IVC. Various studies done previously showed numeric variations as well as variations in drainage of gonadal veins. But very few research works have been done so far about these variations in eastern India. Therefore, we studied 67 bodies to find out the percentage of dual gonadal veins in eastern India.

II. Aims And Objectives

The origin, course and termination of the gonadal veins were observed in this cadaveric study to increase our knowledge regarding the possible variations which may be helpful not only to the clinicians, surgeons but also to the radiologists.

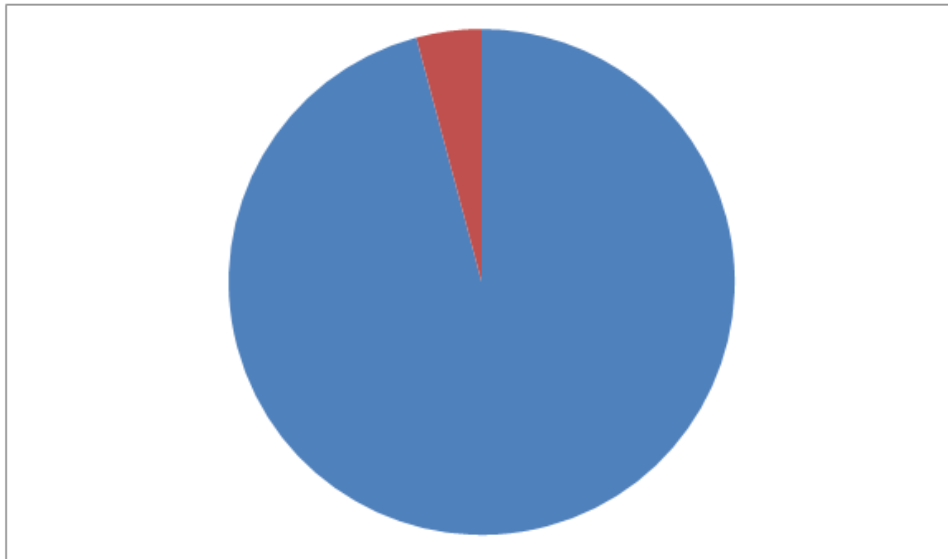
III. Materials And Method:

67 well embalmed bodies were dissected (134 gonadal veins) over a period of three and half years in the department of Anatomy of various Medical Colleges of West Bengal. Among these 46 were male and 21 were female. The abdominal cavities were opened and all retroperitoneal structures were exposed. All Gonadal vessels, Renal vessels, Abdominal Aorta and Inferior vena cava were seen and connective tissues

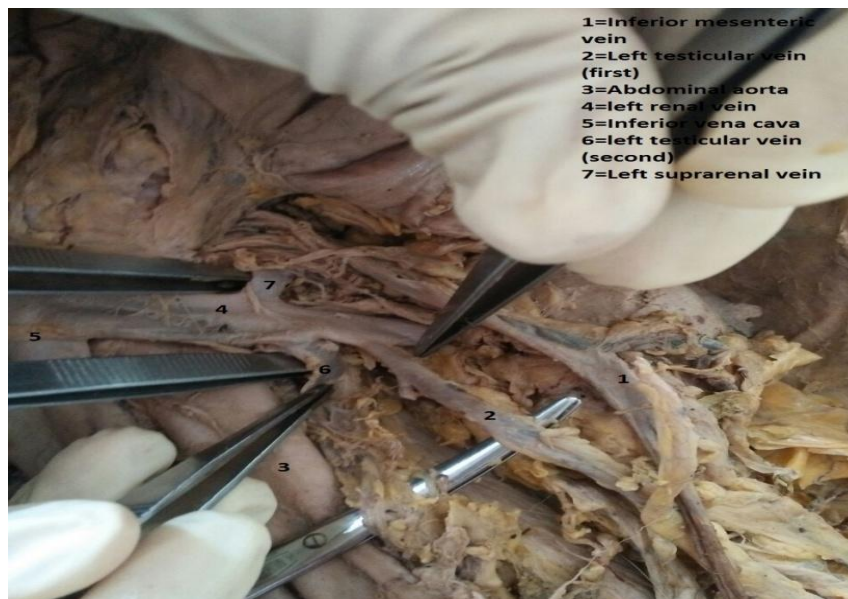surrounding these were removed. We thoroughly observed the drainage of gonadal veins of both sides in all cadavers. The photograph was taken during dissection. They were properly labeled and percentage of dual gonadal vein among the cadaver was noted.

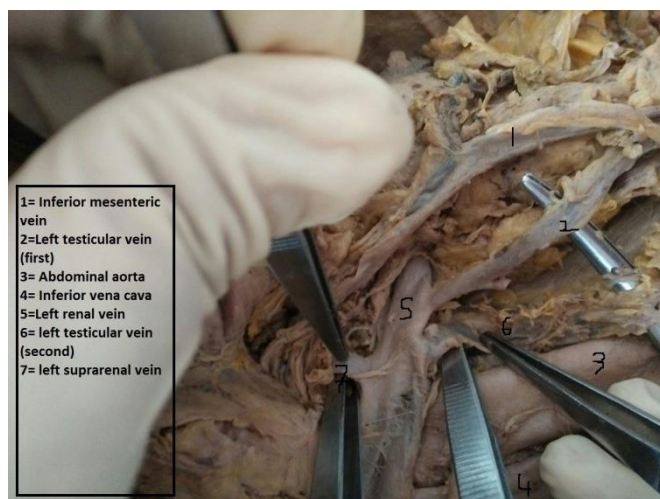
Observation and results:

During abdominal dissection, we observed dual gonadal veins in two male cadavers. After removing transverse colon and small intestine, the abdominal aorta and inferior vena cava were exposed. Suddenly it was found that there was two gonadal vein present on left side, even both drained into the left renal vein. Among all the gonadal veins dissected we noticed dual testicular veins only in 2 cases among 46 and in all two cases they were present in left side. So in male dual testicular vein is present in 4.34%. But in female dual ovarian veins were not reported.



Pic 1: Pie chart showing occurrence rate of dual gonadal veins





IV. Discussion

The variations of gonadal veins are clinically very important for invasive interventions such as laparoscopic surgery and transplantation of kidney. Gonadal vein is a readily available material for vascular reconstruction and renal transplantation in living. For elongation of renal vein especially in right living donor kidney, gonadal vein has been used as a simple and safe method. We applied the donor gonadal vein for lacerated accessory renal artery and renal vein reconstruction. The anatomy of the gonadal veins has assumed importance because of the new operative techniques within the abdominal cavity and also for operations such as varicocele, undescended testes etc⁴. Adequate knowledge can avoid most of the complications. The duplicated testicular vein may act as additional collateral route. According to the study done by Asala et al⁵, variations were seen in 21.3% of the cadavers and were more common on the left side and in 18.8% of cases, the variations were present bilaterally. In our study we also found that numeric variations were only present in left side. Another study done by Raman Gupta, Gupta A and Aggarwal⁶ on 60 cases, they found male: female ratio was 2:1 (40:20) in which no variation was found in ovarian veins. In the 18 (45%) cases, testicular veins showed variations on number and drainage. These variations were found more frequently in the left side 12 (30%) cases as compared to right 2 (5%) but in 4 (10%) cases, the variations were present bilaterally. But Duques et al.,⁷ presented a single testicular/ovarian vein in 85.2% and double in 8.8% of cases. According to study of Lechter et al.,⁸ double testicular veins occurred in 5% of cases in right side but 15% cases show two, 2% three and only 1% case show four veins in left side. Duplication of Gonadal vein is of interest for radiologists in avoiding diagnostic errors as well as to surgeons as anomalous veins that ought to be ligated during surgery for varicocele, go unnoticed and result in recurrence of the varicocele which is regarded as the cause of male infertility⁹. Variations of drainage of gonadal veins can be explained embryologically.

Embryological basis

The development of gonadal vein is closely related to the development of renal vein and IVC. Their development includes regression, anastomosis and replacement of posterior cardinal, sub-cardinal and supra-cardinal venous channels. Anastomosis between the supra-cardinal and the sub-cardinal veins occur bilaterally and form the renal segment of IVC¹⁰. Gonadal vein develops from caudal part of sub-cardinal vein and it drains into the supra-sub cardinal anastomosis. In the right side, this supra-sub cardinal anastomosis and also a small portion of Sub-cardinal vein are incorporated into the formation of IVC, so right gonadal vein usually drains into the IVC. In the left side, this supra-sub cardinal anastomosis forms part of left renal vein where the left gonadal vein drains¹¹. An error of embryological development in venous shift and alteration in anastomotic channel of development leads to venous anomalies like this.

V. Conclusion

The incidence of anatomical variation has been noted in our present study. Occurrence of variation though rare in number, but almost it is observed in left side. The knowledge from our present study is significant for our surgical and radiological purpose.

References

- [1]. Datta A K, Essential of human anatomy (thorax and abdomen); section III: 332.
- [2]. Favorito LA, Costa WS, Sampaio FJ, Applied anatomic study of testicular veins in Adult Cadavers and in Human Fetuses. Int Bra J Urol. 2007; 33(2): 176 -80.

- [3]. Itoh M, Moriyama H, Tokunaga Y, et al. Embryological consideration of left testicular vein into ipsilateral renal vein: Analysis of a case of double inferior vena cava. *Int J Androl*. 2001; 24(3):142-52.
- [4]. Pushpa Dhar, Kumud Lal. Main and accessory renal arteries – A morphological study. *J Anat Embryol*. 2005; 110:101–10.
- [5]. Asala S, Chaudhary SC, Masumbuko-Kahamba N, Bidmos M. Anatomical variations in the human testicular blood vessels. *Ann Anat*. 2001; 183(6):545-49.
- [6]. Gupta R, Gupta A, Aggarwal N. Variation of Gonadal Veins: Embryological Prospective and Clinical Significance. *Journal of Clinical and Diagnostic Research*. 2015 Feb; vol-9(2):08-10.
- [7]. Duques P, Rodrigues JR, Silva Neto FB, Neto EMVS, Toledo ES. Estudo anatômico da veia renal esquerda de cadáveres humanos brasileiros. *Medicina Ribeirão Preto*. 2002; 35:184-91.
Lechter A, Lopez G, Martinez C, Camacho J. Anatomy of the gonadal veins: a reappraisal. *Surgery*. 1991; 109(6):7335-39.
- [8]. Tubbs RS, Salter ES, Oakes WJ. Unusual drainage of the testicular veins. *Clin Anat*. 2005; 18:536–39.
- [9]. Rudloff U, Holmes RJ, Prem JT, Faust GR, Moldwin R, Siegel D. Mesoaortic compression of the left renal vein (nutcracker syndrome): case reports and review of the literature. *Ann Vasc Surg*. 2006; 20(1):120–29.
- [10]. Sharma P, Salwan SK. Anomalous Right Testicular Artery and Vein. *J Clin Diagn Res*. 2011; 5(8):1631-33.

Dr Soumedhik Dey, "A Study on Numeric Variation of Gonadal Veins in Eastern India : Embryological Aspect And Its Application" *IOSR Journal of Dental and Medical Sciences (IOSR-JDMS)*, vol. 17, no. 1, 2018, pp. 72-74