

A Rare Case of Pleomorphic Sarcoma of Breast A Case Report

Dr. Ramesh Kumar Korumilli¹, Dr. J. SriKanth², Dr. M. Sri Harsha³, Dr.Sai Kumar.P⁴, Dr T.Aditya⁵

¹(Professor and HOD, General surgery, SVS Medical college, Dr NTR university of Health sciences, INDIA)

^{2, 3, 4, 5} (Post-Graduates of General Surgery, SVS Medical college, Dr NTR university of Health sciences, INDIA)

Abstract: Pleomorphic sarcoma of breast is a rare entity. Here we present a case of 27 year old female who came with complaints of swelling in Right breast since 2 months. Initial clinical, FNAC and mammography suggested a BIRADS GRADE 3 -4 with provisional diagnosis as Phyllodes tumor with atypical cells. Excision of lump with wide margin is done and sent for Histopathological examination. After extensive sampling and with the help of immunohistochemistry markers the diagnosis of high-grade pleomorphic sarcoma with margins positive was made. Modified radical mastectomy was done, no lymph node infiltration and margins are clear. Post op uneventful and patient is kept on regular follow-up.

Keywords: immunohistochemistry, mesenchymal tumor, pleomorphic sarcoma, vimentin, young female

I. Introduction

Sarcomas of the breast are a very rare entity. They represent less than 1% of all breast malignancies. They arise from connective tissue of breast and are histologically heterogenous non-epithelial malignancies. [1] Undifferentiated pleomorphic sarcoma constitutes for less than 5 % of all adult sarcomas, they are very rarely seen in breast. Most of them are seen in 6th and 7th decades of life and very rare in adolescents and adults. [2] Here we report a very rare case of undifferentiated pleomorphic sarcoma of breast in a 27 year old female which is diagnosed after thorough histopathological examination along with help of immunohistochemistry markers.

II. Case Report

A 27 year old female came to our hospital with complaints of lump in right breast since 2 months, not associated with pain and nipple discharge. No history of exposure to any kind of radiation. No history of ovarian or breast cancers in the family. She was on thyroxine supplementation for hypothyroidism since 2 years.

On physical examination, a 7X5 cm size mass was felt in right upper outer quadrant. It is non tender, firm in consistency with restricted mobility and well demarcated borders. Nipple areolar complex is normal and no clinically palpable lymph nodes in axilla. Left breast is normal. Ultrasonography revealed a firm, hypoechoic lesion with irregular borders. No axillary lymphadenopathy seen. FNAC suggestive of Phyllodes tumor with atypical cells. Excision of the tumor with wide margin is done and the specimen was sent for biopsy. Cut section shows grey white to grey brown soft tumor with fleshy areas as well as slit like spaces noted, foci of necrosis noted, no lymph nodes identified. Superior, inferior and posterior margins of the tumor are found to be positive. Microscopic examination of specimen shows that tumor is highly cellular with mitosis count of 10-19/HPF (score 2). Epithelial components of phyllodes is lacking. Tumor gaint cells, mitotic figures, tumor necrosis noted. Liposarcomatous foci as well as rhabdoid area noted. Herring bone pattern as in fibrosarcoma noted. Areas of myofibroblastic differentiation seen. Alarmingly large tumor cells with altered N: C ratio noted as well as foci consisting of round cells with scanty cytoplasm. FNCLCC grade is 3, tumor differentiation score is 3, tumor necrosis score is 3 and the overall histological grade is 3.

A Rare Case Of Pleomorphic Sarcoma Of Breast - A Case Report

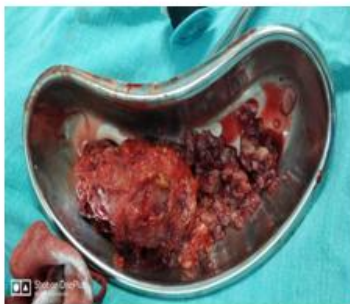

Fig.1 Gross Specimen

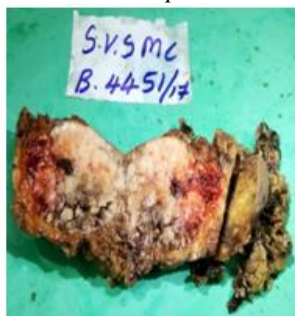

Fig.2 Cut Section

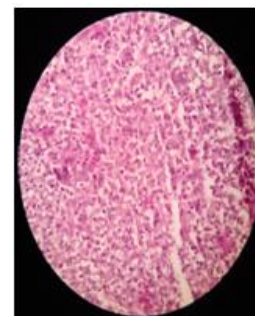


Fig.3 Histopathology

Immunohistochemistry staining for vimentin is strongly positive and SMA is positive in areas of myofibroblastic differentiation. Cytokeratin, S-100, CD10 and Desmin were negative. CD45 showed focal positivity. In the view of vimentin positivity, presence of fibrosarcomatous features along with lack of epithelial component favoured the diagnosis towards High grade Pleomorphic sarcoma. The patient underwent modified radical mastectomy. Margins are clear and no lymph node infiltration. Post operative period was uneventful. No radiotherapy or chemotherapy given. Patient is advised regular follow-up.

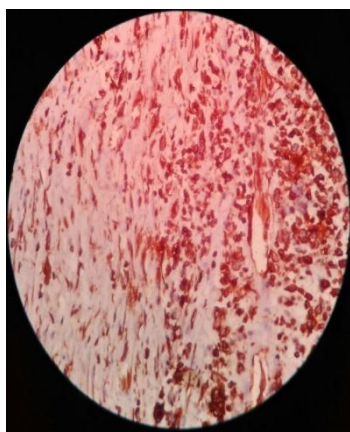


Fig. 4 Vimentin

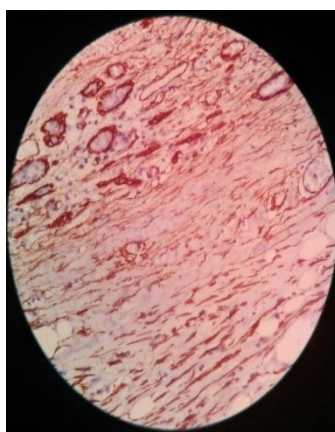


Fig. 5 SMA

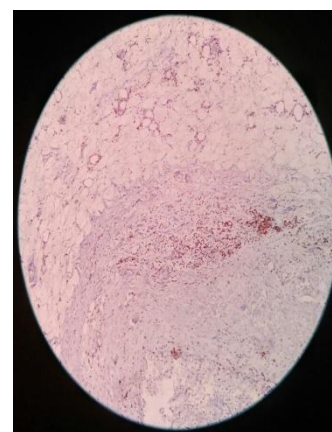


Fig.6 CD 45

III. Discussion

Primary sarcoma of breast is a rare type of malignancies of breast. It accounts for less than 1% of all breast malignancies.^[3] Pleomorphic sarcoma of breast is defined as a group of pleomorphic, highgrade sarcomas in which any attempt to disclose their line of differentiation has failed.^[4,5] It is mainly a diagnosis of exclusion based on histological and immunohistochemistry staining^[5,6] Undifferentiated pleomorphic sarcomas are rarely seen in breast, they constitute approximately 10.5 to 24 % of all primary breast sarcomas^[5,6]. They mainly affect woman in 6th or 7th decade, there are also reports of males getting affected^[7]

Clinical findings, mammography and ultra sonography of the breast have very limited role in the diagnosis of pleomorphic sarcoma. Microscopically also it is very difficult to differentiate it from other malignant mesenchymal and epithelia tumors of the breast. Sonographically the tumor can be identified as well circumscribed mass with well defined margins. On gross examinations, it can be identified as pale fibrous and fleshy areas admixed with zones of necrosis, hemorrhage, or myxoid features^[8]. Microscopically, pleomorphic sarcomas shows cells with marked

A Rare Case Of Pleomorphic Sarcoma Of Breast – A Case Report

pleomorphism along with bizarre giant cells, spindle cells and variable foamy cells^[9]. A storiform growth pattern and variable chronic inflammatory cells are also common^[8]

Differential diagnosis include metaplastic carcinoma (sarcomatoid), malignant phyllodes tumor, inflammatory myofibroblastic tumor (IMT), myxofibrosarcoma, stromal sarcoma, leiomyosarcoma, rhabdomyosarcoma and liposarcoma. Immunohistochemistry, therefore is essential to differentiate the mesenchymal tumors from non mesenchymal tumors of the breast and it is useful in determining the histogenesis of tumor^[10,11]. The markers usually done are vimentin (a mesenchimal marker), Cytokeratin Pan (epithelial cells marker), CD34 and bcl-2 (to identify malignant phylloides tumor) Leukocyte Common Antigen (lymphoid cells marker), SMA (smooth muscle actin), Desmin (smooth and streaked muscular cells marker), S100 (neuronal cells marker), and CD99 (synovial sarcoma marker). It is a diagnosis based on exclusion.

Pleomorphic sarcoma rarely spread through lymphatics, so axillary lymph node dissection is not usually done. A simple mastectomy without axillary dissections is the preferred surgical treatment. They have high incidence of recurrence and distant metastasis. Of all the cases less than 40 % have local recurrence and around 60% develop distant metastases^[12] Overall 5 year survival has been less than 50.^[8] Adjuvant chemotherapy and radiation is not generally recommended as their role is unclear.^[13]

IV. Conclusion

In conclusion, high grade pleomorphic sarcoma of the breast is a very rare tumor especially in adolescents and young adults. Very few cases have been reported till date in young females. It is very difficult to diagnose based on the clinical findings and imaging modalities. Immunohistochemistry helps in tumor differentiation. The diagnosis of pleomorphic sarcoma in our case is by thorough histological examination, immunohistochemistry staining and it is a diagnosis of exclusion.

References

- [1]. Moore MP, Kinne DW. Breast sarcoma. *Surg Clin North Am.* 1996; 76:383–92.
- [2]. Fletcher CD, Vandenberg E, Molenaar W. Pleomorphic malignant fibrous histiocytoma/undifferentiated high grade pleomorphic sarcoma. In: *The WHO classification of tumors of soft tissue and bone.* Lyon: IARC press; 2002. p. 120.
- [3]. McGowan TS, Cummings BJ, O'Sullivan B, Catton CN, Miller N, Panzarella T : An analysis of 78 breast sarcoma patients without distant metastasis at presentation. *Int J Radiat Oncol Boil Phys* 2000, 46:383-390
- [4]. Fletcher CD. The evolving classification of soft tissue tumours: an update based on the new WHO classification. *Histopathology.* 2006; 48:3–12.
- [5]. Adem C, Reynolds C, Ingle JN, Nascimento AG. Primary breast sarcoma: clinicopathologic series from the Mayo Clinic and review of the literature. *Br J Cancer.* 2004; 91:237–41.
- [6]. Pandey M, Mathew A, Abraham EK, Rajan B. Primary sarcoma of the breast. *J Surg Oncol.* 2004; 87:121–5.
- [7]. Jeong YJ, Hoon Kyu O, Bong JG. Undifferentiated pleomorphic sarcoma of the male breast causing diagnostic challenges. *J Breast Cancer.* 2011; 14: 241–6.
- [8]. Zelger B, Burgdorf WH. In: *Skin Cancer.* 1. Nouri K, editor. New York: McGraw-Hill; 2007. Fibrohistiocytic tumors; pp. 205–207.
- [9]. Jain M, Malhan P. Cytology of soft tissue tumors: pleomorphic sarcoma. *J Cytol.* 2008; 25:93–96. doi: 10.4103/0970-9371.44040.
- [10]. Al-Nafussi A. Spindle cell tumours of the breast: practical approach to diagnosis. *Histopathology.* 1999; 35:1–13. doi: 10.1046/j.1365-2559.1999.00766.x
- [11]. Balbi G, Di Martino L, Pitruzzella G, Pitruzzella D, Grauso F, Napolitano A, Seguino E, Gioia F, Orabona P. Undifferentiated pleomorphic sarcoma with osteoclast-like giant cells of the female breast. *World J Surg Oncol.* 2013; 11:21.
- [12]. Weiss SW, Goldblum JR, Enzinger FM. *Soft Tissue Tumors.* 5. Maryland Heights, MO: Mosby; 2009.
- [13]. Shabahang M, Franceschi D, Sundaram M, Castillo MH, Moffat FL, Frank DS, Rosenberg ER, Bullock KE, Livingstone AS. Surgical management of primary breast sarcoma. *Am Surg.* 2002; 68:673–677. discussion p.677

Dr. Ramesh Kumar Korumilli "A Rare Case of Pleomorphic Sarcoma of Breast a Case Report."
IOSR Journal of Dental and Medical Sciences (IOSR-JDMS) , vol. 17, no. 01, 2018, pp. 57–59.