

## A Rare Case of Ileo-Colo-Colic Intussusception in An Adult

\*Dr. Alex Arthur Edwards<sup>1</sup>, Dr. Ajay Abraham<sup>2</sup>

<sup>1</sup>Associate Professor, Department of General Surgery, Tirunelveli Medical College, Tirunelveli, India.

<sup>2</sup>Junior Resident, Department of General Surgery, Tirunelveli Medical College, Tirunelveli, India.

Co-Author : Dr. Alex Arthur Edwards M.S<sup>1</sup>

**Abstract:** We report the case of a 49 year old female who presented in our emergency department with abdominal pain, vomiting and blood in stools. Patient was evaluated and investigations including CT and ultrasound abdomen revealed intestinal obstruction. Emergency exploratory laparotomy revealed an ileo-colo-colic intussusception which was resected and right hemicolectomy and ileo transverse colic anastomosis was done. Intussusception is a common abdominal emergency in paediatric age group. Occurrence of intussusception in an adult patient always should give rise to suspicion about an underlying sinister pathology. Commonest variant of intussusception is an ileo-colic type. Ileo-colo-colic intussusception is one of the rarest variants with an incidence of less than 0.5%.

**Keywords:** Intussusception, Intestinal obstruction, Hemicolectomy, Anastomosis

Date of Submission: 03-01-2018

Date of acceptance: 20-01-2018

### I. Introduction

Intussusception Is Telescoping Or Invagination Of A Segment Of Bowel into the segment adjacent to it. It is common in paediatric age group. When it occurs in adults a sinister pathology must always be ruled out.

### II. Case Report

A 49 year old female, native of Tirunelveli, a home maker, admitted on 28.5.2017, with complaints of abdominal pain on and off for 1 month duration associated with vomiting, blood in stools and abdominal distension of 1 day duration. Abdominal pain was insidious in onset and colicky in nature and aggravated on the day of admission. . There was no radiation/ postural variation/ relation to food intake. The abdominal distension was also of 1 day duration which was progressively increasing since the morning. Vomiting since morning – which was non projectile, non bilious, Vomitus contained food particles, no hematemesis or malena. Also gives a h/o blood and mucus in stools in the morning. The patient did not have any other known co-morbidity. No history of any previous surgeries. On examination, the patient was in shock. Abdomen was distended. Tenderness present over the umbilical region and a mass of size 5x5 cm felt over the umbilical region .bowel sounds were absent. Per rectal examination showed roomy rectum and absent faecal staining. Her blood investigations were within normal limits. CT abdomen showed a large colo-colic intussusception in proximal transverse colon. Ultrasound of the abdomen showed presence of minimal free fluid. Patient was resuscitated and emergency exploratory laparotomy was performed. Abdomen was opened by midline incision and thorough laparotomy was done. It revealed an Ileo-Colo-Colic intussusception and the rest of the bowel was normal. Resection of the involved segment and an end to side ileo transverse anastomosis was done in 2 layers with inner 2-0 vicryl and outer 2-0 silk. Patient was managed with higher antibiotics, Total parenteral nutrition and supportives. Post op was uneventful and patient recovered well to be discharged on 14<sup>th</sup> post op day.

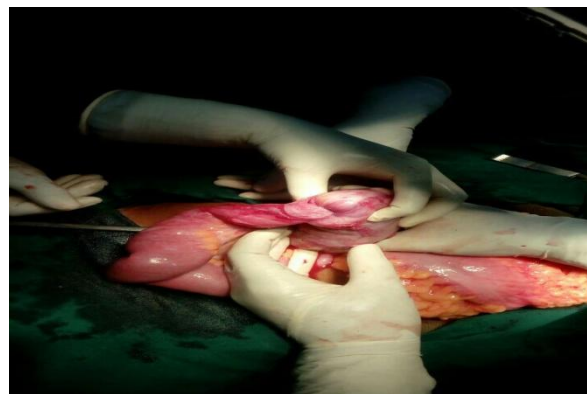
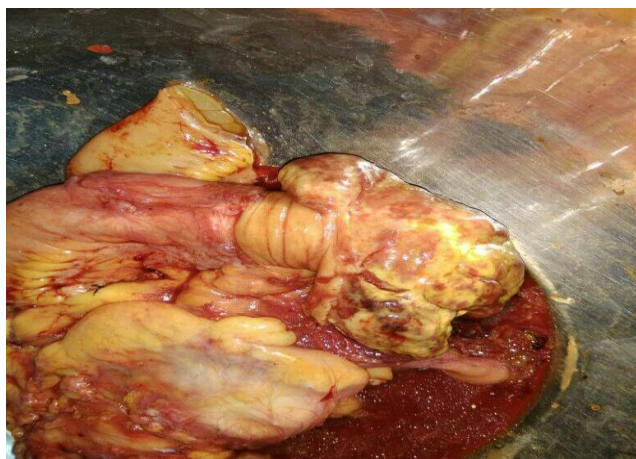

Figure 1 – Ileo-colo-colic intussusceptions



**Figure 2** – Resected specimen

## **2. Post op hpe**

Suggestive of Non Hodgkin's lymphoma large cell type, resected margins free of tumor.

## **III. Discussion**

Intussusception is telescoping or invagination of a segment of bowel into the segment adjacent to it. It was first reported by Barbette and further detailed description given by John Hunter<sup>4</sup> in 1789. Sir Jonathan Hutchinson was the first to operate on a child with intussusception<sup>5</sup> in 1871. It is common in paediatric age group<sup>1</sup>. When it occurs in adults a sinister pathology must always be ruled out. Types of intussusception: Ante grade type being the most common retrograde type is rare. Based on the bowel involved, there are four types, which includes ileo colic, colo colic, ileo-ileo- colic, ileo-colo-colic (very rare). The causes include

1. Change in diet during weaning
2. URTI
3. Intestinal polyps
4. Submucous lipoma
5. Leiomyoma of intestine
6. Meckel's diverticulum
7. Carcinoma

It is very common in paediatric age group, especially around weaning period. Intussusception is the most common cause of intestinal obstruction in paediatric age group<sup>1</sup>. Ileo-colic is the most common type. It is rare in elderly age group, usually apex is formed by a growth and here colo-colic is the most common type. Clinical features include – colicky abdominal pain, sausage shaped mass of intussusception and also passage of red currant jelly stools. Features of obstruction and peritonitis occur progressively.

Ultrasound will reveal target sign<sup>2</sup> or pseudo kidney sign and plain x-ray will reveal signs of intestinal obstruction. CT is a highly sensitive diagnostic tool for correct diagnosis of intussusception<sup>6</sup>. Contrast x-ray will reveal claw or pincer sign.

Treatment of intussusception includes:

1. Resuscitation
2. Iv fluids, Ryle's tube, antibiotics
3. Definitive treatment

### **3.1 Non operative – Hydro reduction**

### **3.2 Operative - laparotomy and proceed**

1. Manual reduction – milking out
2. Resection and anastomosis if  
-Gangrenous

-Persisting for more than 48 hrs

### **3.3 Recurrence**

1. Hydro reduction – 10%
2. Open manual reduction – 2%
3. Resection - <1%

#### **IV. Conclusion**

Intussusception is a common occurrence in paediatric age group but can present as intestinal obstruction in adults as well where a sinister pathology like malignancy should always be suspected. Ileo-colo-colic intussusception is one of the rarest variants of intussusception. Hence this case is being reported for its rarity.

#### **References**

- [1]. Sabiston Textbook of Surgery The Biological Basis of Modern Surgical Practice, 20<sup>th</sup> edition 2016
- [2]. Bailey & Love's Short practice of Surgery, 26<sup>th</sup> Edition
- [3]. Maingot's Abdominal Operations 12<sup>th</sup> Edition.
- [4]. Noble I. Master surgeon: John Hunter. J.Messner: New York; 1971. P. 185.
- [5]. Hutchinson H, Hutchinson J. Jonathan Hutchinson, life and letters. 1<sup>st</sup> ed. Wm Heinemann Medical Books: London; 1946.
- [6]. Takeuchi K, Tsuzuki Y, Ando T, Sekihara M, Hara T, Kori T, Kuwano H. The diagnosis and treatment of adult intussusception. J Clin Gastroenterol. 2003;36:18-21.

Dr. Ajay Abraham."A Rare Case of Ileo-Colo-Colic Intussusception in An Adult."IOSR Journal of Dental and Medical Sciences (IOSR-JDMS), vol. 17, no. 1, 2018, pp. 04-06