

## A Case of Unicornuate Uterus Accidentally Discovered During Caesarean delivery

Mst. Moonmoon Begum<sup>1</sup>, Md. Taifur Rahman<sup>2</sup>

1. \*Dr. Mst. Moonmoon Begum, Junior Consultant, Gynae and obstetrics, 100 bedded Hospital, Saidpur, Nilphamari.

2. Dr. Md. Taifur Rahman, Junior Consultant, Anaesthesiology, 100 bedded Hospital, Saidpur, Nilphamari.  
Corresponding Author: Mst. Moonmoon Begum

**Abstract:** Mullerian duct anomalies (MDAs) are congenital defects of the female genital tract that arise from abnormal embryological development of the Mullerian ducts. Unicornuate uterus with or without rudimentary horn is developmental anomaly which occurs due to abnormal or failed development of one of the paired mullerian duct or fusion of the ducts. Women with unicornuate uterus have increased incidence of obstetric complications like spontaneous abortions, preterm delivery and intrauterine foetal demise and gynaecological complications like infertility, endometriosis and dysmenorrhoea. A 25 years old, primigravida was admitted at her 40weeks 3 days gestational age with complaints of less fetal movement and history of subfertility. She was induced with tab Misoprostol but failure of induction occurred. She underwent caesarean section and intra-operatively she was incidentally found to have unicornuate uterus with no rudimentary horn and absence of right sided fallopian tube and ovary. The baby cried immediately after birth and was healthy weighing 3.2 kg. If pregnancy with unicornuate uterus is managed well, it can result in favourable obstetric outcome.

**Keywords:** Caesarean section, unicornuate uterus

Date Of Submission: 28-09-2018

Date of acceptance: 13-10-2018

### I. Introduction

Congenital uterine anomalies result from an abnormal formation, fusion or reabsorption of Mullerian ducts during fetal life. These anomalies can be found in 1 to 10% of the unselected population, 2 to 8% of infertile women and 5 to 30% of women with a history of miscarriages (1) A unicornuate uterus also called as Class IV congenital uterine anomaly constitutes a unilaterally formed uterus; it may have a communicating or non-communicating horn with cavity (IVa), or a horn without a cavity or aplasia (IVb) (2). Unicornuate uterus is significantly more common in infertile women and also may lead to obstetrical problems such as infertility, ectopic pregnancy, abortion, preterm delivery, intrauterine fetal demise, prematurity, fetal growth retardation, malpresentation (3-12). However successful pregnancies have been rarely encountered. We present a patient who had successful delivery inspite of having a unicornuate uterus with no horn.

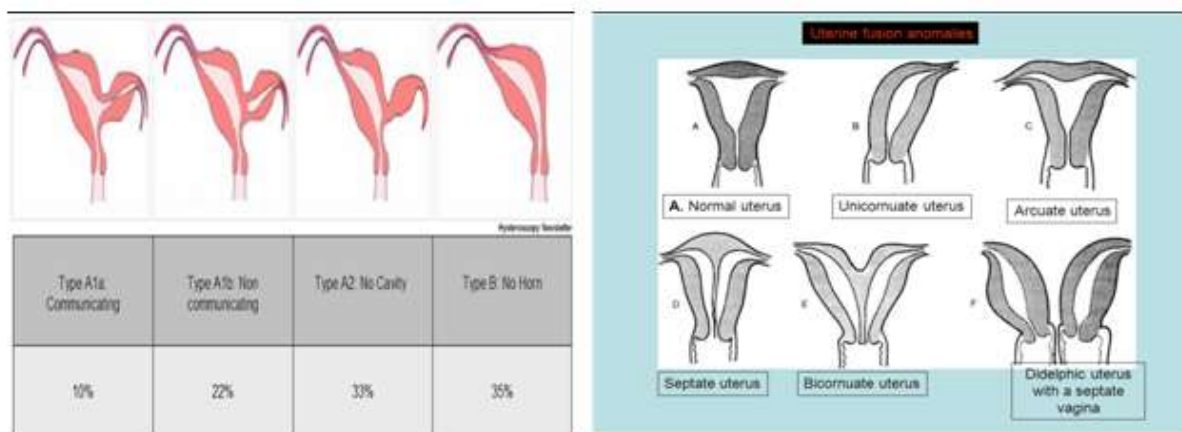


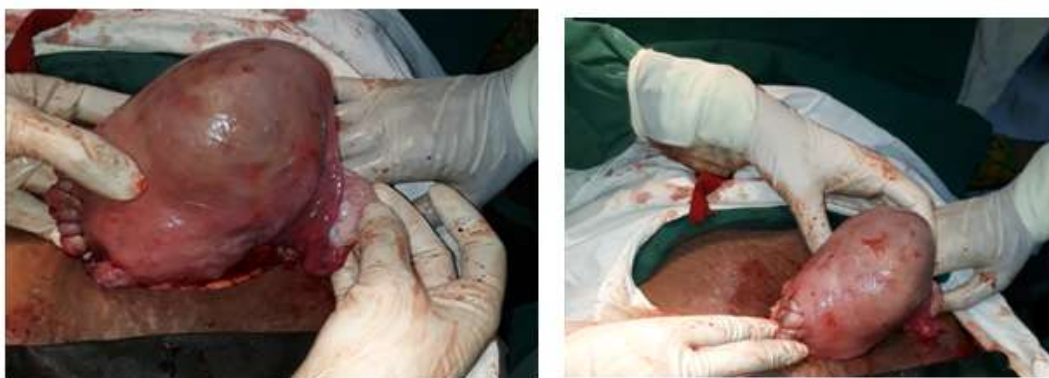Figure 1 : Classification of unicornuate uterus

### Case Report

A 25 years old, primigravida, underwent her ANC elsewhere admitted to the labour ward, 100 bedded Hospital Saidpur, Nilphamari at her 40 weeks 3 days gestational age with complaints of less fetal movement and history of subfertility for 5 years. She did not have any prior ultrasonography reports with her.

On admission, she was healthy and her vital signs were within normal limits. Examination of her abdomen was suggestive of term pregnancy, fetal heart rate was 146 beats per minute, liquor seemed to be adequate, presentation was cephalic. On per vaginal examination, cervix was unfavourable for vaginal delivery. Her routine blood and urine investigations were within normal limits.

She was induced with tab. Misoprostol per vaginally but there was failure of induction. She was taken up for caesarean section and intra-operatively she was incidentally found to have unicornuate uterus with no rudimentary horn and contralateral fallopian tube and ovary was absent (Figure 2). The baby cried immediately after birth, having birth weight - 3.2 kg with no gross congenital anomalies. She did not have any post-partum haemorrhage and the uterus was closed in one layer. Abdomen was closed in layers. She had an uneventful post-operative recovery and was discharged from the hospital on post-operative day 4.



**Figure 2 : Per-operative view of unicornuate uterus. Presence of single product.**

## **II. Discussion**

Unicornuate uterus with no rudimentary horn is a rare congenital uterine malformation. It may lead to gynecologic problems, infertility and adverse obstetrical outcomes (3,5,6). Reichman et al. published rates of 51.5% live birth in women with unicornuate uterus (3). Wang et al. presented 26 cases of rudimentary horn of uterus, four of which (15%) had become pregnant, and one of which (4%) had been presented with ipsilateral oviduct ectopic pregnancy (7). Heinonen mentioned 93 pregnancies and only two of them had term delivery. The fetal survival rate was 61% in the series of Nathan (8). Fox et al. suggested that the risk of adverse pregnancy outcomes was increased in patients with uterine unicornis and the rate of preterm birth < 37 weeks was 50 % (9).

Even though the obstetrical outcome is usually poor, there are some case reports that present successful pregnancies. Nahra-Lynch et al. reported a woman with known unicornuate uterus. This patient became pregnant with twins after controlled ovarian hyperstimulation and intrauterine insemination but she had some obstetrical problems (10). Also Gerris et al. reported successful triplet pregnancy in a patient with a unicornuate uterus with a cavitory communicating rudimentary horn (11). Caserta et al. reported a 39 weeks and 4 days pregnancy after which they had a healthy baby via caesarean section. (12)

Furthermore another case report presented a full-term pregnancy in an undeveloped auxiliary horn of uterus unicornis (13). It is remarkable that all these aforesaid case reports present patients with only one pregnancy.

This is a rare and interesting clinical example of patient who had uneventful pregnancy despite having a unicornuate uterus which carries a significant risk of infertility and adverse pregnancy outcomes.

## **III. Conclusion**

As a contribution to the literature, we have a case report of a patient with unicornuate uterus with no rudimentary horn and absence of contralateral fallopian tube and ovary. Thus, a very important message both for doctors and anxious patients with unicornuate uterus, is that with good monitoring and timely interventions, the fetomaternal outcome is not always adverse.

## **References**

- [1]. Chan YY, Jayaprakasan K, Tan A, Thornton JG, Coomarasamy A, Raine-Fenning NJ: Reproductive outcomes in women with congenital uterine anomalies: a systematic review. *Ultrasound Obstet Gynecol* 2011, 38:371–382.
- [2]. Grimbizis GF, Campo R. On behalf of the Scientific Committee of the Congenital Uterine Malformations (CONUTA) common ESHRE/ESGE working group, Gordts S, Brucker S, Gergolet M, Tanos V, Li T-C, De Angelis C, Di Spiezio Sardo A: Clinical approach for the classification of congenital uterine malformations. *Gynecol Surg* 2012, 9:119–129.
- [3]. Reichman D, Laufer MR, Robinson BK. Pregnancy outcomes in unicornuate uteri: a review. *Fertil Steril* 2009 91(5):1886-94.
- [4]. Hua M, Odibo AO, Longman RE, Macones GA, Roehl KA, Cahill AG. Congenital uterine anomalies and adverse pregnancy outcomes. *Am J Obstet Gynecol* 2011; 205:558.e1-5.
- [5]. Fedele L, Zamberletti D, Vercellini P, Dorta M, Candiani GB. Reproductive performance of women with unicornuate uterus. *Fertil Steril* 1987; 47(3):416-9.
- [6]. Akar ME, Bayar D, Yildiz S, Ozel M, Yilmaz Z. Reproductive outcome of women with unicornuate uterus. *Aust N Z J Obstet Gynaecol* 2005;45(2):148-50.
- [7]. Wang SJ, Oli M, Jinag L, Wang JL, Wei LH. Clinical analysis of 225 women with congenital uterine malformation. *Zhonghua Fu Chan Ke Za Zhi*. 2008;43(7):493-6.
- [8]. Heinonen PK. Unicornuate uterus and rudimentary horn. *Fertil Steril* 1997;68(2):224-30.
- [9]. Nathan S, Fox, Ashley S, Roman, Erica M, Stern, Rachel S, Gerber, Daniel H, Saltzman & Andrei Rebarber. Type of congenital uterine anomaly and adverse pregnancy outcomes. *The Journal of Maternal-Fetal & Neonatal Medicine*, 27:9, 949-953.
- [10]. Nahra-Lynch M, Toffle RC. Multiple gestation in a unicornuate uterus. A case report. *J Reprod Med*. 1997;42(7):451-4.
- [11]. Gerris J, Eulaers E, Joostens M, Jacquemyn Y, Loquet P, Verdonk P, Buytaert P. Successful triplet pregnancy in a patient with a unicornuate uterus with a cavitary communicating rudimentary horn. *Hum Reprod* 1993; 8(2):338-41.
- [12]. Caserta D, Mallozzi M, Meldolesi C, Bianchi P, Moscarini M. Pregnancy in a unicornuate uterus: a case report. *Journal of Medical Case Reports* 2014; 8:130.
- [13]. Domanski S. Full-term pregnancy in undeveloped auxiliary horn of uterus unicornis. *Ginekol Pol*. 1957; 28(2):139-42.

Mst. Moonmoon Begum" A Case of Unicornuate Uterus Accidentally Discovered During Caesarean delivery" *IOSR Journal of Dental and Medical Sciences (IOSR-JDMS)*, vol. 17, no. 10, 2018, pp 88-90.