

Socio Cultural Hurdles in Late Presentation of Primary Amenorrhoea Case Report

Dr. Abirami.E¹, Dr. Vidhya²

¹Postgraduate, Dept of Obstetrics and Gynecology, Sree Balaji Medical College & Hospital, Chennai, India.

²Assistant Professor Sree Balaji Medical College & Hospital, Chennai, India.

Corresponding Author: Dr. Abirami.E

Abstract:

This is the report of a late presentation of case of MRKH at 27yrs with coital difficulty.

Some of the reasons for late diagnosis of such cases in the face of advanced medical and scientific technology are

- ✓ Social stigma
- ✓ Lack of awareness
- ✓ Lack of family support

Since this condition affects physical, mental, and social well being of the individual, the treatment should begin from early diagnosis and disability limitation.

Keywords: Rokitansky syndrome, Mullerian duct, Karyotype, Primary Amenorrhea.

Date of Submission: 23-05-2018

Date of acceptance: 05-06-2018

I. Introduction:

Mayer-Rokitansky-Kustner-Hauser Syndrome is the second most common cause of primary amenorrhoea. MRKH Syndrome affects at least 1 out of 4500 women and has for a long time been considered as a sporadic anomaly. The syndrome is characterized by aplasia of the Müllerian duct (uterus and upper two-thirds of the vagina). In addition, it is often found associated with unilateral renal agenesis or dysplasia as well as skeletal malformations (MURCS association). Women will have karyotype 46, XX with female phenotype characteristics. The MRKH syndrome, when described in familial aggregates, seems to be transmitted as an autosomal dominant trait with an incomplete degree of penetrance and variable expressivity.

The normal development of the female reproductive tract depends on the interaction between genetic, hormonal and environmental factors for the differentiation of the Müllerian and Wolffian ducts, and the urogenital sinus. Changing these factors can result in a wide spectrum of abnormalities of the reproductive tract, including imperforate hymen, vaginal agenesis or atresia, incomplete fusion of the Müllerian ducts and Müllerian aplasia.

Congenital malformations of female genitalia are often a challenge for doctors, in both diagnosis and management.

II. Case Report:

27yrs old female, newly married, presented with complaints of coital difficulty. On detailed history patient revealed the fact that she has not attained menarche. No family history of primary amenorrhoea or late menarche in the family. She was not aware of the fact that this condition needs medical attention since she was living only with her aged grandmother, who was a daily wage earner and illiterate, and so the problem of primary amenorrhoea was ignored. She got married without revealing this fact to the partner and presented to our OPD with coital difficulty.

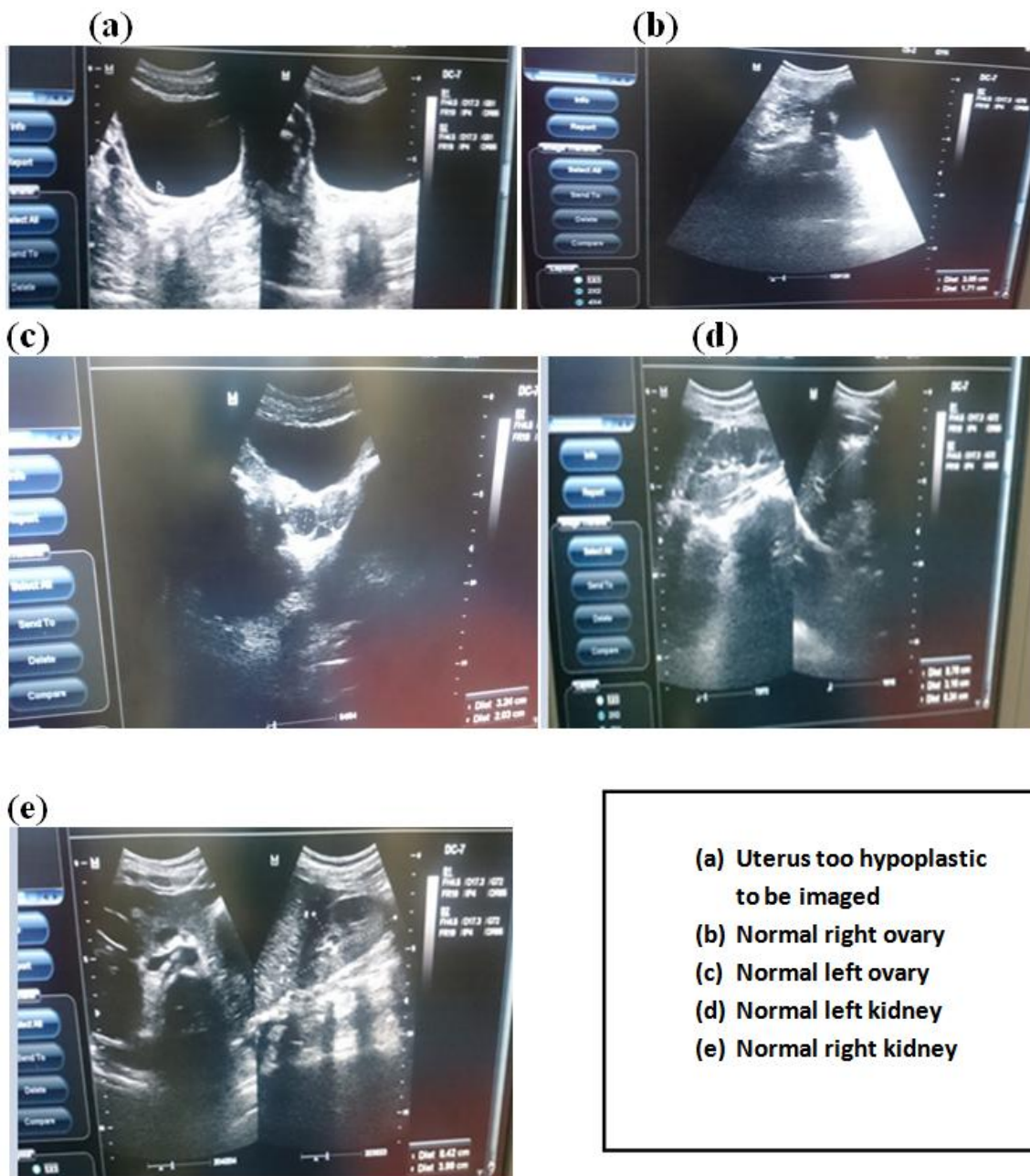
General Examination, She has normal breast development with Tanner stage 4, her body hair distribution was normal, including pubic hair –Tanner stage 4, and normal axillary hair. Her height was 160cm and weight of 55kg, and normal arm span. There is no skeletal abnormality.

Local Examination: Inguinal region was normal. External genitalia was normal and well estrogenized. Speculum examination was not possible.

PV Examination: Blind vaginal pouch of 2cm length.

Per Rectal Examination: uterus could not be palpated

An ultrasound of the abdomen and pelvis showed a too hypoplastic uterus to be imaged. Both ovaries were normal in size and appearance. Both kidneys were normal .



PROVISIONAL DIAGNOSIS:

MAYER ROKITANSKY KUSTER HAUSER SYNDROME

This provisional diagnosis was confirmed by following investigations:

HORMONAL PROFILE:

- Follicular stimulating hormone (FSH),
- Luteinizing hormone (LH),
- Estradiol, and
- 17-hydroxyprogesterone, were normal, indicating normal hypothalamic-pituitary-ovarian axis.

KARYOTYPING: showed normal (46, XX) female karyotype. This differentiates MRKH syndrome from other genital tract development defects such as Turner syndrome (45,XO) and androgen insensitivity syndrome (46, XY).

MANAGEMENT:

She was explained about her condition and pretreatment counselling was given. The couple were psychologically affected, knowing that pregnancy was not possible in her condition. They requested not to disclose her condition to other family members.

Treatment options were explained to the patient and informed consent was obtained. Accordingly **McIndoe vaginoplasty** was done and thereby giving a solution for the coital difficulty. She was given the options like surrogacy and adoption which will fulfill their ambition of having a child.

III. Discussion:

A case of MRKH syndrome presents as primary amenorrhoea with normal secondary sexual characteristics and a blind vagina.

MRKH syndrome is characterized by aplasia of the Mullerian duct (uterus and upper two-thirds of the vagina) in a person who has karyotype 46 XX with female phenotype, characteristic of primary amenorrhea in adolescence. The lower third of the vagina, the ovaries and external genitalia in these cases usually do not have any abnormalities. 40-60% of patients have renal disorders such as unilateral agenesis, horseshoe kidney, ectopic or bilateral ureteropelvic obstruction. In addition, 20% have bone changes, thoracocervical asymmetry, spinal fusion, scoliosis or Klippel-Feil syndrome. Cardiac abnormalities and hearing defects can also be countered. Occurring less frequently, but also reported in the literature is bilateral femoral hypoplasia. Among the various proposed ratings, the MRKH syndrome maybe (according Oppelt et al):

a) **Typical MRKH:** Isolated uterovaginal aplasia or hypoplasia

b) **Atypical MRKH:** Incomplete aplasia (uterovaginal aplasia or hypoplasia) and/or associated with other malformations, is generally referred to as MURCS association (or type II MRKH)

➤ **MURCS association (Mullerian duct aplasia, Renal dysplasia and Cervical somite anomalies):** uterovaginal aplasia or hypoplasia + renal, skeletal, cardiac and digital anomalies.

In a meta-analysis of 521 cases of MRKH, Oppelt et al⁸ found that 64% of patients had the typical form, 24% atypical and 12% had MURCS syndrome.

Recently researchers have been attempting to identify novel causative genes of isolated Mayer-Rokitansky-Küster-Hauser (MRKH) syndrome using whole-exome sequencing (WES) together with single nucleotide polymorphism (SNP) array.

Treatment:

Treatment is usually delayed until the patient is ready to begin sexual activity, in fact, they are often associated with somatic and psychosocial disorders such as depression, requiring psychological monitoring. The restorative treatment may or may not be surgical, but the method chosen must be adapted to individual needs, the patient's motivation and available options.

Surgical technique:

- Frank technique or perineal dilation
- McIndoe technique
- Williams vaginoplasty
- Rotational flap procedures
- Intestinal neovagina
- Vecchietti technique

In developed countries a case of MRKH syndrome presents as primary amenorrhoea usually around the age of puberty because of awareness among the people. But in developing countries people lack such awareness because of poor education status and even a proportion of educated people do not come for medical help in these conditions due to social stigma attached to it.

In a study Strubbe et al reported a mean age of 25yrs in Netherland. In this case the diagnosis was delayed till marriage due to ignorance of the woman and negligence from care taker. A case has been reported by Abdel Fattah MS et al where in the diagnosis of MRKH syndrome was made only after menopause.

As the condition has significant effect on the mental well being of the individual, the treatment should also focus on ameliorating the psychological stress. Adequate and timely counselling along with medical interference can help females to overcome the psychological stress associated with this condition.

IV. Conclusion:

Sad part of her...!!

I thought

I am a girl.....

But the thought remained

as a thought

In my life.....

In our country social stigma associated with discussing about menstrual complaints and seeking medical care for the same, Illiteracy and poverty can delay the diagnosis of MRKH syndrome in many women. With our social belief “ To marry is to procreate”, diagnosing MRKH syndrome at an earlier age can reduce the psychological stress associated with failed marriage.

References

- [1]. Guerrier D, Mouchel T, Pasquier L, Pellerin I (2006) The Mayer-Rokitansky- Küster-Hauser syndrome (congenital absence of uterus and vagina) – phenotypic manifestations and genetic approaches. *J Negat Results in Biomed* 5: 1.
- [2]. Cunha GB, Alencastro JB, Ferreira MS, Alvez CLN, Silveira PM (2006) Neovagina por Videolaparoscopia na Síndrome de Mayer-Rokitansky- Kuster-Hauser. *Rev Bras Videocir* 4: 183-188.
- [3]. Dornelas MT, Arruda FR, Anna LLS, Nett GM, Souza RG, et al. (2010) Reconstrução vaginal pelo retalho neurovascular podendo crural na síndrome de Rokitansky. *Rev Bras Cir Plást* 25: 525-531.
- [4]. Folch M, Pigem I, Konje JC (2000) Müllerian agenesis: etiology, diagnosis, and management. *Obstet Gynecol Surv* 55: 644-649.
- [5]. Sharma BB, Sharma S, Singh Y, Balesa J (2015) Mayer-Rokitansky-Kuster- Hauser Type I Syndrome – A Case Report. *Indian J Case Reports* 1: 8-10.
- [6]. Sultan C, Biason-Lauber A, Philibert P (2009) Mayer-Rokitansky-Kuster- Hauser syndrome: Recent clinical and genetic findings. *Gynecol Endocrinol* 25: 8-11.
- [7]. Chandiramani M, Gardiner CA, Padfield CJ, Ikhen SE (2006) Mayer - Rokitansky - Kuster - Hauser syndrome. *J Obstet Gynaecol* 26: 603-606.
- [8]. Oppelt P, Renner SP, Kellerman A, Brucker S, Hauser GA, et al. (2006) Clinical aspects of Mayer-Rokitansky-Kuster-Hauser syndrome: recommendations for clinical diagnosis and staging. *Human Reprod* 21: 792-797.
- [9]. Chen MJ, Wei SY, Yang WS, Wu TT, Li HY, et al. (2015) Concurrent exometargeted next-generation sequencing and single nucleotide polymorphism array to identify the causative genetic aberrations of isolated Mayer- Rokitansky-Küster-Hauser syndrome. *Hum Reprod*.
- [10]. Aguilar AJ, Arias JAL, Ortega CDR (2010) Amenorrea primaria: A propósito de un caso com el síndrome de Mayer-Rokitansky-Küster-Hauser. *Revista Mexicana de Pediatría* 77: 123-127.
- [11]. Reis P, Sousa R, Pinto A, Leal C, Guimaraes JM (2014) Pregnancy in a case of Mayer-Rokitansky-Ku`ster-Hauser Syndrome – A Case Report. *Acta Obstet Ginecol Port* 8: 186-188.
- [12]. Brännström M, Johannesson L, Bokström H, Kvarnström N, Mölne J, et al. (2015)

Dr. Abirami.E "Socio Cultural Hurdles in Late Presentation of Primary Amenorrhoea Case Report." *IOSR Journal of Dental and Medical Sciences (IOSR-JDMS)*, vol. 17, no. 6, 2018, pp 31-34.