

## Efficacy of Lignocaine 2% Gel in Pterygium Surgery with Amniotic Membrane Graft

Dr. Sachin Daigavane<sup>1</sup>, Dr. Rohit Agrawal<sup>2</sup>  
Corresponding Author: Dr. Rohit Agrawal

---

**Abstract:****Aim:** The aim of this study is to study the effectiveness and efficacy of 2% lignocaine gel for anaesthesia in pterygium surgery combined with amniotic membrane graft. **Materials And Methods:** A prospective, interventional study, comprising of 30 patients (30 eyes) having nasal pterygium, was conducted at a tertiary eye care centre. Pterygium excision with amniotic membrane grafting was done under 2% lignocaine gel. Patient's intraoperative comfort, time of surgery, any complications and surgeon's comfort were noted. Patients were followed up for a period of 3 months for recurrence and graft displacement. **Results:** Thirty eyes of 30 consecutive patients including 17 males and 13 females were operated. No pain was noticed in 23 (76.6%) patients. Lid squeeze was present in 28 (93.3%) patients. 3 (10%) patients did not cooperate for surgery in topical anaesthesia, so sub-conjunctival anaesthesia was given. Recurrence was seen only in 2 (6.6%) patients after a follow up of 3 months. Graft displacement was seen in 2 (6.6%) patients on the 1<sup>st</sup> post-op day. **Conclusion:** By this study we conclude that use of lignocaine 2% jelly is an easy, effective and versatile method for pterygium surgery. Use of amniotic membrane graft along with lignocaine jelly further improves the outcome of the surgery.

---

Date of Submission: 10-07-2018

Date of acceptance: 27-07-2018

---

### I. Introduction

A pterygium (plural pterygia) is a triangular fibrovascular subepithelial ingrowth of degenerative bulbar conjunctival tissue over the limbus onto the cornea [1]. The major drawback associated with pterygium surgery is high recurrence rates (2.1%–87%) [2-3]. Various anaesthetic techniques have been tried to perform primary pterygium surgery. These include peribulbar, retro-bulbar block, anaesthesia, sub-conjunctival injection of 2% lignocaine hydrochloride and 2% lignocaine jelly. In ophthalmology, less invasive techniques such as sub-conjunctival, intracameral and topical anaesthesia are gaining in popularity. The role of lidocaine 2% gel has already been established in cataract and chalazion surgery. The potential role of this topical anaesthetic agent in pterygium surgery has not yet been established [4-5]. Several techniques have been tested to reduce the fibrovascular activity aiming to reduce the recurrence such as  $\beta$ -irradiation, conjunctival and limbal autografting, antimetabolic drugs, and amniotic membrane transplantation [6-7]. Amniotic membrane graft shows better result therefore we used amniotic membrane graft in our study. [8-9]

### II. Aims And Objectives:

The aim of this study is to study the effectiveness and efficacy of 2% lignocaine gel for anaesthesia in pterygium surgery combined with amniotic membrane graft.

### III. Material And Methods:

**Study Design-** Prospective Interventional Study

**Inclusion CRITERIA:**

1. Both sexes.
2. >18 years old
3. Primary pterygium > 2mm across corneal limbus [Measurement made from the imaginary line of surgical limbus to the most advance edge of the visible pterygium]
4. Informed consent for pterygium surgery under topical anaesthesia

**Exclusion Criteria:**

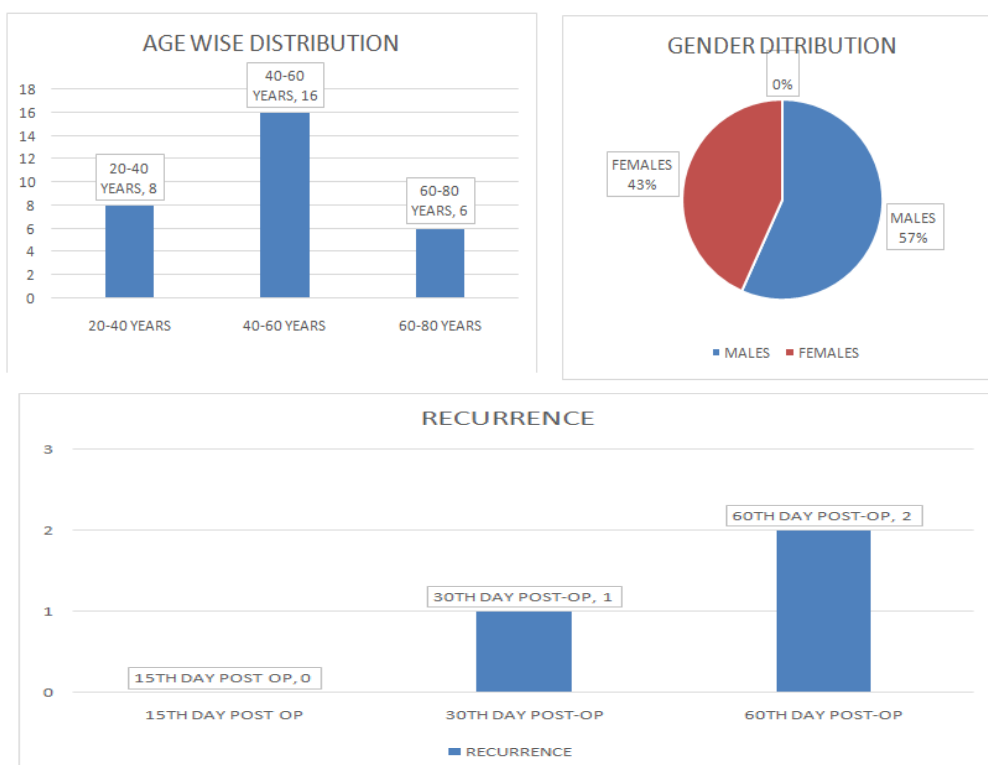
1. Temporal pterygium
2. Double headed pterygium
3. Previous ocular surgery in which conjunctival-limbal graft is not feasible
4. History of scleritis or autoimmune diseases

**Pre-Operative:** 30 patients with nasal pterygium and giving consent for the study were selected. Patients were examined for visual acuity, anterior segment evaluation on slit lamp, blood pressure, blood glucose levels and intra ocular pressure. Patients were explained the procedure of operation.

**Intra-Operative:** Patients were instilled with 2% lignocaine jelly and then surgery was started. Nasal pterygium was removed and cornea was cleared off of any remaining sub-conjunctival tissue. After cutting the nasal pterygium and preparing the bed for graft, size of the bed was measured using Vernier calliper. Amniotic membrane graft is cut of the size measured by Vernier calliper. Amniotic membrane graft was placed over the bare scleral bed and ironed properly. At the end of the surgery patient was padded for 12 hrs.

**Post-Operative:** On 1<sup>st</sup> day post-op patient was asked about any discomfort that he/she might have felt during the surgery. Position of graft is examined on slit lamp. Patient was followed up for 3 months on 15<sup>th</sup> day, 30<sup>th</sup> day and 60<sup>th</sup> day post-op.

#### IV. Observation & Results



The study included 30 eyes of 30 patients. There were 17 males (57%) and 13 females (43%). The mean age was  $47.2 \pm 7.1$ . Maximum patients were in age group of 40-60 years i.e. 16 patients (53.3%). All patients had nasal pterygium. No pain was noticed in 23 (76.6%) patients. Lid squeeze was present in 28 (93.3%) patients. 3 (10%) patients did not cooperate for surgery in topical anaesthesia, so sub-conjunctival anaesthesia was given. 2 months post-op only 2 out of 30 patients showed signs of recurrence, one of which had graft displacement on the 1<sup>st</sup> post-op day.

#### V. Discussion

Recurrence is a common concern after primary pterygium surgery. To overcome that we used amniotic membrane graft after pterygium excision. Our study showed that, preoperative instillation of 2% lignocaine jelly provided satisfactory patient comfort to conduct the safe removal of pterygium with amniotic membrane grafting. Oksuz and Tamer studied the role of lignocaine jelly in excision of primary pterygium with conjunctival auto-graft [10]. Mithalet al. have studied the role of lignocaine gel in the excision and glue- free conjunctival grafting in primary pterygium [11].

Use of 2% lignocaine jelly also reduced average surgical time. The major advantage of using topical anaesthesia was to bring the surgical site under microscope by verbal commands to the patient.

The major advantage of using amniotic membrane graft was there was no damage to superior conjunctiva, which could be of use in cases of glaucoma for trabeculectomy in future.

#### VI. Conclusion

The study result demonstrates pterygium surgery with amniotic membrane grafting can be performed under instillation of 2% lignocaine jelly preoperatively without compromising the outcome of the surgery. Use of lignocaine jelly avoid the complications associated with local anaesthetic such as retro-bulbar haemorrhage, globe rupture, chemosis, raised intraocular pressure and also systemic complications. Instillation of jelly is a painless process as compared to injecting the block in peri-bulbar area. Topical anaesthesia is patient friendly method of giving anaesthesia. Use amniotic membrane graft is advised as it has least chance of rejection or displacement and it is also cost effective.

#### **Bibliography-**

- [1]. Kanski's clinical ophthalmology 8<sup>th</sup> edition pg. no. 162-164
- [2]. Fernandes M, Sangwan VS, Bansal AK, Gangopadhyay N, Sridhar MS, Garg P, et al. Outcome of pterygium surgery: Analysis over 14 years. *Eye (Lond)* 2005; 19:1182- 90.
- [3]. Kurna SA, Altun A, Aksu B, Kurna R, Sengor T. Comparing treatment options of pterygium: Limbal sliding flaptransplantation, primary closing, and amniotic membrane grafting. *Eur J Ophthalmol* 2013; 23:480- 7.
- [4]. Osayande OO, Mahmoud AO, Bolaji BO. Comparison of topical lidocaine [2% gel] and injectable lidocaine [2% solution] for incision and curettage of chalazion in Ilorin, Nigeria. *Niger Postgrad Med J* 2010; 17:270- 6.
- [5]. Gupta SK, Kumar A, Agarwal S. Cataract surgery under topical anaesthesia using 2% lignocaine jelly and intracameral lignocaine: Is manual small incision cataract surgery comparable to clear corneal phacoemulsification? *Indian J Ophthalmol* 2010; 58:537- 40.
- [6]. Mohammed I. Treatment of pterygium. *Ann Afr Med* 2011; 10:197- 203.
- [7]. Shimazaki J, Kosaka K, Shimmura S, Tsubota K. Amniotic membrane transplantation with conjunctival auto graft for recurrent pterygium. *Ophthalmology* 2003; 110:119-24.
- [8]. Song YW, Yu AH, Cai XJ. Effectiveness of amniotic membrane transplantation combined with mitomycin C in the treatment of pterygium: A meta- analysis. *Int J Ophthalmol* 2010; 3:352- 5.
- [9]. Zheng K, Cai J, Jhanji V, Chen H. Comparison of pterygium recurrence rates after limbal conjunctival auto graft transplantation and other techniques: Meta- analysis. *Cornea* 2012; 31:1422- 7.
- [10]. Oksuz H, Tamer C. Efficacy of lidocaine 2% gel in pterygium surgery. *ActaOphthalmolScand* 2005; 83:206- 9.
- [11]. Mithal C, Agarwal P, Mithal N. Pterygium surgery with conjunctival limbal autograft with fibrin glue under topical anaesthesia with lignocaine 2% jelly. *Nepal J Ophthalmol* 2011; 3:151- 4.

Dr. Sachin Daigavane "Efficacy of Lignocaine 2% Gel in Pterygium Surgery with Amniotic Membrane Graft" *IOSR Journal of Dental and Medical Sciences (IOSR-JDMS)*, vol. 17, no. 7, 2018, pp 22-24