

## “A Study on Morphological Variations of Thyroid Gland”

Dr.P.Surya Venkata Narayana<sup>1</sup>,Dr.C.B.Nisha Parveen<sup>2</sup>, Dr.M.V.R. Mayuri<sup>3</sup>,  
Dr.K.Deva Priyanka<sup>4</sup>

<sup>1</sup>Assistant professor, Dept. of Anatomy,S.V.Medical college ,Tirupati,A.P,India,NTR UHS

<sup>2</sup>Assistant Professor, Dept. of Anatomy,S.V.Medical college ,Tirupati,A.P,India,NTR UHS.

<sup>3</sup>Post graduate, Dept. of Anatomy,S.V.Medical college ,Tirupati,A.P,India,NTR UHS

<sup>4</sup>Senior Resident, Dept. of Anatomy,S.V.Medical college ,Tirupati,A.P,India,NTR UHS

Corresponding Author: Dr.C.B.Nisha Parveen

**Abstract:**Thyroid gland is highly vascular, ductless gland that clasps the upper part of the trachea. It extends from the fifth or sixth tracheal ring to the oblique line on the thyroid cartilage, and is enclosed in a sheath of pretracheal fascia attached to that line and to the arch of the cricoid cartilage. The gland varies greatly in size, and is relatively larger in women and children than in men.[1]**Method :** The present study was carried out in 25 adult cadavers. The midline structures of the neck were dissected in layers and finally thyroid gland was exposed by separating the strap muscles. The gland was examined morphologically and looked for variations. Photographs were taken and later the results were statistically analyzed. **Results:** Levator glandulae thyroideae, pyramidal lobe, absence of isthmus were noted in the present study

**Key words :** LGT (levator glandulae thyroideae), Pyramidal lobe, Isthmus, Hyoid bone.

Date of Submission: 10-07-2018

Date of acceptance: 27-07-2018

### I. Introduction

The Thyroid gland, brownish-red and highly vascular, is placed anteriorly in the lower neck, extending from fifth cervical to the first thoracic vertebrae. It is ensheathed by the pretracheal layer of deep cervical fascia and consists of right and left lobes connected by a narrow, median isthmus. The gland is slightly heavier in females and enlarges during menstruation and pregnancy.[2]

The thyroid gland is the first endocrine gland to start developing in the embryo. It is well known for its developmental anomalies which include persistence of the pyramidal lobe, thyroglossal cysts, agenesis of the thyroid gland, agenesis of the isthmus alone, aberrant thyroid gland, etc [3,4]. A small portion of gland substance often projects upwards from the isthmus, generally to the left side of the median plane, as the pyramidal lobe, representing development of glandular tissue from the caudal end of the thyroglossal duct. It may be attached to the inferior border of the hyoid bone by fibrous band, sometimes containing muscle fibers which is named as Levator Glandulae Thyroideae (LGT) and are innervated by branch of external laryngeal nerve. Separate small masses of thyroid tissue (accessory thyroid glands) are commonly found near the hyoid bone, in the tongue, in the superior mediastinum, or anywhere along the path of the descent of the thyroglossal duct, though their presence may only be revealed by histological study.[5]

The pyramidal lobe and the Levator Glandulae Thyroideae (LGT) develop from the remnant of the epithelium and connective tissue of thyroglossal duct [6].

Levator glandulae thyroideae is said to represent the detached part of infrahyoid muscles and it may be innervated by a twig from Ansa cervicalis.[7]

The anomalies of the development of the thyroid gland distort the morphology of the gland, and may cause clinical functional disorders and various thyroid illnesses. The knowledge of various developmental anomalies of the gland and variation in neurovascular relations will benefit the surgeon in better planning of safe and effective surgery. Aim of the present study was to look for various anomalies of the thyroid gland.

### II. Material&Methods

The present study was carried out in 25 adult cadavers in the department of Anatomy, Sri Venkateswara Medical College, Tirupati during routine dissection for MBBS students.

As per Cunningham's Dissection Manual, the midline structures of the neck were dissected in layers and finally Thyroid gland was exposed by separating the strap muscles. Then the gland was examined morphologically and for variations. Photographs were taken and later the results were statistically analyzed.

### **III. Observation**

Out of 25 cadavers (19 male ,6 female) in the present study 3 cadavers showed the presence of Levator Glandulae Thyroideae, 2 cadavers showed pyramidal lobe and 1 cadaver showed absence of isthmus.

Out of three cadavers (2 male ,1 female) possessing levator glandulae thyroideae , one male cadaver aged about 50 yrs showed presence of Levator Glandulae Thyroideae , lower end was attached to the Pyramidal lobe arising from the isthmus and the other end is attached to the lower border of the body of Hyoid bone. (Fig.1).

In another female cadaver aged around 45 yrs ,Levator Glandulae Thyroideae was found extending between the middle of isthmus traversing along the midline of the neck to the lower border of the body of Hyoid bone. Another feature noted in this cadaver was that the Levator Glandulae Thyroideae along its entire extension is made up of muscle fibers (Fig.2).

In another male cadaver aged about 60yrs , Levator Glandulae Thyroideae was found extending between the middle of isthmus traversing along the midline of the neck to the lower border of the body of Hyoid bone (Fig.3).

Pyramidal lobe was seen in one female cadaver aged about 55 yrs which is arising as a small projection from isthmus, not extending as levator glandulae thyroideae and in another cadaver pyramidal lobe was arising from the right lobe of the thyroid gland and extending as levator glandulae thyroideae (Fig.1) .

Absence of isthmus was noted in female cadaver aged about 50yrs .The thyroid gland had two separate lobes, with complete agenesis of isthmus. The two lobes are close to each other. (Fig.4) The individual lobes were supplied by branches of superior and inferior thyroid arteries. No accessory thyroid arteries were present.

### **IV. Discussion**

Views given by various authors regarding the morphology of Thyroid gland and its anomalies with Levator Glandulae Thyroideae in particular, provokes much interest. By fourth week of development [On Day 24] during embryonic period the thyroid gland appears first as a median thickening, which is soon converted into a solid cellular cord-like structure between the 1st and 2nd Pharyngeal pouches and is named the so called ‘Thyroglossal duct’. The lower end of the duct bifurcates and forms Right and Left lobes which is later united by a bridge crossing the midline called as ‘Isthmus’, and simultaneously the upper end degenerates [8].

The presence of LGT is independent of the presence or absence of a pyramidal process(Gardner et al,1975;Von lanz and Wachsmuth,1982,Romanes,1981)[9,10,11]. In the present study, there were 3 LGT out of them 2 extending from the isthmus to hyoid bone and another extending from a small pyramidal lobe . The incidence of LGT was 19.6% & 7.31% in studies conducted by Hussein Muktyaz et al. , & Daksha dixit et al .,[12,13] respectively which correlates with the present study (12%) . The incidence was high in the studies of Veena et al. ,(30%) Ranade et al.,(49.5%),Sultana et al. ,(43%),Savitha et al., (41.57%)[14,15,16]

The pyramidal lobe (PL) should be looked for, while thyroidectomy and removed, as failure of its identification can result in incomplete resection of thyroid gland [18]. Pyramidal lobe course can be from the isthmus,or the left or right lobe of thyroid , upwards in the form of a short stump or a long process that can reach the upper border of the thyroid cartilage or even the hyoid bone . Since Laloutte gave this entity its name in 1789, also called as Laloutte’s lobe [19].

The incidence of the Pyramidal Lobe varies between 7% to 77% as cited by Gupta R and Singla RK [20]. Daksha dixit et al [13] study showed the incidence of pyramidal lobe as 7.31% which correlates with the present study (8%). The incidence was high in the studies of Won & Chung et al., (78.8%) , Ranade et al., (58%), Bran et al., (55%), Hussein et al., (41%), Sultana et al., (50%). [21,15,22,12,16].

Pastor et al., (2006) [23] defined the agenesis of the thyroid isthmus as the complete and congenital absence of the thyroid isthmus. The isthmus may be missing in the amphibians, birds and among mammals - monotremes, certain marsupials, cetaceans, carnivores and rodents. In rhesus monkey (*Macacus rhesus*) thyroid gland is normal in position but there is no isthmus.(24) A comparative study of anatomy suggests that isthmus connecting the two lobes appeared during the course of evolution. The morphological difference in the evolutionary origin does not result in any changes in the thyroid function.[23]

Won and Chung have reported that in 3% of the cases studied, the isthmus was absent and the lateral lobes of the thyroid were separated [21]. According to Gruber (quoted by Testus and Latarjet) the incidence of agenesis of isthmus is about 5% [4]. ) while according to Marshall, it is about 10%.[3]. Shankar et al., and pastor et al., reported agenesis of thyroid gland in 1 case[25,23] . In the present study it was about 4% which correlates with the above studies. Incidence of absence of isthmus was higher in studies conducted by Saheli Zannath Sultana et al.,& Ranade et al.,which was reported as 31.66% & 33% respectively. [16,15]

**Table 1: Showing Incidence of absence of isthmus in various studies**

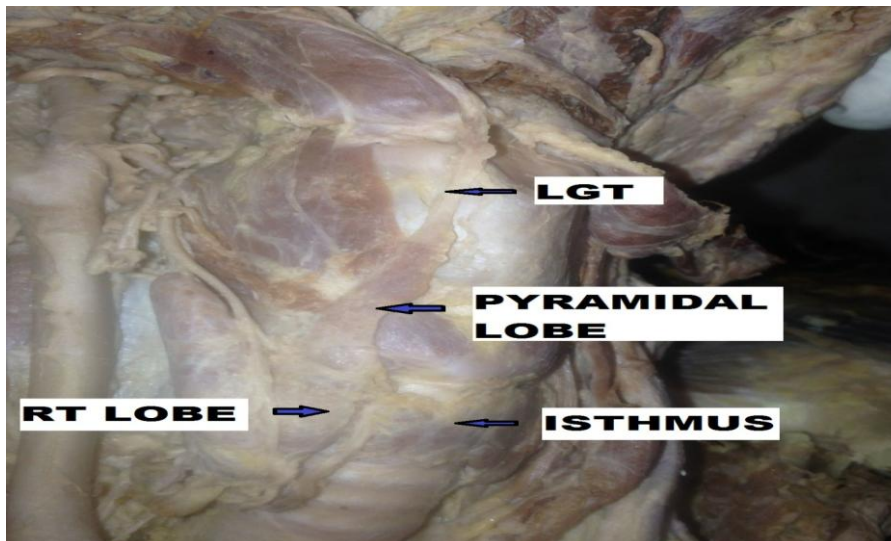
S.no	Author & year	Percentage (%)
1	Ranade (2008)	33%
2	Dixit (2009)	14.6%
3	Veena kulkarni (2012)	10%
4	Hussein mukyaz (2013)	12.5%
5	Savitha (2014)	9%
6	Sharada Guptha (2015)[26]	16.2%
7	Present study (2018)	4%

### V. Conclusion

The knowledge of the various developmental anomalies of the thyroid gland and the variations in the neurovascular relations will help the surgeons in the better planning of a safe and effective surgery. Imaging of pyramidal lobe preoperatively especially in patients requiring total thyroidectomy would facilitate the treatment and monitoring of patient by decreasing relapses that may occur at a later time.

Thyroid isthmus agenesis does not cause clinical symptoms by itself and often the diagnosis is purely incidental due to the existence of other thyroid pathology. While planning for thyroidectomy one should be prepared to find such variations like absence of isthmus or ectopic thyroid tissue around the normally located thyroid gland and also has to be precise in dissection as important nerves and vessels lie in vicinity of thyroid gland.

Tracheostomy can be potentially dangerous in cases such as in securing invasive airway during emergencies if a pre-procedure examination is not carried out. Therefore, a thorough knowledge of the thyroid anatomy and its associated anatomical variations is very important for the clinicians so as to avoid undue complications pre and post operatively .



**Fig:1 Showing pyramidal lobe and LGT (levator glandulae thyroideae)**

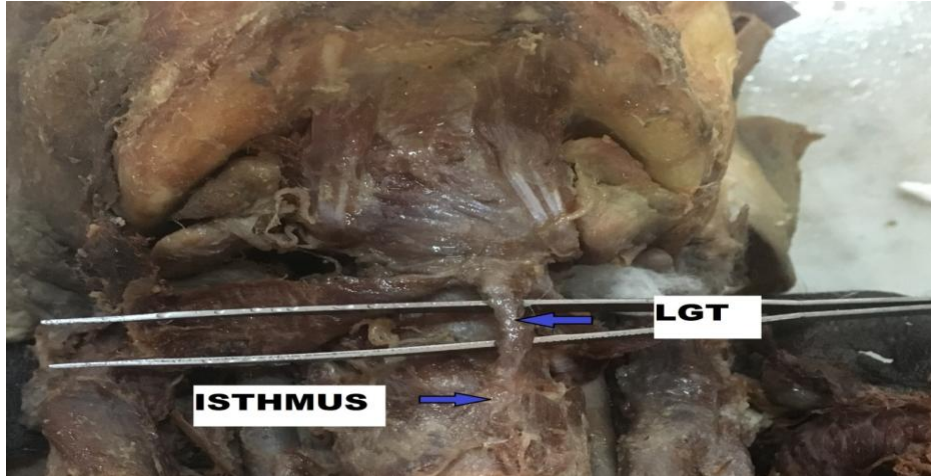


Fig:2 Showing LGT (levator glandular thyroideae ) which is entirely made up of muscle fibers

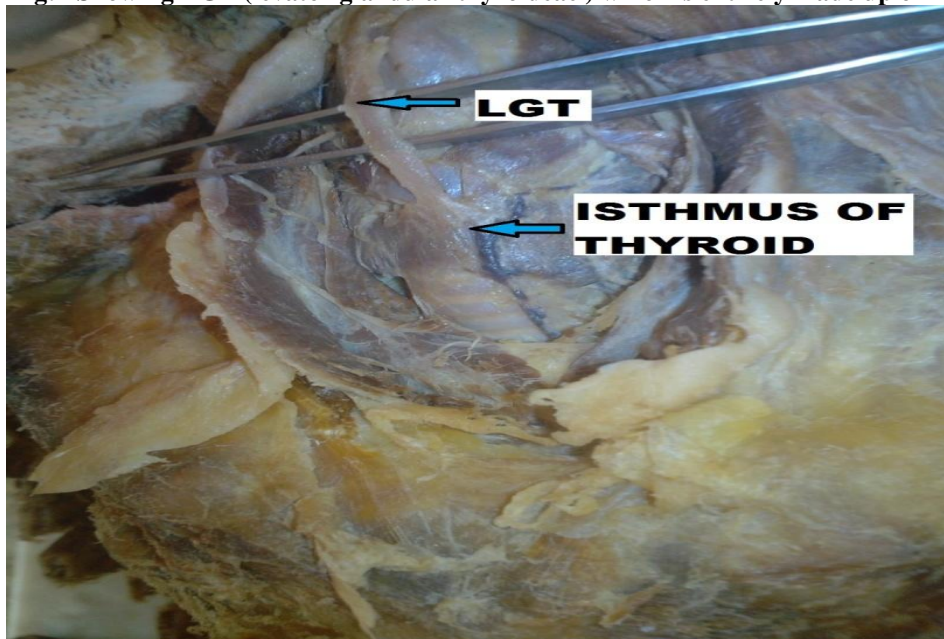


Fig:3 Showing presence of LGT (levator glandulae thyroideae) arising from isthmus

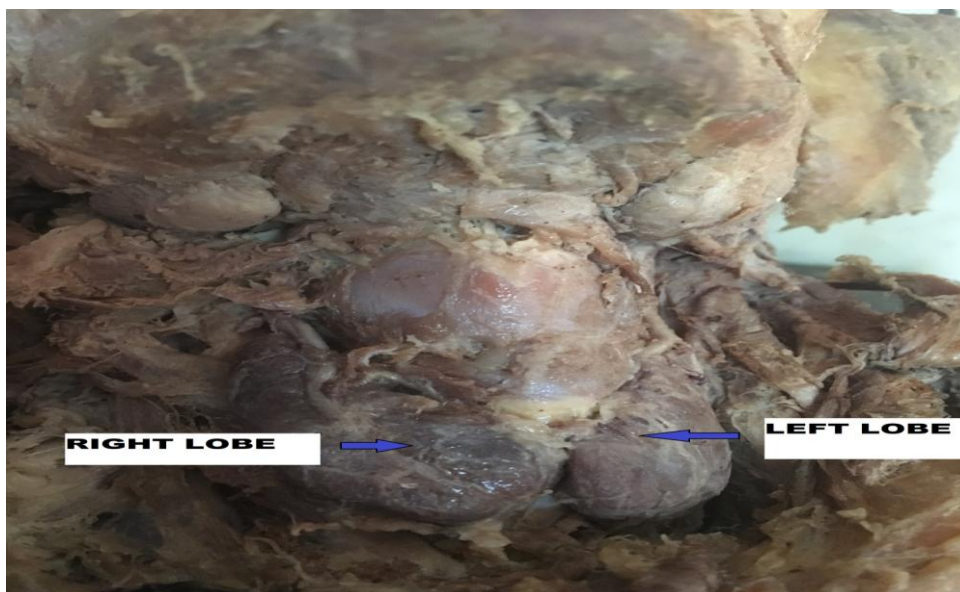

Fig:4 Showing absence of isthmus of thyroid gland



## References

- [1]. G.J Romanes ,Cunningham’s Manual of practical Anatomy.15<sup>th</sup> Edn:Vol 3,Head and Neck and Brain:p: 64- 67
- [2]. Gray’s Anatomy .40<sup>th</sup> Edn: the anatomical basis of clinical practice.London: Elsevier Churchill Lngstone.2005;724-28
- [3]. Marshall CF. Variations in the form of the thyroid gland in man. J Anat Physiol 1895;29:234–39.
- [4]. Testut L, Latarjet A. Anatomia Human. Tomo IV. 9th ed. Barcelona: Salvat editors; 1978; 402-4. Spanish. Cited by Sankar KD, Bhanu SP, Susan PJ, Gajendra K. Agenesis of the isthmus of thyroid gland, with bilateral levator glandulae thyroidea. Inter J Anat Vari 2009; 2:29-30.
- [5]. Sinnatamby CS. Head, neck & spine - triangles of neck. In: Sinnatamby CS, eds. Last’s Anatomy, Regional and Applied. 10th ed. London: Elsevier-Churchill Livingstone; 1999: 330-331.
- [6]. Moore, K.L. 1988. The developing human: Clinically Oriented Embryology. 4th ed. Toronto; W.B. saunders 184-7.
- [7]. Ranganathan TS. Levator glandulae thyroidea. In: Ranganathan TS, eds. A Textbook of Human Anatomy. 6th ed. New Delhi: S. Chand and Company Ltd; 2002: 496-497.
- [8]. Moore KL, Persaud TVN. The developing human clinical oriented embryology. Philadelphia,WBSaunders company 2003;6th ed:230-3.
- [9]. Gardner E,Gray DJ,O,Rahilly R(1975)Anatomy,4th edn.p.689 philadelphia:Igaku-Shoin/Saunders
- [10]. Von LanzT,Wachsmuth(1982)Praktische Anatomie.Vol. I(2),p.231,Berlin:springer
- [11]. RomanesGJ(1981)Cunninghams textbook .12th edn,p.595,Oxford:Oxford university press
- [12]. Hussein Muktyaz, Yadav Birendra, Saxena Dhiraj, Sharma Kr. Arun. Anatomical variations of thyroid gland and its clinical significance in North Indian population. Glob J Biol Agric Health Sci. 2013;2(2):12-6.
- [13]. Dixit D, Shilpa MB, Harsh MP, Ravishankar MV. Agenesis of the isthmus of the thyroid gland in adult human cadavers: a case series. Cases J 2009; 2:6640
- [14]. Veena kulkarni, Sankeswari Sreepadma, S. K. Deshpande. Morphological variations of the Thyroid gland. Medica Innovatica. 2012 Dec;1(2):35-8.
- [15]. Ranade AV, Rai R, Pai MM, Nayak SR, Prakash, Krishnamurthy A, Narayana S. Anatomical variation of the thyroid gland: possible surgical implications. Singapore Med J 2008;49:831-34.
- [16]. Sultana S, Mannan S, Ahmed M, Rahman M, Khan M, Khalil M. An anatomical study on pyramidal lobe of thyroid gland in Bangladeshi people. Mymensingh Med J 2008;17:8-13.
- [17]. Veerahanumaiah S, Dakshayani KR, Menasinkai SB. Morphological variations of the thyroid gland. Int J Res Med Sci 2015;3:53-7.
- [18]. Rajjini PT, Ramchandran A, Savalgi GB, Venkata SP,Mokhasi V. Variations in the anatomy of the thyroidgland: Clinical implication of a cadaver study.Anatomical Science International.2011;10:1-7.
- [19]. Zivic R, Radovanovic D, Vedic B. Surgical anatomy of the pyramidal lobe and its significance in thyroid surgery.SAJS.2011;49(3):110-116.
- [20]. Gupta R, Singla RK. Multiple anomalies in the morphology and blood supply of the thyroid gland:acase report. Journal of Dignostic and Clinical Research. 2011;5(8):1634-36
- [21]. Won HS, Chung IH: Morphologic variations of the thyroid gland in Korean adults. Korean J Phys Antropol 2002, 15:119-125.
- [22]. Braun E, Windisch G, Wolf G, Hausleitner L, Anderhuber F. The pyramidal lobe: clinical anatomy and its importance in thyroid surgery. Surg Radiol Anat 2007;29:21-27.
- [23]. Pastor VJF, Gil VJA, De Paz Fernández FJ, Cachorro MB. Agenesis of the thyroid isthmus. Eur J Anat 2006;10:83-84.
- [24]. Kaur HS, Kumar U, Bajwa SJS, Kalyan GS. Absent Thyroid isthmus: embryological and clinical implications of rare variations of thyroid gland revisited. Thyroid Res Pract. 2013;10:80-2.
- [25]. Sankar KD, Bhanu SP, Susan PJ, Gajendra K. Agenesis of the isthmus of the thyroid gland, with bilateral levator glandulae thyroidea. InterJ Anat Vari 2009; 2:29-30.
- [26]. Sharada R, Gupta C, Kalthur S, Pai SR, Rairam GB. Thyroid anomalies with its embryological and clinical correlation. CHRISMED J Health Res 2015;2:115-8