

Conservative Approach to Replace Hopeless Tooth at the Esthetic Zone by Using an Immediate Implant: Case Report with A4-Year Follow-Up

Mohammed M. Albadani

Private Practice, Qassem, Saudi Arabia Master Degree Candidate, Bari University Lecture Baird Implant Diploma, Yemen

Abstract: *Obtaining predictable outcomes with optimal success following the planned removal of a natural tooth with periodontal or endodontic complications depends on many factors that, once recognized, guide the implant team in selecting the surgical and prosthetic treatment options best suited for the patient. This article presents information regarding the use of more than one novel technique to enhance the immediate implantation, such as a traumatic extraction procedure before immediate implantation in addition to using a decision chart for reasonable extraction.*

Keywords: *immediate implant, esthetic zone, extraction*

Date of Submission: 25-07-2018

Date Of Acceptance: 10-08-2018

I. Introduction

Waiting for the normal healing 3–6 months, after tooth extraction, and then insert the implant, within time, usually because of ridge atrophy, physiological absorption of alveolar bone, width becomes narrow and height becomes low. Moreover, the gingival papilla may be lost, especially in the anterior region (1).

Clinically, dental implantation in the upper anterior esthetic zone is risky and difficult to manage due to the lack of bone mass, inadequately attached gingival papilla, and the relapse of the buccal bone, which directly affects the subsequent implant restoration esthetically (2). Therefore, maxillary anterior esthetic zone implantation is always a challenge for most dentists. The suitable time for placing an implant in the anterior region is also an issue of debate (3). The extraction of teeth with chronic infection in the maxillary anterior region is common in clinical practice; however, such cases are considered complex and high-risk cases for implantation (4).

The immediate dental implant and bone graft may regenerate the damaged facial wall of the bone, which serves as a support for three-dimensional reconstructions (horizontal, vertical, and lingual/labial thickness) of the alveolar ridge (5). Platelet-rich fibrin (PRF) is a rich source of platelets, autologous leukocytes, and fibrin biomaterial. It also effectively stimulates the formation of blood clots in the physiological state of fibrin and well avoids immune rejection and cross-infection (6). PRF platelets release six kinds of growth factors, including transforming growth factor, insulin-like growth factor, vascular endothelial growth factor, platelet-derived growth factor, epidermal growth factor, and basic fibroblast growth factor (7).

Fibrin bonds with various growth factors to produce a relatively stable gel that is stored in the PRF. Through synergy, they can promote tissue regeneration and repair. In this study, the replacement of a fractured tooth with an immediate implant is presented step by step with the use of PRF (8). This report aims to evaluate the use of a PRF mixed with xenograft in patients with chronic periodontal infection in the anterior esthetic zone over immediate implant and observe its ability to resist infection and osteogenic, gingival, and esthetic effects.

II. Case report

A 37-year-old female patient went to a private dental clinic due to a complaint of mobile teeth in the esthetic zone of the maxillary arch. Clinical examination showed a avulsed mobile crown of tooth #11. The patient was medically fit. She had poor periodontal condition with proper oral hygiene. The free gingival margin was located 2 mm below the cemento-enamel junction (CEJ) of the tooth with thin biotype periodontium and triangular-shaped crown. The fractured crown #11 was held by fiber-reinforced composite post. In addition, an 8 mm periodontal pocket was recorded in the distal aspect of the tooth (Figure 1a–c). Periapical X-ray showed fractured post-triangular root form and widening of periodontal ligament extending around the root (Figure 1d). Thus, according to Avila et al (2), extraction of tooth #11 was performed. The treatment modalities were explained to the patient. The patient was interested in an immediate implant-supported prosthesis type of restoration, and all the findings were typically indicated for immediate implant with minimum risk of soft tissue

loss, which can be treated by applying PRF over the bone graft after implant insertion. The removal of the artificial crown and composite fiber post was performed manually (Figure 2a). Then, a traumatic extraction of the remaining root (Figure 2b) was conducted using the periosteal elevator, which was inserted into the periodontal ligament space to preserve the thin buccal wall of the extracted tooth. After this step, the fibers were broken and stretched from the cementum. This separation was performed carefully and slowly. By using rotational movement, the hopeless root was removed with mosquito artery forceps. The surrounding walls and the base of the socket were checked and debrided, and confirmation of the non-infected socket was made. A full thickness flap was reflected with #15 blades to preserve the interdental papilla after local anesthesia injection. An implant depth gauge was used to ensure the intact buccal bone plates. Based on (9), the osteotomy was performed with a 2 mm pilot drill, which was placed into the socket with 13 mm implant length. Implant insertion engaged the palatal wall of the socket and penetrated halfway to two thirds of the way down the extraction site into the remaining palatal apical bone for rigid fixation. The implant drill was extended to 2–3 mm in the socket beyond the apex of the extracted tooth. Drilling was performed under copious amount of saline irrigation. The drill was then repositioned under the incisal edge of the future crown in the mid-faciopalatal and mesiodistal center, which did not coincide with the root apex position. A bone tap was used in the final depth. An implant fixture (4.2 mm x 13 mm; tioLogic® dental implants, Dentaaurum Implants GmbH, Germany) was threaded in the extracted site (Figure 2c). The implant was countersunk below the facial bone, and the implant platform was placed as much as 4 mm apical to the CEJ of the adjacent teeth (Figure 2e). One gram of bovine bone grafts (Cancellous and Cortical Granules, Natural Bone Mineral Matrix Deproteinized Bovine Bone, ACEUSA) was packed after the implant placement (Figure 2f). PRF was prepared as described by (4). Blood was drawn from the vein into 10 mL tube without anticoagulant (Vacuette, Greiner Bio-One, Kremsmünster, Austria). A total of 40 mL of blood was taken from the patient. The tube was immediately centrifuged at 400× g for 12 min (A-PRF fibrin centrifugal machine, Germany TBL, Model: pc02). After centrifugation, three layers were obtained: cellular plasma (platelet-poor plasma) was concentrated at the top and was collected using a syringe; fibrin clots and red corpuscles were removed from the tube with a scalpel; a PRF clot was immediately separated from red corpuscles by using tweezers. This clot was placed and pressed over the graft to obtain a membrane. A 2 pieces of PRF was placed over the graft (Figure 2d). Periapical radiograph was taken to check the position of immediate implant in relation to the extraction site (Figure 2g). Furthermore, primary implant stability of 35 Nm torque was confirmed prior to the provisional restoration. The tissue was sutured in place using a horizontal mattress technique.

Twenty-four hours after the surgery, direct provisional crown (Success SD, PROMEDICA NEUMUNSTER, Germany) was constructed for tooth #11 from an anterior direct rubber base index (which was taken before the extraction). The provisional crown was cemented with temporary cement (Temp-Bond™, Italy) (Figure 3a). After one month, the patient was recalled for a proper provisional crown construction due to improper interdental papilla contouring (Figure 3b). Composite re-contouring was carried out (Tetric-NCeram, Ivoclar Vivadent, Liechtenstein) on the labial surface of tooth #21 to improve the final esthetic outcome. The cover screw of tooth #11 was removed, and the gingival former was placed for two months with new provisional crown (Figure 3c, d).

The patient was recalled for the second stage surgery. Customized metal temporary abutment was prepared extra-orally and hand tightened onto the implant. The customized temporary abutment and its corresponding provisional restorations were made to capture the cervical gingival emergence of the extracted tooth. Two months later, the provisional crown was removed, and impression copings were screwed onto the top of the implant. Light polymerizing resin material (LiquiDAM, Discus Dental, Culver City, CA) was injected around the impression copings to prevent the soft tissues from collapsing onto the impression copings. The final implant level impression was taken by utilizing open tray technique for the maxillary arch using plastic stock tray with additional silicon (Virtual Ivoclar Vivadent, Liechtenstein). Pouring of the final impression was performed with CAD/CAM special stone (BEGO, Germany). The die preparation, ditching, and finish line exposure were performed. The master maxillary cast was mounted manually using Di-Lok tray (Di-Equi Dental Products). The cast was transferred to a laser scanner (Cynoprod Canada Inc. Listings, Montreal, Canada) for scanning and capturing the preparation. The scanner was connected to a computer screen, and the software program 1.3 EVLOTION (Cynoprod Inc. Listings, Montreal, Canada) was used for milling the zirconia core. The core was constructed with Vita In-Ceram YZ Disc (Vita Zahnfabrik, Germany). The ceramic build-up (VMK 95, Vita, Germany) and shade guide selection (2M2 - 3D master) were according to the manufacturer's instruction. The crown was tried-in, and the occlusion was adjusted in the centric and eccentric mandibular positions. The glazed ceramic crown was cemented (Figure 4a–c). The patient was seen after 3, 6, 12, and 24 months. The soft tissues around the implant-supported restorations showed excellent tissue appearance with absence of inflammation or gingival recession. The interdental papillae appeared normal, enhancing the optimal esthetic result obtained by the definitive ceramic crown (Figure 4d–f). The patient was motivated to keep standard oral hygiene instructions during the follow-up appointments.

Extra-oral view with cone beam computed tomography imaging were taken after four years (Figure 5a,b).

III. Discussion

Atraumatic extraction with flap reflection and immediate implant insertion with single-stage surgical technique is a sensitive procedure. According to (2), a novel decision-making chart was used to decide the extraction of the upper central 11 because this tooth was non-restorable and affected by periodontal disease, and the patient was willing to have the tooth extracted. Many dentists delay treatment of sites exhibiting infection. The survival rate after two years of treatment reaches 100% on a case series of patients whose teeth were extracted following immediate implant insertion (11–12). Preserving the continuity of the bone surrounding the root for primary stability and long-term success, especially in upper anterior region, is very necessary (13).

A traumatic technique for extraction was performed, as the fracture line runs sub-gingivally and to prevent the loss of the thin facial cortex of the maxillary bone. Implant socket was prepared slightly palatal to achieve primary stabilization. In this case, the socket was removed in totality, and the socket was debrided and filled with bone graft. PRF represents a modern procedure in the platelet gel treatment modality. PRF production steps attempt to accumulate platelets and deliver cytokines in a fibrin clot (10). Unlike other platelet concentrates (14,15), this procedure requires neither bovine thrombin nor anticoagulants; it uses only centrifuged natural blood without additives. A PRF is a fibrin matrix that has different effects than platelet-enriched fibrin glue (such as PRP), which has a short-term and uncontrollable effect. Though leukocyte cytokines and platelets have an important role in the biology of these materials, the fibrin matrix supporting them certainly constitutes the determining element responsible for the real therapeutic effect of PRF (4,15,16). Thus, the synergic effect between cytokines and their supporting fibrin matrix has much more importance than any other factors.

In this case report, we used a novel therapeutic procedure including a traumatic technique for extraction and modern procedure in the platelet gel treatment modality to obtain optimal success of immediate implant insertion on the very sensitive area with thin facial cortex on the maxillary anterior segment of maxilla, which often becomes compromised or lost.

The clinical significance of this case is using PRF as adjunctive therapy to replace a hopeless tooth by means of a conservative approach with immediate implant after establishing a proper contouring of the interdental papillae with labial correction of the adjacent tooth for esthetic symmetry. Excellent clinical findings were recognized after four years follow-up.

IV. Conclusions

One of the options for management of fractured tooth at the esthetic zone is to provide immediate implant placement with immediate loading. A traumatic extraction with preservation of buccal bone was performed. The authors describe a technique, including a traumatic tooth removal with simultaneous root form implant placement at the time of extraction with barrier membranes and temporization. Immediate implant placement with immediate loading is an option that provides excellent treatment modality, allows good functional and esthetic results, and addresses the social/psychological aspects of dental fractures.

References

- [1]. Schropp L, Wenzel A, Kostopoulos L et al. Bone healing and soft tissue contour changes following single tooth extraction, a clinical and radiographic 12 month prospective study. *Int J Perio Rest Dent* 2003;23: 313-323.
- [2]. Avila G, Galindo-Moreno P, Soehren S, et al. A Novel Decision-Making Process, Decision Chart. *J Peri* 2009; 80: 213-219.
- [3]. Buser D, Martin WC, Belser UC. Surgical considerations with regard to single tooth replacements in the esthetic zone. *Quintessence* 2007; (1): 26–37.
- [4]. Lixin XU, Ding Y, Chaofeng L, Weipeng J. The Use of advanced Platelet-Rich Fibrin during Immediate Implantation for the Esthetic Replacement of Maxillary Anterior Segment with Chronic Apical Lesion. *Int J Scie Research* 2012; 3:358.
- [5]. Buser D, Chen ST, Weber HP, et al. Early implant placement following single tooth extraction in esthetic zone: a biologic rationale and surgical procedures. *Int J Peri Resto Dent* 2008;28 : 441-451.
- [6]. Buser D, Halbritter S, Hart C, et al. Early implant placement with simultaneous GBR following single tooth extraction in the esthetic zone, 12 month results of a prospective study with 20 consecutive patients. *Period* 2009; 80 : 152-162.
- [7]. Nicosia RF, Santo Nicosia, Smith M. Vascular Endothelial Growth Factor, Platelet-Derived Growth Factor, and Insulin-Like Growth Factor-1 Promote Rat Aortic Angiogenesis In Vitro. *Am J Pathol* 1994, 145:1023-29.
- [8]. Sharma S, Srivastava D, Grover S, Sharma V. Biomaterials in Tooth Tissue Engineering: A Review. *J Clin Diag Res* 2014; 8(1): 309-315.
- [9]. Misch Carl E: Anterior Single-Tooth Replacement: Surgical Considerations. Textbook of CONTEMPORARY IMPLANT DENTISTRY ISBN, Third Edition, by Mosby, Inc., an affiliate of Elsevier Inc: 2008; PP 733-768.
- [10]. Choukroun J, Diss A, Simonpieri A, et al. Platelet-rich fibrin (PRF): a second-generation platelet concentrate. Part IV: clinical effects on tissue healing. *Oral Surg Oral Med Oral Pathol Oral Radiol Endo* 2006;101:e56-60.
- [11]. Villa R, Rangert B. Early loading of inter-foraminal implants immediately installed after extraction of teeth presenting endodontic and periodontal lesions. *Clin Implant Dent Relat Res* 2005;7 :S28-S35.
- [12]. Novaes AB Jr, Novaes AB. Immediate implants placed into infected sites: a clinical report. *Int J Oral Maxi Impl* 1995;10:609-13.

Conservative approach to replace hopeless tooth at the esthetic zone by using an immediate implant:

- [13]. Chen ST, Darby IB, Adams GG, Reynolds EC. A prospective clinical study of bone augmentation techniques in immediate implants. Clin Oral Impl Res 2005;16:176-84.
- [14]. Froum SJ, Wallace SS, Tarnow DP, Cho SC. Effect of platelet-rich plasma on bone growth and osseointegration in human maxillary sinus grafts: Three bilateral case reports. Int J Peri RestDent 2002; 22:45-53.
- [15]. Kassolis JD, Rosen PS, Reynolds MA. Alveolar ridge and sinus augmentation utilizing plateletrich plasma in combination with freeze-dried bone allograft: case series. J Period 2000; 71:1654-61.
- [16]. Marx RE, Carlson ER, Eichstaedt RM, Schimmele SR, Strauss JE, Georgeff KR. Platelet-rich plasma: Growth factor enhancementfor bone grafts. Oral Surg Oral Med Oral Pathol Oral RadiolEndod 1998; 85(6):638-646.

List of figures and ligand

Figure 1: Preoperative clinical and radiographical view

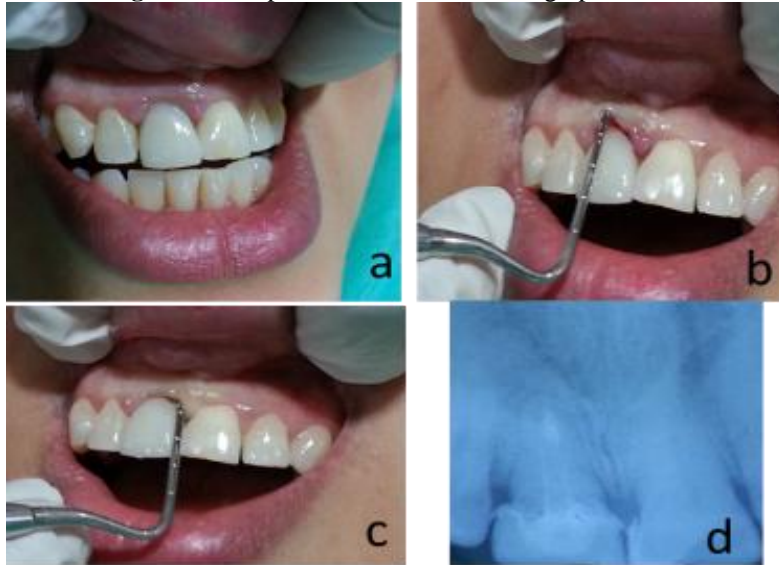


Figure 2: Surgical steps including or involving removal of fractured post and roots and placement of implant, fibrin, and bone graft

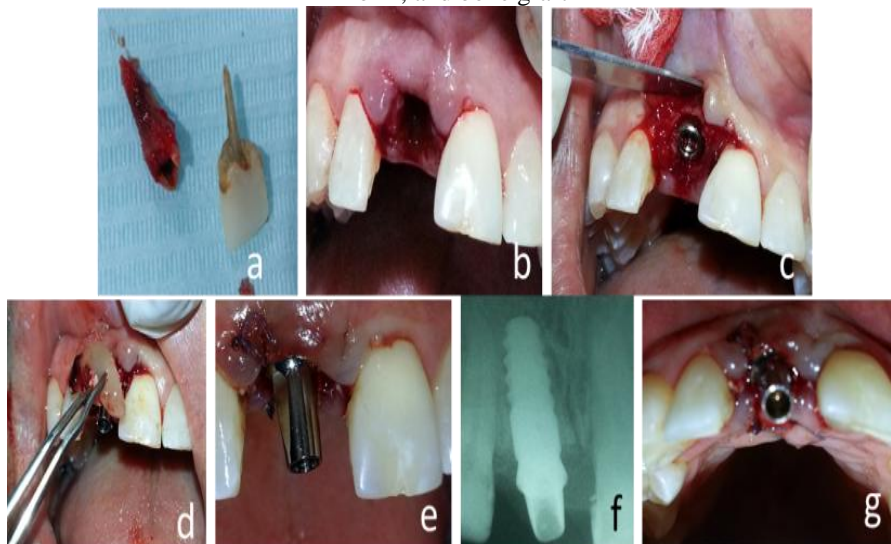


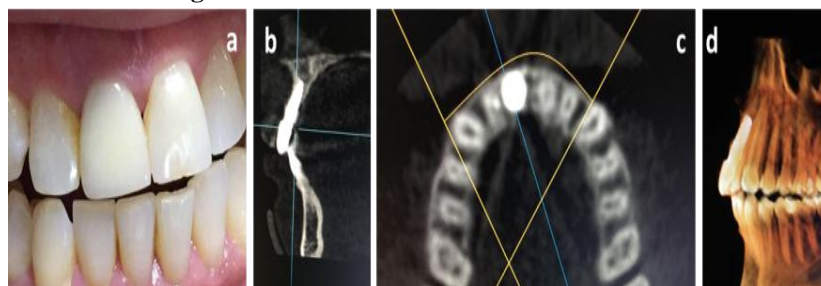
Figure 3: Immediate provisional crown and correction of interdental papillae with second provisional crown and labial composite of tooth #21

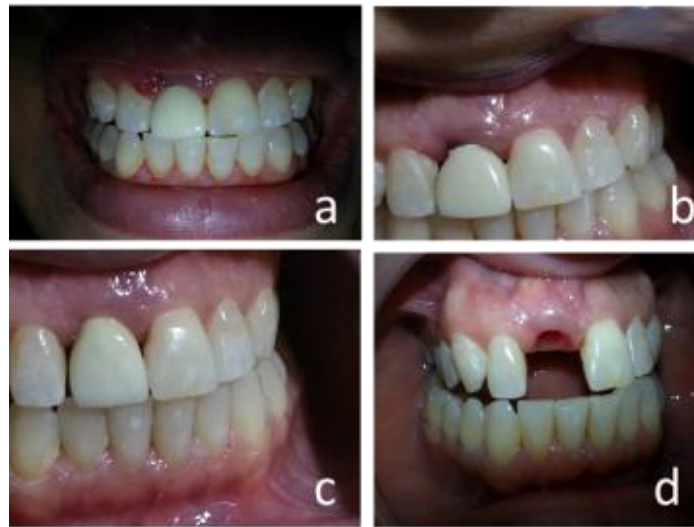

Figure 4: Postoperative clinical views with different smile line and radiographic views

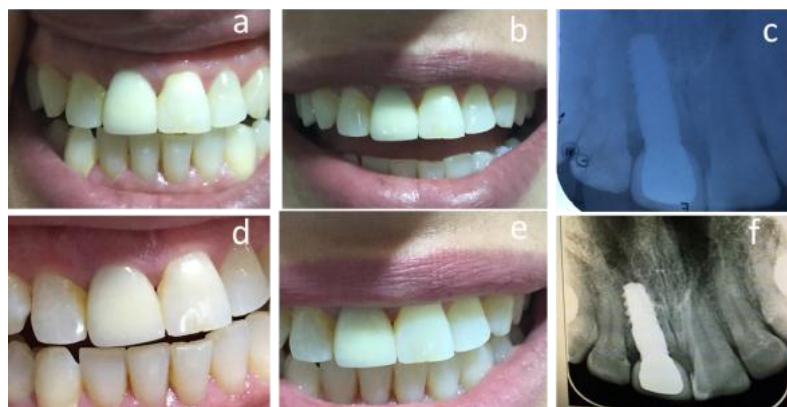

Figure 5: Four Year Clinical and CBCT views



Mohammed M. Albadani " Conservative Approach to Replace Hopeless Tooth at the Esthetic Zone by Using an Immediate Implant: Case Report with A4-Year Follow-Up."IOSR Journal of Dental and Medical Sciences (IOSR-JDMS), vol. 17, no. 8, 2018, pp 68-72.