

## Tunica vaginalis flap as second layer in hypospadias surgery : our experience at a tertiary health care centre.

Sanjay Kumar<sup>1</sup>, S K Jha, Sudhir kumar

Department of plastic surgery, Nalanda Medical College & Hospital, Patna, India.

<sup>1</sup>Corresponding author : Sanjay Kumar, house no-3, road no-13, rajiv nagar, patna, bihar-800024.

**Abstract:** Hypospadias surgery with so many developments in the field is still fraught with the most common complication of fistula formation regardless of type of hypospadias, technique performed and surgeon's expertise. Each refinement aims in decreasing the incidence of formation of urethrocutaneous fistula viz; two stage repair, dartos flap cover, overlapping suture line etc. Parietal layer of tunica vaginalis from testis as a covering over reconstructed neo urethra decreases fistula rate. Unlike dartos layer, tunica vaginalis brings vascular supply from outside source hence helping in better healing of suture line of neo-urethra. Study of effectiveness of tunica vaginalis flap covering in two common procedures performed is presented with significant decrease of urethro-cutaneous fistula.

Date of Submission: 12-09-2018

Date of acceptance: 28-09-2018

### I. Introduction :

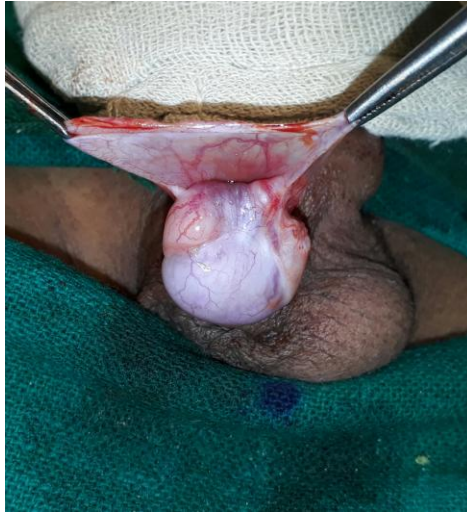Hypospadias repair still, after so many developments in the field is fraught with fistula formation. With more than 150 techniques of repair,<sup>(1)</sup> none guarantees fistula proof repair. Urethro-cutaneous fistula in hypospadias repair occur regardless of the type of hypospadias, technique or the surgeon.<sup>(2)</sup> Various techniques were introduced to reduce the incidence of fistula formation, like use of better suture, technique of urethroplasty, second layer covering, staging of repair etc. One such effort to reduce the risk of urethrocutaneous fistula formation is the use of tunica vaginalis flap as second layer covering over urethroplasty. We report our experience with the tunica vaginalis flap as second layer over urethroplasty.

### II. Material And Methods:

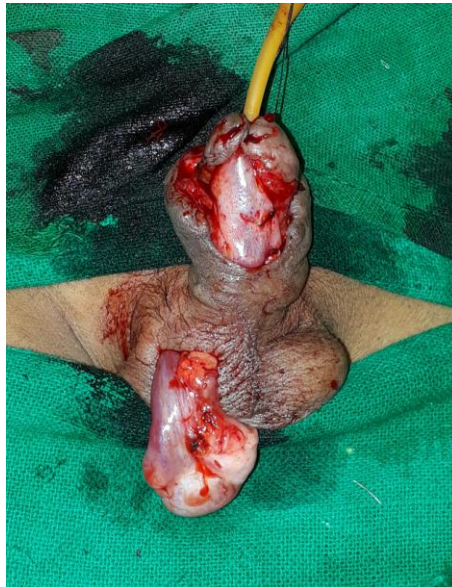
The study was conducted from October 2015 to December 2016 (in department of plastic surgery, Nalanda Medical College, Patna, Bihar). All uncomplicated fresh cases of hypospadias were included in the study. Patients' age ranges from 3 to 22 years (mean, 5.38 yrs). Total of 26 cases of hypospadias urethroplasty were performed in this duration which included proximal as well as distal hypospadias. The techniques used were either Snodgrass (for distal hypospadias) or Bracka staged repair (for proximal hypospadias). All re-do cases and fistula closures were excluded from the study.

10 patients were repaired by Snodgrass (T.I.P) urethroplasty while 16 proximal hypospadias patients were repaired by Bracka staged repair in which chordee excision was done in first stage followed by second stage urethroplasty by Thiersch Duplay principle four to six months later.

All urethroplasties were performed under magnification with Vicryl 5-0/6-0 over silicone Foley's catheter. In all patients, tunica vaginalis flap from outer layer of testis was harvested via the same incision in proximal cases and via a short transverse scrotal incision in distal cases. After delivery of testis in the operative field, parietal layer of tunica vaginalis was elevated and two stay sutures were applied distally over medial and lateral aspect (picture-1). Then the flap was elevated proximally including the stay sutures in a rectangular fashion. The flap was delivered to the neourethra by making a subcutaneous tunnel in distal hypospadias cases. The flap was fixed in place with 5-0 interrupted Vicryl sutures just distal to corona (picture-2). A small corrugated drain was placed in scrotum in all cases. Preputioplasty and glanuloplasty performed after securing hemostasis. Foley's catheter was kept for 14 days with twice daily bladder wash prophylactically to prevent catheter blockage. All patients were followed for 6 months.



**Picture 1** : exposing tunica vaginalis from Parietal layer of testis.



**Picture 2** : Tunica vaginalis flap over neourethra.

**III. Results:**

Out of 26 cases,3(11.54%) patients developed urethrocutaneous fistula.Out of 10 snodgrass urethroplasty 1(10%) patients developed urethrocutaneous fistulas,whereas in 16 patients who underwent bracka second stage urethroplasty,only 2(12.5%) patients developed urethrocutaneous fistula. Fistulas were managed later on by secondary surgeries.

Fistula rate of two procedures:

Procedure performed	Fistula(n)	Fistula (%)
Snodgrass urethroplasty with TVF cover	1/10	10%
Bracka two stage withTVF	2/16	12.5%

One case of Snodgrass urethroplasty developed scrotal hematoma formation, which later on also developed skin dehiscence and urethrocutaneous fistula.

One case of Snodgrass urethroplasty developed meatal stenosis which was managed conservatively by serial meatal dilatation with feeding tube.

Other complications :

Hematoma	1
Skin dehiscence	1
Catheter blockage	Nil
Infection	Nil
Meatal stenosis	1

Penile torsion	Nil
Testicular malposition	Nil
Scrotal abscess	1

#### IV. Discussion:

Several different surgical techniques have been advocated to achieve a successful result following hypospadias surgery. The success of the method depends on its low complications rates in the treatment of hypospadias. Better suture materials, use of magnification, dorsal subcutaneous flap, silicone stents and catheters have all contributed to a decrease in fistula rate.<sup>(3,4)</sup>

Some of these techniques use the penile skin while some other methods use extra penile tissues, including the buccal mucosa,<sup>(5)</sup> the skin graft,<sup>(6)</sup> and the tunica vaginalis as a flap or graft.<sup>(7)</sup>

Snodgrass procedure or Incised Plate Urethroplasty is a method with high success rate;<sup>(8)</sup> however, urethrocutaneous fistula is a common complication following this technique.<sup>(9)</sup>

To decrease the rate of this complication, a vascularized tissue is applied as a second layer between the neourethra and the skin coverage.<sup>(10)</sup> Dorsal flap is a tissue that has been used for the neourethra coverage to improve the outcome; however, this technique sometimes results in penile torsion or chordee.<sup>(9)</sup> an increased incidence of wound healing problems in the form of small eschar, edema and skin dehiscence. John Duckett has ascribed it to hypovascularity of the overlying skin when dartos is separated from skin.<sup>(9)</sup>

An alternative technique is the use of tissues such as dartos fascia of ventral side of the penis. Furness and Hutcheson reported a success rate of 98% for this method and of 109 patients, only 2 developed fistulas.<sup>(11)</sup>

Tunica vaginalis is another tissue that can be used as a second layer in hypospadias repair. Advantages of this flap are its excellent vascularity and availability even in re do cases. Furthermore, because this tissue is far from the penis, it is not affected by the penis disorders. Besides, acceptable outcomes have been achieved from the use of tunica vaginalis flap for repair of urethrocutaneous fistula.

Introduction of this flap is credited to Snow<sup>(7,12)</sup> *et al* in 1986. It has a dependable blood supply from the cremasteric vessels and its pedicle length can safely be increased up to the external inguinal ring. Care must be taken while increasing pedicle length as the tissue becomes more flimsy proximally and at the same time inadequate pedicle length can cause tethering of the testis at a higher level compared to the normal side.

The correct plane of cleavage during degloving is important; inverting the edge of the epithelial surface of the neourethra is necessary to avoid fistula formation. The results of urethroplasty also depend on the vascularity around the reconstruction, and this may be damaged by using an incorrect tissue plane, improper tissue handling or by haematoma after surgery. The Tunica vaginalis pedicled wrap is a good vascularized flap, as it has a different blood supply and does not depend on the vascularity of penile skin, unlike the dartos fascia wrap. Dissecting the tunica vaginalis is technically easier and may be done even by beginners in hypospadias surgery. In our study, overall fistula rate was 11.54%, (10% in Snodgrass urethroplasty<sup>(8)</sup> and 12.5% in bracka urethroplasty technique<sup>(13)</sup>), which was higher than snow and associates (5%). This could be due to use of microscope by Snow and associates.<sup>(12)</sup>

In a study by Snow and colleagues, most of the post tunica vaginalis flap complications were related to scrotal hematoma and abscess, while the rate of 5% was reported for urethrocutaneous fistula.<sup>(12)</sup> Therefore, Snow and associates has recommended tunica vaginalis flap as a second layer for primary hypospadias repair.

In a similar study by Handoo, rate of fistula formation were 12.5% and 5% in Snodgrass and bracka stage two urethroplasty respectively, when tunica vaginalis flap was used for cover.<sup>(14)</sup>

We have encountered only one case of scrotal hematoma leading to skin dehiscence and fistula formation, which was higher in the study by snow and colleagues.

#### V. Conclusion:

Tunica vaginalis flap is a good option for interposition over the neourethral tube. It is well vascular, easy to harvest, remote from the surgical site and can cover whole of the neourethra. It is an useful armamentarium in hands of hypospadias surgeons, especially in re-do cases/hypospadias cripples and fistula repair. It avoids penile torsion and risk of skin devascularisation associated with the use of dartos flap. Careful dissection of the scrotum and attention to hemostasis can reduce scrotal complications as well. Currently, fistula formation remains the most common complication of this technique, which often necessitates reoperation.

**CONFLICT OF INTEREST: NONE**

**SOURCE OF SUPPORT : NONE**

**References:**

- [1]. Hodgson NB. History of hypospadias repair, Reconstructive and plastic surgery of the external genitalia adult and pediatric. WB Saunders Company; 1999. p. 16.
- [2]. Belman AB. *In* : Kelalis PP, King LR, Belmanab, (editors) Urethra, Clinical Paediatric Urology, 2nd ed. WB Saunders;; 1985. p. 781.
- [3]. Retic AB, Keating M, Mandell J. Complications of hypospadias repair. Urol Clin North Am 1988;15:223-6.
- [4]. Duckett JW, Jr., Kaplan GW, Woodard JR, Devine CJ, Jr. Panel: complications of hypospadias repair. Urol Clin North Am. 1980;7:443-54
- [5]. Ahmed S, Gough DC. Buccal mucosal graft for secondary hypospadias repair and urethral replacement. Br J Urol. 1997;80:328-30.
- [6]. Ehrlich RM, Alter G. Split-thickness skin graft urethroplasty and tunica vaginalis flaps for failed hypospadias repairs. J Urol. 1996;155:131-4.
- [7]. Snow BW. Use of tunica vaginalis to prevent fistulas in hypospadias surgery. J Urol. 1986;136:861-3.
- [8]. Snodgrass W. Tubularized, incised plate urethroplasty for distal hypospadias. J Urol. 1994;151:464-5.
- [9]. Duckett JW. Campbell's urology, 7th ed. WB Saunder Company;1998. p. 2114.
- [10]. Retic AB, Mandell J, Bauer SB, Atala A. Meatal based hypospadias repair with use of dartos sub-cutaneous flap to prevent urethra-cutaneous fistula. J Urol 1994;152:1229-31.
- [11]. Furness PD, 3rd, Hutcheson J. Successful hypospadias repair with ventral based vascular dartos pedicle for urethral coverage. J Urol. 2003;169:1825-7;discussion 7.
- [12]. Snow BW, Cartwright PC, Unger K. Tunica vaginalis blanket wrap to prevent urethrocutaneous fistula: an 8-year experience. J Urol. 1995;153:472-3.
- [13]. Bracka A. Hypospadias repair: the two-stage alternative. Br J Urol 1995;76:31-41.
- [14]. Handoo YR. Role of tunica vaginalis interposition layer in hypospadias surgery. Indian J Plast Surg 2006;39:152-6.

Sanjay Kumar ." Tunica vaginalis flap as second layer in hypospadias surgery : our experience at a tertiary health care centre. ." IOSR Journal of Dental and Medical Sciences (IOSR-JDMS), vol. 17, no. 9, 2018, pp 21-24.