

Evaluation of Intraoperative Frozen Sections: Experience in a Tertiary Care Hospital

Pranati Misra, Nageswar Sahu, Urmila Senapati

Department of Pathology, Kalinga Institute of Medical Sciences and Pradyumna Bal Memorial Hospital, Bhubaneswar, Odisha, India.

Corresponding author: Dr Nageswar Sahu

Abstract:

Aim: Intraoperative frozen section analysis play an important role in modern day surgical practice. The quality assurance of this technique is vital as it is a major tool in guiding the patient surgical management. The present study was conducted to evaluate the diagnostic accuracy of frozen section results and to find out the common reasons of misdiagnosis.

Method: This is a retrospective study done by retrieving the data from frozen section and routine histology registers over a period of two years. Total 163 cases were received for frozen section analysis in that period. Out of these 2 cases were deferred and analysis was done on 161 cases.

Results: Out of 163 cases, results were deferred in 2 cases for routine histology leading to a deferral of 1.23%. The diagnostic accuracy was found to be 90.68% with a false positive diagnosis of malignancy in 4.97% and false negative benign diagnosis in 2.49% cases. The major causes of misdiagnosis were found to be interpretation error (73.33%), followed by sampling error (20%) and scanty tissue for analysis (6.67%). The interpretation error was mostly due to the freezing artefacts.

Conclusion: A thorough clinical and radiological knowledge, proper sampling and processing as well as interpretation by experienced pathologists are the prerequisites for accurate diagnosis in frozen section study.

Key words: Frozen section, Intraoperative, Diagnostic accuracy, Interpretation error.

Date Of Submission: 15-09-2018

Date of acceptance: 03-10-2018

I. Introduction

In this era of advancing technology in medical science frozen sections play an important role in guiding the surgeons for intraoperative and perioperative patient management.¹

William H. Welch from John Hopkins Hospital in 1891 first developed the frozen section technique for intra-operative consultation.^{2,3,4} In 1905 Louis B Wilson also developed a technique to quickly evaluate the frozen tissues.^{4,5} This practice has since then evolved and preparation of frozen section was made easier after the development of cryostat in 1959.^{2,3,4}

The common indications of frozen sections are determination of nature and extent of a lesion, evaluation of surgical margins and identification of lymph node metastasis in malignant lesions and confirmation of presence of representative samples for paraffin section diagnosis.^{1,2,3,6} Other indications are performing enzyme histochemistry, immunohistochemistry and immuno-fluorescence.² However the most important role of frozen sections is to differentiate between benign and malignant lesions.^{1,6}

A review sponsored by College of American Pathologist (CAP) of over 90,000 frozen sections at 461 institutions showed a concordance rate of 98.52%. As per their study the common causes for the discrepancies were misinterpretation of the original frozen section (31.8%) and absence of diagnostic tissue in the frozen material but present in the unsampled tissue or in the corresponding routine histopathology section (31.4%).⁷

In the present study we wanted to analyse the frozen section results and compare it with the final histopathological diagnosis to evaluate its diagnostic accuracy. We also tried to find out the possible causes of misdiagnosis in discordant cases.

II. Materials And Methods

The present study is a retrospective study conducted in the Department of Pathology, Kalinga Institute of Medical Sciences and Pradyumna Bal Memorial Hospital, Bhubaneswar, Odisha. We have retrieved all cases of frozen sections from 16th June 2016 to 15th June 2018. During this period 163 cases were received for intra-operative frozen section analysis.

Fresh tissues were sent without any fixative in a clean plastic container from the operation theatre to the frozen section room along with appropriate clinical details mentioned in the requisition form. The gross

specimens were inspected and sections were taken from representative areas whenever necessary. The cryostat temperature was set within a temperature range of -20°C to -24°C. Blocks were cut on the cryostat (Leica CM 1850) using Tissue freezing medium as embedding medium. Sections were cut at a thickness of 4µ to 5µ followed by rapid Hematoxylin-Eosin staining. The frozen section diagnosis were made by the consensus opinion of two pathologists. The diagnosis was immediately informed to the surgeons in the operation room over phone.

Frozen sections remnant as well as any remaining non frozen tissue were then fixed in 10% formalin solution and sent to the histopathology section for routine processing, paraffin embedding, section cutting and conventional Hematoxylin-Eosin staining.

The frozen section (FS) diagnosis was compared with the final histopathology (HP) diagnosis of the permanent sections. The indications, accuracy, causes of errors and deferral of the frozen section reporting were analysed.

III. Results

During the study period of 2 years 163 cases were received for frozen section analysis. Two cases were deferred because of insufficient amount of tissue, hence were excluded from the study, resulting in a sample size of 161 cases.

The common indications for frozen section analysis in this study were assessment of surgical margins (55.28%), primary diagnosis of tissues (46.58%), assessment of nodal status (5.59 %) and identification of ganglion cells in suspected cases of Hirschsprung’s disease (3.73%). In some cases frozen section was done for multiple purposes like primary diagnosis and nodal or marginal status.

The commonest tissue received for FS analysis was oral mucosa followed by breast, nose and paranasal sinus and ovary (Table-1).

Table-1: Diagnostic Accuracy of Frozen sections as per site of biopsy

Sl. No	Site	No. of cases	Concordant	Discordant	Accuracy(%)
1	Oral cavity	53	52	1	98.11
2	Breast	12	9	3	75
3	Stomach	7	6	1	85.71
4	Nose and PNS	11	9	2	81.82
5	Thyroid	6	4	2	66.67
6	Colorectal	6	5	1	83.33
7	Liver and Gall Bladder	9	8	1	88.89
8	Pancreas	2	2	0	100
9	Brain	7	5	2	71.43
10	Spinal cord	3	3	0	100
11	Ovary	10	9	1	90
12	Uterus and cervix	3	3	0	100
13	MGS	5	5	0	100
14	Skin	4	4	0	100
15	Bone	2	2	0	100
16	Lymph node	5	5	0	100
17	Suspicious metastatic nodule	3	2	1	66.67
18	Intestine for ganglion cells	6	6	0	100
19	Others	7	7	0	100
	Total	161	146	15	90.68

PNS-Paranasal sinus, MGS-Male genital system

The frozen section diagnosis was concordant with the histopathological diagnosis in 146 cases resulting in a diagnostic accuracy of 90.68%. False positive diagnosis of malignancy was given in 8(4.97%) cases and false negative diagnosis was given in 4(2.49%) cases (Table-2).

Table 2: Causes of Discordant results

Sl. No.	Site	No. of discordant cases	False positive for malignancy	False negative for malignancy	Cause of discrepancy
1	Oral cavity	1	1	0	Small tumor size
2	Breast	3	2	1	Interpretation error
3	Stomach	1	1	0	Interpretation error
4	Nose and PNS	2*	1	-	Interpretation error
5	Thyroid	2	0	2	Sampling error
6	Colorectal	1	0	1	Sampling error
7	Liver and Gall bladder	1	1	0	Interpretation error

8	Ovary	1	1	0	Interpretation error
9	Brain	2*	-	-	Interpretation error
10	Suspicious metastatic nodules	1	1	0	Interpretation error
	Total	15	8	4	

*1 case from Nose and Paranasal sinuses and 2 from Brain were discordant because of misinterpretation leading to discrepancy in typing and/or grading of tumor.

PNS - Paranasal sinuses

The diagnostic accuracy was cent percent in most of the tissues. The causes of discordant results were found to be interpretation error in 11/15(73.33%) cases, sampling error in 3/15(20%) cases and insufficient sample in 1(6.67%) case.

Out of the 15 discordant cases 3 were breast tissues. Among these 2 cases sent for status of surgical margins were wrongly diagnosed to be involved by carcinoma. A case diagnosed as benign phyllodes tumor on frozen section was later found to be malignant phyllodes tumor. Gastric margin sent in a case of infiltrating adenocarcinoma of stomach was misinterpreted as involved by tumor.

A case from nose and paranasal sinuses diagnosed as Non Hodgkin lymphoma (NHL) was later found to be a case of adenoid hypertrophy on routine histology (Figure-1). Another case of nasal mass diagnosed as small round cell tumor was found to be an uncommon lesion adenocarcinoma (high grade - non intestinal, non salivary). Both these discordant results were due to interpretation error. In the CNS lesions erroneous typing and grading of tumor was found in 2 cases. A case of metastatic round cell tumor was misdiagnosed as anaplastic astrocytoma and a case of neurocytoma was wrongly diagnosed as a case of pineoblastoma in FS study. Suspicious nodules from liver and other sites were also wrongly diagnosed as carcinoma in frozen section. Similarly an ovarian mature cystic teratoma was misinterpreted as immature teratoma.

Due to errors of sampling in lesions of thyroid false negative diagnosis of nodular goitre was given in a case of a medullary carcinoma (Figure-2) and in a case of papillary microcarcinoma. Similarly sampling error was also found in a case of colorectal adenocarcinoma which was underdiagnosed as colorectal adenoma in FS.

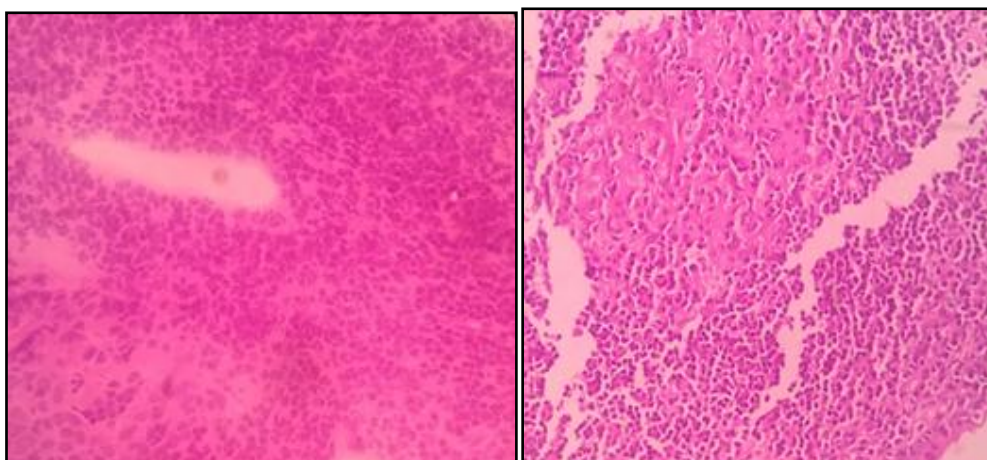


Figure-1a

Figure-1b

Figure 1: a(FS,100x)-sheets of large lymphoid cells. b(HP,100x)-enlarged lymphoid follicle.

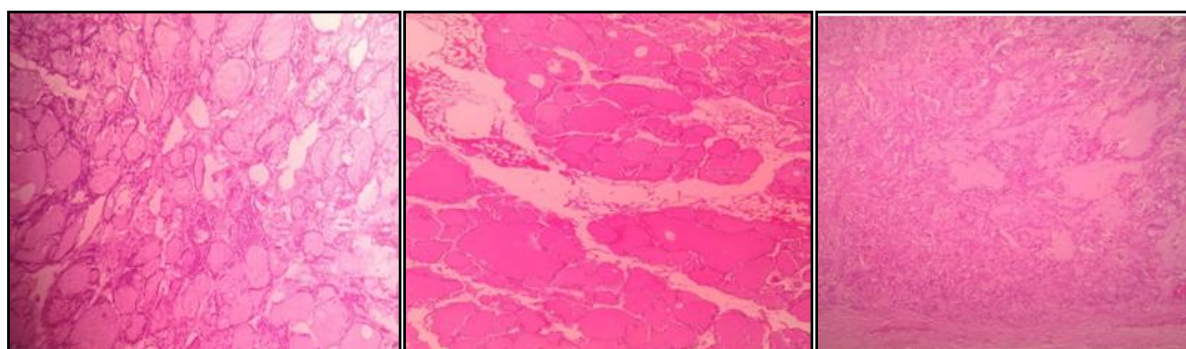


Figure-2a

Figure-2b

Figure-2c

Figure-2: a(FS,100x) & b(HP,100x)-showing changes of colloid goiter. c(HP,100x)-section from a small nodule left in the thyroid remnant showing features of medullary carcinoma of thyroid.

IV. Discussion

Frozen section is considered a rapid and reliable method to assist the surgeons in making intraoperative decisions. Also this process allows the remnant tissue to be preserved for further routine histopathological study. However this procedure is costly and needs technical expertise.¹

A total of 163 cases were received for frozen section analysis during the study period. Out of these, 2 cases were deferred. One of them was a bony tissue from tibia that could not be processed properly. Another case was from a suspicious ureteric space occupying lesion where the scanty tissue made it difficult to make any diagnosis. These two cases were excluded from analysis leading to a deferral of 1.23%(2/163) as compared to results of 1% by Patil P et al¹, 3.93% by Ahmad Z et al⁸ and 4.62% by Silva R.D.P. et al⁵.

In the present study the overall diagnostic accuracy of frozen section was 90.68%. A comparative analysis of diagnostic accuracy in various studies is detailed below (Table-3). The incidence of false negative diagnosis of malignancy (2.49%) in our study is comparable with the results obtained by Silva et al⁵ (2.08%) and Shrestha S. et al³ (3.9%). The rate of false positive diagnosis of malignancy (4.97%) in the present study is higher as compared to other studies (0-1.9%)^{3,5,10}. The false positive diagnosis were mostly due to interpretation errors, while false negative diagnosis were mostly due to errors in sampling similar to result seen by Chbani L et al.¹⁰

Table-3: Comparative table of diagnostic accuracy of Frozen Sections

Author(s)	Period of study (years)	No. of cases	Diagnostic accuracy (%)
Zubair Ahmad et al ⁸	1	342	97.08
Patil P. et al ¹	2	100	96.96
Saumya Misra et al ⁴	2	52	96.2
Shrestha S et al ³	5	404	94.6
Agrawal Preeti et al ⁹	2	224	94.2
R.D.P.Silva et al ⁵	7	433	93.3
K.Chandramouleswari et al ²	1	51	92
Present study	2	161	90.68

Among the 15 discordant cases interpretation error was found in 11 (73.33%) cases, sampling error in 3 (20%) and small tumor size in 1(6.67%) case. In a study of 100 cases of frozen sections by Patil P. et al the common causes of discrepant results seen were interpretation error (66.66%) and sampling error (33.34%).¹ While in the study by Ahmad Z. et al sampling error was the most frequent error (44.8%) encountered.⁸

Interpretation errors were the most common type of errors (73.33%) in the present study. This can be attributed to the freezing artefact which is an unwanted and unavoidable limitation of frozen section.³ Cellular swelling a common artefact in frozen sections often leads to a spurious impression of nucleomegaly and false positive diagnosis of malignancy.⁹ Technical aspects like embedding and sectioning were also found to contribute in interpretation errors. Rarity of a lesion can be a factor of misdiagnosis in the hand of inexperienced pathologists.

In a case received for primary diagnosis from the oral cavity the frozen section report was given as squamous cell carcinoma. This was a known and treated case of squamous cell carcinoma presenting with metastatic neck nodes. But as the tumor tissue was too small it got exhausted in the FS analysis and no tumor was found in the remnant tissue subjected for routine histology.

A case diagnosed as benign phyllodes tumor of breast turned out to be malignant phyllodes on conventional histopathology. This may be due to marked alteration in cellular morphology making it difficult to identify mitosis in stromal cells and to some degree in architectural morphology in frozen sections.

In a case of diffuse adenocarcinoma of stomach presenting with gastric outlet obstruction, surgical margin was sent for frozen section analysis. The proliferation of ganglion cells led to the misinterpretation of margin involved by tumor.

In ovarian lesions a case of mature teratoma was misinterpreted as immature teratoma as the chronic inflammatory cells were swollen giving an impression of the immature neuroectodermal element. The freezing artefacts also gave an overall immature look to different mesenchymal elements of the tumor.

Similarly freezing artefacts of the inflammatory cells and endothelial cells also led to overdiagnosis of a sample from liver and a suspicious omental nodule as metastatic deposits, which were later found to be free from tumor. Such problems also resulted in false positive diagnosis of surgical margins from breast tissue as involved by malignancy.

Error in tumor typing and grading was frequent in neurosurgical biopsies. Freezing artefacts are common cause of discrepancies in these cases. To reduce these fallacies some studies have recommended to study multiple bits from different areas of the lesion and to use squash cytology along with frozen section.³

We found errors of sampling in two cases of thyroid. False negative diagnosis of nodular goitre was given in a case of a medullary carcinoma and in a case of papillary microcarcinoma. Because the tumors in both

these cases were small and adequate radiological data was unavailable, the lesions were missed during sampling. More extensive sampling could have made a correct diagnosis.

Similarly sampling error was also found in a case of colorectal adenocarcinoma which was underdiagnosed as colorectal adenoma. This may be due to the fact that it was a polypoidal mass and the sample sent by the oncosurgeon was a diagnostic sample that did not reveal invasion even after multiple serial sections. But clear cut invasion by malignant cells was noted at other sites in routine histology.

Better communication between the operating surgeon and pathologist regarding clinical and radiological details, careful sampling by the surgeon and the pathologist, study of multiple sections, technical expertise and opinion by experienced pathologist(s) may limit the interpretation error and thus reduce the rate of false positive and false negative diagnosis.

Frozen sections are difficult to interpret. A pathologist should know precisely what to look for in the frozen section. The frozen diagnosis can be given as inflammatory, benign or malignant rather than the exact subtype which hardly alters the patient management.¹¹ If the situation warrants the diagnosis may be deferred and the surgery should be performed as if the frozen section has never been performed.¹²

V. Conclusion

Frozen section is an important tool to assist the surgeons in making intraoperative decisions. The errors and deferrals can be reduced by proper coordination between the surgeon and pathologist. Adequate clinical and radiological information, thorough macroscopic examination, careful sampling by the surgeon and the pathologist, properly trained technical staffs and interpretation by experienced pathologists can increase the diagnostic accuracy.

References

- [1]. Patil P, Shukla S, Bhake A, Hiwale K; Accuracy of frozen section analysis in correlation with surgical pathology diagnosis. *Int J Res Med Sci.* 2015 Feb ; 3(2) :399-404.
- [2]. Chandramouleeswari K, Yogambal M, Arunalatha P, Bose JC, Rajendran A; Frozen and paraffin sections - Comparative study highlighting the concordance and discordance rates in a tertiary care centre. *IOSR Journal of Dental and Medical Sciences (IOSR-JDMS)* 2013, Nov.- Dec.;12(5): 26-30
- [3]. Shrestha S, Lee MC, Dhakal H, Pun CB, Pradhan M, Shrestha S, Basyal R, Pathak T; Comparative Study of Frozen Section Diagnoses with Histopathology. *Post Graduate Medical Journal of NAMS.* 2009 July-Dec; 9(2):1-3
- [4]. Mishra S, Gupta M, Bharat V, Bansal R; Qualitative Comparative Study of Frozen Section with Routine Histological Technique. *National Journal of Laboratory Medicine.* 2016; Apr, Vol 5(2): 44-50
- [5]. de Silva RD, Souto LR, Matsushita GdeM, Matsushita MdeM; Diagnostic accuracy of frozen section tests for surgical diseases. *Rev. Col. Bras. Cir.* 2011; 38(3): 149-154
- [6]. Hatami H, Mohsenifar Z, Alavi SN; The Diagnostic Accuracy of Frozen Section Compared to Permanent Section: A Single Center Study in Iran. *Iran J Pathol.* 2015; 10(4): 295 – 299
- [7]. Gephardt GN, Zarbo RJ; Interinstitutional comparison of frozen section consultations: A College of American Pathologists Q-probes study of 90,538 cases in 461 institutions. *Arch Pathol Lab Med* 1997;120: 804-9.
- [8]. Ahmad Z, Barakzai MA, Idrees R, Bhurgri Y; Correlation of intra-operative frozen section consultation with the final diagnosis at a referral center in Karachi, Pakistan. *Indian Journal Of Pathology And Microbiology* 2008,- October-December;51(4): 469-473
- [9]. Agarwal P, Gupta S, Singh K, Sonkar AA, Rani P, Yadav S, Goel MM; Intra-Operative Frozen Sections: Experience at A Tertiary Care Centre; *Asian Pac J Cancer Prev* 2016; 17 (12): 5057-5061
- [10]. Chbani L, Mohamed S, Harmouch T, Fatemi H.E, Amarti A; Quality assessment of intraoperative frozen sections: An analysis of 261 consecutive cases in a resource limited area Morocco. *Health* 2012; 4(7):433-435
- [11]. Taxy JB; Frozen section and the surgical pathologist: a point of view. *Arch Pathol Lab Med.* 2009;133(7):1135-8.
- [12]. Khoo JJ; An audit of intraoperative frozen section in Johor. *Med J Malaysia.* 2004;59(1):50-5.

Dr Nageswar Sahu, " Evaluation of Intraoperative Frozen Sections: Experience in a Tertiary Care Hospital "IOSR Journal of Dental and Medical Sciences (IOSR-JDMS), vol. 17, no. 9, 2018, pp 24-28.