

Collagenous Fibroma: A Case Identified In Breast

Dr. Amitoj Sandhu, Dr. Jasmine Kaur, Dr. Samidha Jindal, Dr. R. K. Kundal,
Dr. Ramanpreet Kaur, Dr. Neetika Kaushal

Corresponding Author: Dr. Jasmine Kaur

Abstract: *Desmoplastic fibroma is a rare, benign soft-tissue tumor composed of spindled and stellate-shaped cells that are embedded in a dense collagenous stroma. The most common sites are the upper extremities, followed by the lower extremities. Rare lesions arise in the head and neck region. The present study describes the case of 56 year old female who presented with an inactive, firm painless swelling below the nipple areola complex in the left breast. A biopsy was performed and the result of the histopathological examination indicated a collagenous fibroma.*

Date of Submission: 28-08-2018

Date of acceptance: 10-09-2018

I. Introduction

Desmoplastic fibroma (collagenous fibroma) is a distinctive, rare, benign, slow-growing fibroblastic soft-tissue tumor that was first described by Evans in 1995. ⁽¹⁾The gross characteristics of the tumor are well circumscribed, with spindle to stellate fibroblasts dispersed in a fibromyxoid or densely fibrous matrix, with low mitotic activity. The condition was renamed 'collagenous fibroma' a year later by Nielson *et al.* ⁽²⁾It is a recently defined benign fibroblastic/myofibroblastic tumor. The lesion usually presents as a painless, firm, well-circumscribed subcutaneous mass of long standing duration and behaves in a benign fashion. ⁽³⁾The lesion is considered to be a neoplasm because of its association with the 11q12 breakpoints, a lack of inciting events, and the initiation of reactive fibrous proliferation. ⁽⁴⁾

II. Case Report

A 56 year old female was referred to a Department of Surgery, Rajindra Hospital, Government Medical College Patiala due to complaint of a firm, inactive, painless swelling below the nipple areola complex in the left breast. The patient had no complaint of pus or discharge from the swelling or the nipple areola complex. On examination no other swelling was found in either breast. The swelling was completely excised and specimen was sent to Department of Pathology, Rajindra Hospital, Government Medical College Patiala. The specimen was fixed in 10% formalin solution and subsequently embedded in paraffin. 5 micron sections were made and stained with H and E.

Gross Features

The tissue received after excisional biopsy was skin covered soft tissue piece measuring 1x0.7 cm.

Histopathological Features

Sections stained with H and E were observed under 4x, 10x, 40x to reveal a focus of lamellated keratin enclosed by stratified squamous epithelium with prominent granular layer exhibiting the features of epidermoid cyst. But underneath this was seen a well circumscribed lesion with bland stellate fibroblast in the background of prominent collagenous stroma.

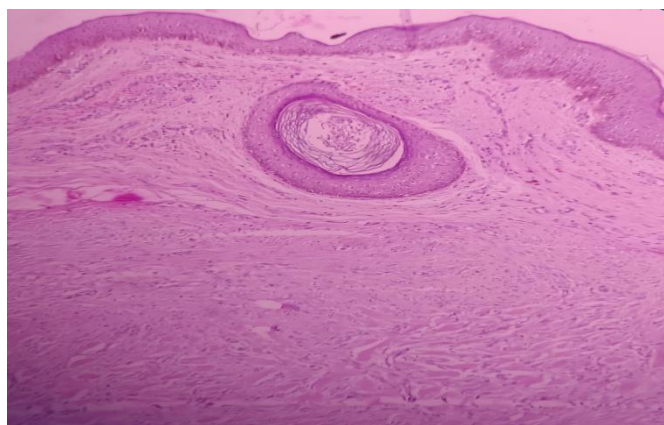


Figure 1: Section showing epidermoid cyst and underneath a well circumscribed lesion. (H and E, original magnification x100)

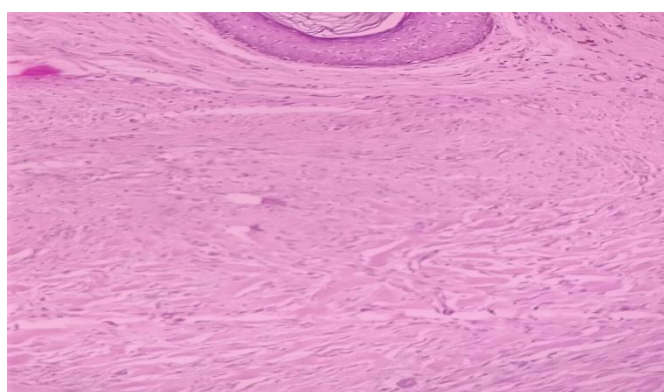


Figure 2: Section shows bland stellate or spindle fibroblast in background of prominent collagenous stroma. (H and E, original magnification x100)

III. Discussion

Collagenous fibroma is a benign fibrous soft tissue tumor typically arising in the subcutaneous tissue or skeletal muscle of adults. A wide age range is affected, but it is most common in the fifth through seventh decades. Men are affected four times more commonly than women. Collagenous fibroma has a wide anatomic distribution affecting mainly extremities and presents as a slowly growing, painless mass, ranging from 1 to 20 cm in maximum dimension.⁽⁵⁾Surgery is the treatment of choice, with no reported tumor recurrences.⁽⁶⁾DF represents a neoplasm, given that no inciting event was clinically mentioned and no specific cause for a reactive fibrous proliferation could be microscopically identified. Furthermore, a cytogenetically abnormal clone, involving the 11q12 breakpoint, was detected in some cases, corroborating with the neoplastic nature of the DF.⁽⁷⁾Histologically, the tumors often appear well delineated under a low power microscope. The tumor cells are relatively stellate or bland spindle fibroblasts separated by a collagenous or myxocollagenous matrix. These fibroblasts lack any atypical or hyperchromatic nuclei. Mitotic activity is either absent or minimal. Ultrastructurally and immunohistochemically the tumor cells present features compatible with a fibroblastic/myofibroblastic profile.⁽⁸⁾The cells are positive for vimentin, and focal immunoreactivity to SMA and muscle-specific actin. Immunostaining for desmin, S100 protein, CD34, and EMA is negative.⁽⁹⁾Evans suggested that the most significant differential diagnostic consideration was that of a desmoid tumor, as it may have similar cytological features and is often locally aggressive.⁽¹⁰⁾Alberghini *et al* reported that desmoplastic fibroma is a myofibroblastic lesion, ultrastructurally demonstrating the presence of fibronexus junctions. Immunohistochemical studies reveal prominent myofibroblastic differentiation, which typically presents on the cytoplasmic membranes of the cells, while a desmoid tumor is fibroblastic. This ultrastructural finding is significant in the differential diagnosis between a desmoplastic fibroma and a desmoid tumor.⁽¹¹⁾ When fibrous tumors were considered as differential diagnosis, the possibility of the tumor being juvenile hyaline fibromatosis had to be ruled out. They are formed by fibroblast cells with areas of amorphous hyaline material. Differentiating between fibromatosis and CF only by microscopic examination is difficult due to their histologic similarity. Fibromatosis are locally aggressive infiltrating fibroblastic tumors with frequent recurrences.

However, our case presented as a benign, well-defined, circumscribed mass with no attachment to the overlying or underlying structures.⁽¹²⁾

IV. Conclusion

Soft tissue tumors are relatively common, but frequently represent a diagnostic problem for pathologists due to the similarity in histological aspects and an overlap in the staining profile among cells with fibroblastic and myofibroblastic differentiation. Differential diagnosis in this as includes simple fibroma, desmoid tumor, juvenile hyaline fibromatosis. Correct management is dependent on pathologist being familiar in varied microscopic appearances. Close clinico-pathological correlation is advised in fibrous lesions of breast.

References

- [1]. Nishio J, Akiho S, Iwasaki H and Naito M: Translocation t(2;11) is characteristic of collagenous fibroma (desmoplastic fibroblastoma). *Cancer Genet* 204: 569-571, 2011
- [2]. Nielsen GP, O'Connell JX, Dickersin GR and Rosenberg AE: Collagenous fibroma (desmoplastic fibroblastoma): a report of seven cases. *Mod Pathol* 9: 781-785, 1996.
- [3]. Miettinen M, Fetsch JF. Collagenous fibroma (desmoplastic fibroblastoma): A clinicopathologic study of 63 cases of a distinctive soft tissue lesion with stellate-shaped fibroblasts. *Hum Pathol*1998;29:676-82.
- [4]. Bernal K, Nelson M, Neff JR, Nielsen SM, Bridge JA. Translocation (2;11)(q31;q12) is recurrent in collagenous fibroma (desmoplastic fibroblastoma). *Cancer Genet Cytogenet*2004;149:161-3.
- [5]. M. Miettinen and J. F. Fetsch, "Collagenous fibroma (desmoplastic fibroblastoma): a clinicopathologic analysis of 63 cases of a distinctive soft tissue lesion with stellate-shaped fibroblasts," *Human Pathology*, vol. 29, no. 7, pp. 676–682, 1998.
- [6]. R. Sciot, I. Samson, H. van den Berghe, B. Van Damme, and P. Dal Cin, "Collagenous fibroma (desmoplastic fibroblastoma): genetic link with fibroma of tendon sheath?," *Modern Pathology*, vol. 12, no. 6, pp. 565–568, 1999.
- [7]. Dernal K, Nelson M, Neff JR, et al. Translocation (2;11)(q31;q12) is recurrent in collagenous fibroma (desmoplastic broblastoma). *Cancer Genet Cytogenet.* 2004;149:161–3.
- [8]. Evans HL. Desmoplastic fibroblastoma. A report of seven cases. *Am J Surg Pathol*1995;19:1077-81.
- [9]. Miettinen M, Fetsch JF. Collagenous fibroma (desmoplastic fibroblastoma): A clinicopathologic study of 63 cases of a distinctive soft tissue lesion with stellate-shaped fibroblasts. *Hum Pathol*1998;29:676-82.
- [10]. Evans HL: Desmoplastic fibroblastoma. A report of seven cases. *Am J Surg Pathol* 19: 1077-1081, 1995.
- [11]. Alberghini M, Pasquinelli G, Zanella L, *et al*: Desmoplastic fibroblastoma: a light and ultrastructural description of two cases. *UltrastructPathol* 28: 149-157, 2004.
- [12]. de Sousa SF, Caldeira PC, Grossmann Sde M, de Aguiar MC, Mesquita RA. Desmoplastic fibroblastoma (collagenous fibroma): A case identified in the buccal mucosa. *Head Neck Pathol*2011;5:175-9.

Dr. Amitoj Sandhu." Collagenous Fibroma: A Case Identified In Breast."IOSR Journal of Dental and Medical Sciences (IOSR-JDMS), vol. 17, no. 9, 2018, pp 43-45.