

## Intramuscular Myxoma: A Rare Mesenchymal Tumor of Thigh

Banwari lal<sup>1</sup> virendra gandhi<sup>2</sup>

<sup>1</sup>(Consultant surgeon, Hitkari hospital balotra barmer raj, India)

<sup>2</sup>(Consultant, Hitkari hospital balotra barmer raj, India)

Corresponding Author: Banwari lal

---

**Abstract : Introduction:** Intramuscular myxoma is a rare benign soft tissue tumor of the musculoskeletal System. The reported incidence is varying from 0.1 to 0.13 per 100,000 population. Most patients present between the fifth to seventh decades of life. The tumor commonly occurs in the large muscles of the thigh, shoulder, buttocks and arms. The tumor can be diagnosed with certainty only with histopathological examination. Post surgical recurrence is rare.

**Case report:** A 60 year old female presented with a swelling of the anteromedial aspect of middle third of right thigh measuring about 6×10 centimeters. She was thoroughly investigated and tumor surgically excised. The excised lesion was found intramuscular myxoma on histopathological examination.

**Conclusion:** this case is being reported since the tumor is rare and also an important consideration in the differential diagnosis of sarcomas, intramuscular lipoma, hematoma, and desmoid tumor. Important feature is that definitive diagnosis made only after excision by histopathological examination.

**Keywords-** soft tissue tumor, benign, intramuscular myxoma, thigh

---

Date of Submission: 28-08-2018

Date of acceptance: 10-09-2018

---

### I. Introduction

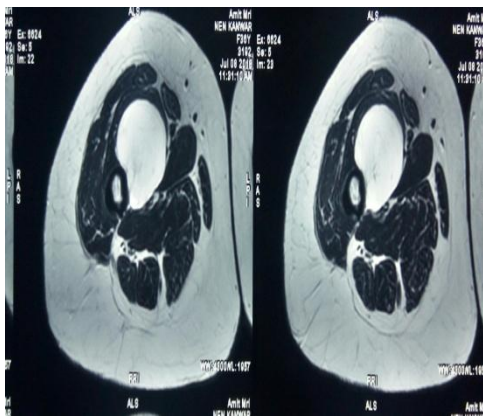
Intramuscular myxoma is a benign soft tissue tumor of mesenchymal origin. It is a rare tumor of unknown etiology. The incidence is between 0.1 and 0.13 in every 100,000 individuals. It occurs usually between the fourth and seventh decades of life and predominantly in women (70%)<sup>1</sup>. Myxoma originates from primitive mesenchymal cells, which lose their capacity to produce collagen, but produce excess hyaluronic acid and immature collagen fibers.<sup>2</sup>

They are characterized by slow growth. The most common location of myxoma is the cardiac muscle, where they account for 50% of all benign lesions.<sup>3</sup> Next to cardiac muscle, more than a half of all myxomas can be found within thigh muscles. Less frequent locations are: the buttocks, shoulder girdle, shank, arm and trunk. In very rare cases these tumors may also be located within the neck.<sup>4</sup>

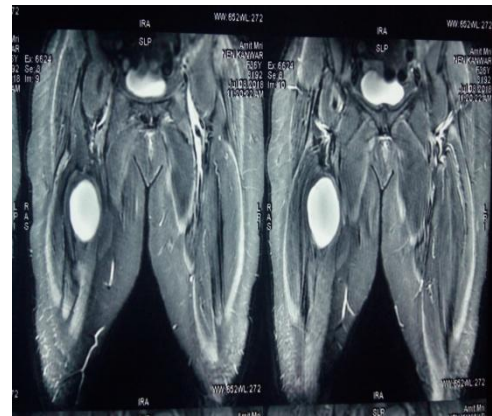
### II. Case report

A 60 year old female patient presented to us with a swelling of right thigh. The swelling was painless and progressively increasing in size since last 6 months. The swelling was firm in consistency and mobile, measuring 6×10 cm in size. Its size reduced on active muscle contraction. The patient was investigated thoroughly with routine blood investigations and MRI of thigh. MRI revealed a mass, measuring 5×5×8 cm in vastus medialis muscle in middle 1/3 of right thigh with no major neurovascular involvement (fig.1&2). Other pre operative blood investigations were normal.

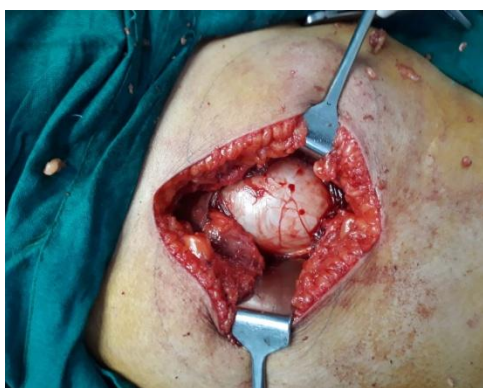Surgical excision of tumor was done, taking care of vessels and nerves. Excised tumor was encapsulated soft cystic mass. (fig.3&4) In post operative period there was no complication and patient discharged in couple of days under satisfactory conditions. Histopathological examination revealed on gross examination; cut section shows gray-white glistening gelatinous areas. Microscopy showed abundant mucoid material with relative hypo cellularity, consistent with a myxoma. No significant mitotic activity was noted and it was encapsulated in bundles of striated muscles.



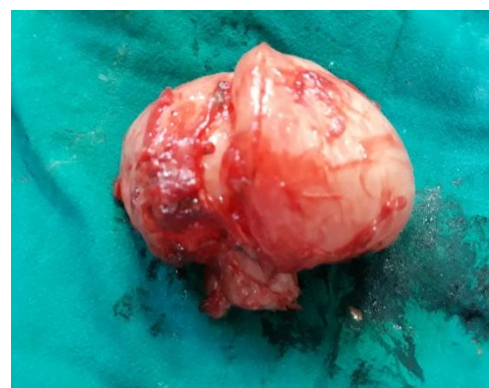**Fig.1;**MRI scan showing the intramuscular lesion in axial section.



**Fig.2;**MRI scan showing the lesion in sagittal plan in T2 weighted image



**Fig3;** intraoperative picture showing intra muscular lesion



**Fig 4;** gross specimen of lesion showing glistening capsule

### III. Discussion

In 1863, Virchow introduced term myxoma to describe a mesenchymal tumor, which histologically resembles the umbilical cord, with no other differentiation.<sup>5</sup> The histological criteria for diagnosing a myxoma were established by Stout in 1948, who defined myxoma as “a true neoplasm composed of a paucity of stellate cells in a loose myxoid stroma of reticulin and collagen fibres” (Murphey et al.)<sup>6</sup>

Myxoma is a benign tumor of mesenchymal origin composed of undifferentiated stellate cells within a myxoid tissue<sup>6</sup>. Besides cardiac muscle locations, skeletal muscle involvement is most common in the muscles of the thigh, but may affect other muscles and may be in intramuscular, para-articular or sometimes subcutaneous location<sup>6</sup>. There is a slight female preponderance. The tumor may occur in association with fibrous dysplasia or Albright syndrome<sup>7</sup>. When there are multiple tumor, and associated with fibrous dysplasia, called mazabraud’s syndrome<sup>8</sup>.

The current modes of imaging are ultrasound, CT and MRI. Intramuscular myxoma appears as a hypo echoic lesion with well defined margins, on ultrasound. On CT intramuscular myxoma usually present as a well defined homogenous low density lesion. On MRI the tumor usually appears as low signal intensity on T1 weighted images and high signal intensity on T2 weighted, gradient echo or STIR images<sup>9</sup>. Grossly tumor is oval or spherical in shape. On cut open, it has a white or grey-white mucoid gelatinous surface. Although it appears well capsulated, the delicate fibrous capsule is usually incomplete and most lesions infiltrate adjacent musculature.<sup>2</sup> On microscopic examination, there is abundant mucoid material, relative hypo cellularity and loose reticulin fibers. Vascular structures are sparse. Stellate shape cells with small hyper chromatic pyknotic nuclei and scanty cytoplasm. Some myxomas may show focal areas of hyper cellularity. Absence of nuclear atypia, mitotic figures or necrosis helps to rule out malignancy. Mucoid material stain positively for alcian blue, mucicarmine and colloidal iron.<sup>8</sup>

The tumor is to be differentiated from soft tissue Sarcomas, metastasis, and other benign tumors such as lipoma, hemangioma, hematoma, desmoid tumor.<sup>10</sup> Histopathological diagnosis is recommended with fine needle aspiration cytology or open biopsy, prior to surgery. Surgical excision is curative. Recurrence is very rare.<sup>7, 10</sup>

#### **IV. Conclusion**

This is a very rare tumor of mesenchymal origin, of unknown etiology, which appears in the long muscles of the extremities or pelvis. It is usually a single lesion, but the presence of multiple lesions could suggest part of a syndrome. Surgery is the treatment of choice, there is no risk of malignancy. Recurrence is rare and due to incomplete excision of the lesion. The definitive diagnosis is histopathological.

#### **References**

- [1]. Ortiz J, Abad MM, Garcia Macias C, Bullon A. Mixoma intramuscular: hallazgos citológicos en material obtenido por punción aspiración con aguja fina. *Rev Esp Pat.* 1997;30:264---6.2
- [2]. Tan HM , Peh WC , Shek TW . A distinctive shoulder mass. *Br J Radiol* 2001; 74:1159–1160.
- [3]. Reynen K. Cardiac myxomas. *N Engl J Med* 1995; **333:1610–7**.
- [4]. Allen P. Myxoma is not a single entity: a review of the concept of myxoma. *Ann Diagn Pathol* 2000;**4:99–123**.
- [5]. Virchow's R. Cellular pathology as based upon physiological and pathological histology. Nueva York: Dover Publications Inc;1971. p. 525---
- [6]. Murphey MD, McRae GA, Fanburg-Smith JC, Temple HT, Levine AM, Aboufalia AJ. Imaging of soft-tissue myxoma with emphasis on CT and MR and comparison of radiologic and pathologic findings. *Radiology.* 2002;225:215---24.
- [7]. Robert J Logel. Recurrent Intramuscular myxoma associated with Albright's Syndrome: *Journal of Bone and Joint Surgery: Vol 58-A, NO. 4:565-568.*
- [8]. Kabukcuoglu F, Kabukcuoglu Y. Mazabraud's syndrome: Intramuscular myxoma associated with fibrous dysplasia. *Orphanet Encyclopedia.* Jan 2005.
- [9]. PN Chan, SF Lee, TC Chow, YL Chan. A rare benign tumour –Intramuscular Myxoma. *J HK Coll Radiol* 2004;7:40-3.
- [10]. Ozbek N, Danaci M, Okumus B, Gursel B, Cakir S, Dabak N, Karagoz F. Recurrent intramuscular myxoma: review of the literature, diagnosis and treatment options. *Turk J Cancer.* 2006;36(2):75.

Banwari Lal." Intramuscular Myxoma: A Rare Mesenchymal Tumor of Thigh". *IOSR Journal of Dental and Medical Sciences (IOSR-JDMS)*, vol. 17, no. 9, 2018, pp 36-38.