

## OCULO-Orbital Manifestations of Crouzon Syndrome- A Rare Case Report

B. Sireesha<sup>1</sup> and Hari Priya<sup>2</sup>

Corresponding Author: B.Sireesha

---

**Abstract:** Crouzon syndrome is a rare genetic disorder characterized by craniosynostosis showing premature closure of one or more cranial sutures leading to skull deformities. It commonly has autosomal dominant inheritance with complete penetrance and variable expressivity. It is characterized by brachycephaly, shallow orbits resulting in ocular proptosis with or without divergent strabismus, orbital hypertelorism, hypoplasia of maxilla and bifid uvula. Our paper reports the diagnosis of this rare syndrome in a 8 year old male child based on clinical features.

**Key Words:** Craniofacial dysostosis, craniosynostosis, crouzon syndrome, exophthalmos.

---

Date of Submission: 11-12-2019

Date of Acceptance: 26-12-2019

---

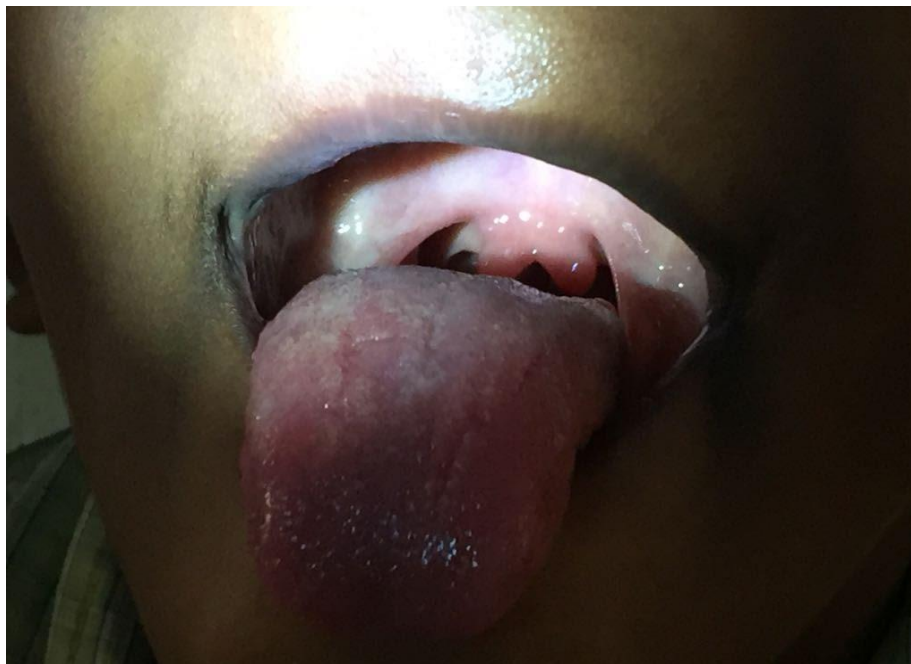
### I. Introduction

Premature fusion of one or more sutures results in craniofacial malformation called craniosynostosis. Craniosynostosis restricts the growth of the brain perpendicular to the suture, and so compensatory growth takes place in the direction of open sutures<sup>1</sup>. It is one of the craniosynostosis syndromes that is caused by a mutation in the fibroblast growth factor receptor 2 gene (FGFR2). It accounts for approximately 4.8% of all cases of craniosynostosis making it the most common syndrome within the craniosynostosis group. It has worldwide prevalence rate of approximately 1 per 25,000 live births<sup>2</sup>.

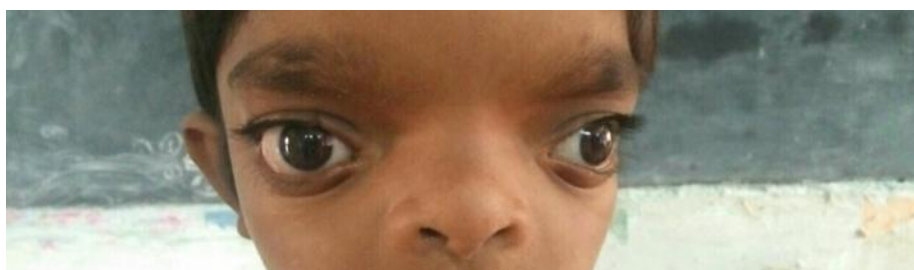
### II. Case Report

The diagnosis and management of craniofacial abnormalities have always been a challenge therefore understanding of these abnormalities is necessary to monitor subsequent growth and to ensure that the patient receives the best available care. Herein, we report this rare entity of Crouzon syndrome showing characteristic features with oculo-orbital abnormalities.

A 8 years old male child presented to departmental OPD with complaint of outward protrusion of both eyeballs present since birth. Detailed family and medical history was taken which revealed mother had normal hospital based vaginal delivery. In family, sibling and near relatives are normal. On examination, it was noted that head was elliptical in shape with broad nasal bridge, high arched palate, bifid uvula and low set of ears (FIGURE 1). On local examination, patient had bilateral proptosis, hypertelorism and divergent squint (FIGURE 2). Anterior segment including pupil was normal. Fundus showed clear media with hyperemic disc, absence of physiological cup with normal macular reflex. Patient was started on lubricating eye drops and ointment to prevent exposure keratopathy and advised close follow-up. Child was referred to Paediatrician and Neurosurgeon for further management.



**FIGURE 1: High arched palate and bifid uvula**



**FIGURE 2: Bilateral proptosis, hypertelorism and broad nasal bridge.**

### **III. Discussion**

Octave Crouzon in 1912 first described Crouzon's syndrome. It is a rare genetic disorder with autosomal dominant inheritance with the prevalence of 16.5 per million newborns. More than 90% of cases occur due to mutations in fibroblast growth factor gene (FGFR2) which maps to chromosome 10p 25-q26<sup>2</sup>. Early prenatal diagnosis such as prenatal DNA testing for mutation of FGFR-2 gene and prenatal ultrasonography may be useful in providing indications of forthcoming developmental problems, thus providing the option of termination or optimal postnatal management for families who choose to continue the pregnancy<sup>3</sup>. The management of CS requires a multidisciplinary approach for successful outcome. The goal is to stage reconstruction to coincide with facial growth patterns, visceral function, and psychosocial development<sup>4</sup>. Surgical treatment varies according to the variable expressivity of the disease and usually begins during a child's first year with fronto-orbital advancement with cranial decompression<sup>5</sup>. Early craniectomy with frontal bone advancement is most often indicated to prevent or treat increased intracranial pressure because newborns with Crouzon syndrome develop multiple suture synostoses and fused synchondroses<sup>2</sup>.

### **IV. Conclusion**

Management of patients with crouzon syndrome requires multidisciplinary approach and early diagnosis is important. Increased intracranial pressure leading to optic atrophy may occur, which produce blindness if the condition is not treated. Timely decompression may prevent optic neuropathy and any visual loss. Our patient showed characteristic features of Crouzon syndrome and was reported with no signs of raised intracranial pressure or optic atrophy hence was referred to neurosurgeon for further management and to prevent any further sequelae of dysostosis.

### References

- [1]. Kalanjiam V, Manoharan GVMG. Crouzon syndrome - A rare case report. *Int J Health Sci (Qassim)*. 2017;11(4):74–5
- [2]. Mohan RS, Vemanna NS, Verma S, Agarwal N. Crouzon Syndrome: Clinico-Radiological Illustration of a Case. *J Clin Imaging Sci*. 2012;2(4):70.
- [3]. Phupong V, Srichomthong C, Shotelersuk V. Prenatal exclusion of Crouzon syndrome by mutation analysis of FGFR2. *Southeast Asian J Trop Med Public Health* 2004;35:977-9
- [4]. Stephanie Gonçalves Carneiro, Dorivaldo Lopes da Silva, Angélica Cristina Pezzin Palheta, Francisco Xavier Palheta Neto, Cláudio Tobias Acatauassú Nunes, Thaís Oliveira Ferreira, et al. Crouzon’s syndrome literature review. *Intt Arch Otorhinolaryngol Sao Paulo* 2008;12:436-41
- [5]. Taglialatela Scafati C, Aliberti F, Taglialatela Scafati S, Mangone GM, Taglialatela Scafati M. The value of the maxillo-malar osteotomy in the treatment of Crouzon syndrome with exorbitism. *Ann Plast Surg* 2008;61:285-9.

B.Sireesha. “OCULO-Orbital Manifestations of Crouzon Syndrome- A Rare Case Report.”  
IOSR Journal of Dental and Medical Sciences (IOSR-JDMS), vol. 18, no. 12, 2019, pp 12-14.