

Diagnostic Accuracy of Echogenicity as an Ultrasound Parameter for Determination of Malignancy in Solitary Thyroid Nodules

Dr. Megha Kumra¹, Dr. Sneha Karwa², Dr. D.L Lakhkar³

¹(Resident, Department of Radiodiagnosis, DVVPPF's Medical College and Hospital, Ahmednagar, Maharashtra)

²(Resident, Department of Radiodiagnosis, DVVPPF's Medical College and Hospital, Ahmednagar, Maharashtra)

³(Professor & Head, Department of Radiodiagnosis, DVVPPF's Medical College and Hospital, Ahmednagar, Maharashtra)

Abstract: Thyroid nodule is one of the most common finding on neck ultrasound examinations. It is a common term which includes a variety of pathological types under it, ranging from benign to malignant. A solitary thyroid nodule is seen with high suspicion and patients are subjected to further imaging and pathological analysis. Sonography is a safe, non-invasive modality to visualize these nodules and their characterization can be done based on their morphological features. Distinguishing benign from malignant lesions is a desirable outcome of ultrasonographic examinations that allows early diagnosis and timely management of malignant lesions, also avoids unnecessary procedural burden in case of benign lesions. Thyroid nodules are assessed by not one but a combination of morphological parameters to reach a diagnosis. The present study was undertaken to study "Echogenicity" of these nodules as a diagnostic parameter to detect malignant lesions on ultrasound. 50 cases of solitary thyroid nodules were studied on ultrasound and were followed up on cytopathology. It was concluded that hypo-echogenicity of the nodule was highly specific and accurate for malignancy with a high negative predictive value.

Date of Submission: 26-11-2019

Date of Acceptance: 10-12-2019

I. Introduction

Diseases affecting thyroid gland have varied manifestations, of which thyroid nodules are very common. They are commonly found entities in day to day practice. They are either found at the time of clinical examination or incidentally during imaging procedures. The method of identification of thyroid nodules invariably determines their prevalence. While imaging gives an evidential proof of their presence, the estimated prevalence by palpation ranges from only 4% to 7%.^{1,2}

Thyroid nodules pose a diagnostic challenge in clinical practice when it comes to labeling a nodule as benign or malignant.³ Since the treatment and prognosis of both differ significantly, it becomes crucial to identify and differentiate them with the help of their characteristic imaging findings along with clinico-pathological support and manage them accordingly.

Overall thyroid nodules have low risk of malignancy; however they can transform into various malignancies like papillary carcinoma, follicular carcinoma. A solitary thyroid nodule is more likely to be malignant

Ultrasonography is the first line of investigation for detection of thyroid nodules and further characterization. Ultrasound is a real time, non-invasive imaging tool in the detection and characterization of diseases. It is also the imaging modality of choice for early detection and differentiation of thyroid nodules into benign and malignant

Apart from imaging, FNAC is an accurate diagnostic method to diagnose thyroid nodules. FNAC done under ultrasound guidance yields better results especially in patients who are having non-palpable or multiple or heterogeneous nodules. It is also helpful to target the solid part of lesion and aspirating from particular part of the large solid-cystic nodule. US guidance is also beneficial when the nodule is difficult to palpate in patients with diffuse disease or obesity. US-guided FNAC reduces the rate of non-diagnostic aspirates. Various Ultrasound and Doppler features suggest high chances of benignity or malignancy but no single feature is sufficient to diagnose with confidence. However a combination of features can be used to make a probable diagnosis and suggest pertaining risk of malignancy in the thyroid nodule.⁴ These include Number, Size, Shape, Margins, peripheral halo, Internal component, Echogenicity, Calcifications, Vascularity, cervical lymph node enlargement with loss of fatty hilum, honey combing and comet tail artefact etc. Out of these, the

echogenicity of the thyroid nodules was tested in the present study, pertaining to its heterogeneous nature, thus posing a practical difficulty while assessing a nodule and raising a suspicion of malignancy in it.

II. Material And Methods

50 patients were retrospectively studied who had undergone thyroid ultrasound in the department of radio-diagnosis and were diagnosed with a solitary thyroid nodule and had also undergone subsequent FNAC examination. Study was carried out by evaluating their hospital records, Ultrasound images and pathological reports. Patients of all age groups and genders were included. Written informed consent had been obtained from patients at the time of USG examination and FNAC. These patients were scanned using Mindray DC -7 and GE logic F6 with linear array high frequency probe 4-11 MHz.

All cases were scrutinized for the type of echogenicity of the nodule that was reported at the time of ultrasonographic diagnosis. They were either hypoechoic, hyperechoic, isoechoic, anechoic when compared to normal thyroid parenchyma.

When the echogenicity of solid component was mixed, the echogenicity was defined by predominant echogenicity of the nodule. In cases of predominantly cystic nodules echogenicity of solid component was assigned as echogenicity of nodule. As hypoechogenicity is established as a more probable feature in most of the thyroid malignancies, the lesions were divided into two groups- Hypoechoic nodules, Non-hypoechoic nodules which included isoechoic, hyperechoic and anechoic nodules.

FNAC report of each nodule was then correlated with the ultrasonographic diagnosis and accordingly were divided into two groups- benign and malignant.

Statistical analysis was done by calculating specificity, sensitivity, positive predictive value, negative predictive value and accuracy of Echogenicity as a parameter in determining malignancy in the nodule

III. Results

Out of 50 patients, on Ultrasound, 32 patients i.e., 64% of patients had isoechoic nodules followed by 12 (24%) patients had hypoechoic, 5 patients i.e., 10% of patients had anechoic nodules, one patient i.e., 2% of patients had hyperechoic nodule

Table No. 1: Distribution of Echogenicity of the thyroid nodules on Ultrasound

Echogenicity of nodules	Number	Percentage
Anechoic	05	10%
Hypoechoic	12	24%
Isoechoic	32	64%
Hyperechoic	01	2%
Total	50	100%

Graph No. 1: Distribution of Echogenicity of the thyroid nodules on Ultrasound

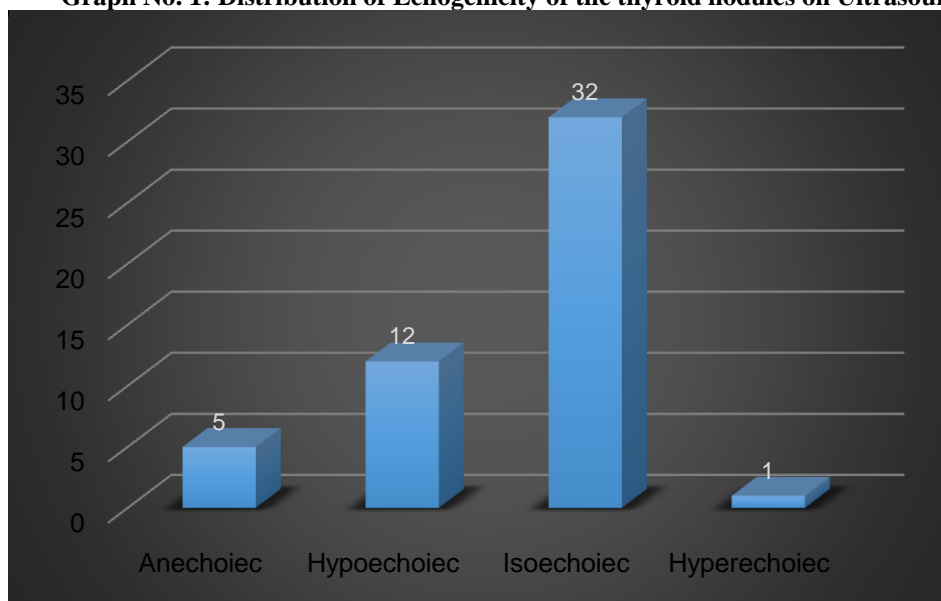


Table No. 2: Distribution of Echogenicity of the thyroid nodules based on FNAC Diagnosis

Echogenicity on USG	Total Number on USG	On FNAC			
		Benign		Malignant	
		Number	Percentage	Number	Percentage
Anechoic	05	05	11.4%	0	0%
Hypoechoic	12	08	18.2%	4	66.7%
Isoechoic	32	30	68.2%	2	33.3%
Hyperechoic	01	01	2.2%	0	0%
Total	50	44	100%	06	100%

Graph No. 2 : Distribution of Echogenicity of the thyroid nodules based on FNAC Diagnosis

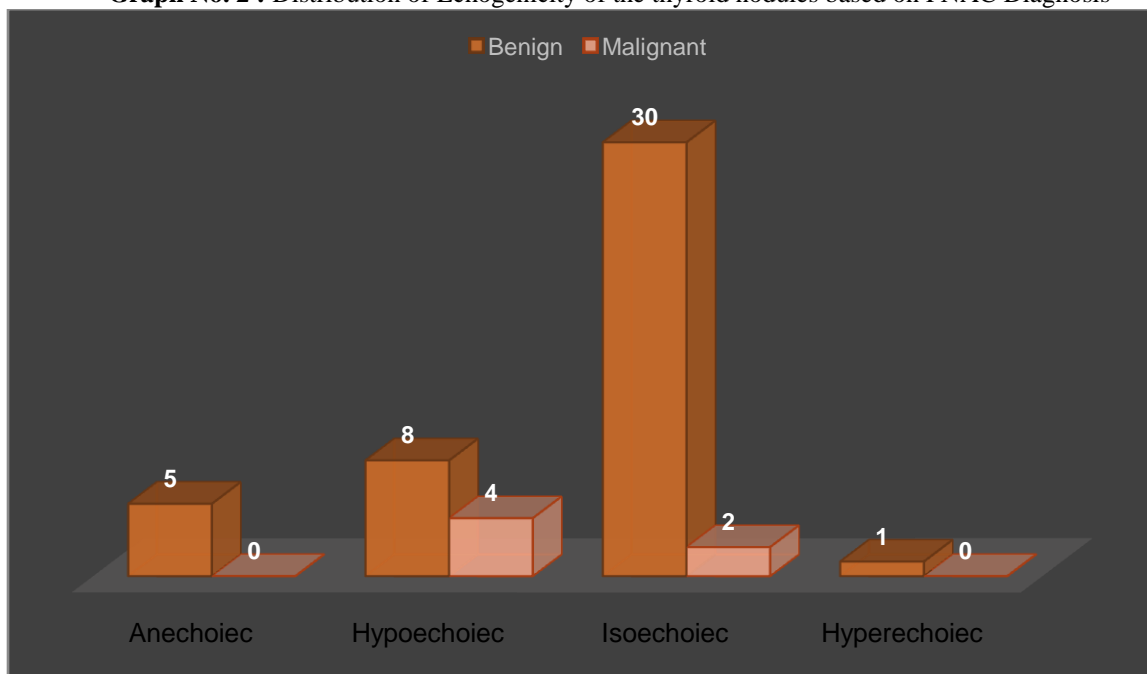


Table No. 2 shows that, all the anechoic 5 (10%) and hyperechoic 1(2%) nodules were found to be benign on FNAC. Out of 6 malignant lesions on FNAC, 4 (66.67%) were hypoechoic, 2 (33.3%) were isoechoic. Out of 44 benign lesions on FNAC, 30 (68.2%) were isoechoic and 08 (18.2%) were hypoechoic. Thus the benign lesions were predominantly isoechoic whereas, malignant lesions were commonly hypoechoic.

Table No. 3(a): Diagnostic values of hypoechogenicity on ultrasound in assessment of malignancy in thyroid nodules

USG Parameter	No. of malignant nodules on FNAC	No. of benign nodules on FNAC	Total
Nodules with hypoechogenicity	04	08	12
Nodules not showing hypoechogenicity (anechoic, isoechoic, hyperechoic)	02	36	38
Total	06	44	50
$\chi^2 = 6.8049$; $df = 1$, $p = 0.009091$ (Significant)			

Table No. 3(b): Diagnostic accuracy of hypoechogenicity on ultrasound in assessment of malignancy in thyroid nodules

Sensitivity	Specificity	Positive predictive value	Negative predictive value	Accuracy
66.67%	81.82%	33.33%	94.74%	80%

Table No. 3 shows that the sensitivity of hypoechogenicity on USG for diagnosis of malignancy was (66.67%) and the specificity was 81.82% with diagnostic accuracy of 80%. There was a significant association found between hypoechogenicity and malignancy (p -value=0.009091)

IV. Discussion

A thyroid nodule is defined as a discrete lesion within the thyroid gland that is distinguishable from the adjacent parenchyma at USG.⁵ Thyroid nodular disease is characterized by the presence of one or more palpable or non-palpable nodules within the substance of the thyroid gland. Thyroid nodules are one of the most common presentations of many benign and malignant thyroid diseases.⁶

On ultrasonography, a thyroid nodule is assessed by looking at its morphology and various parameters are considered to label it as a benign or malignant nodule. These include size, shape, margins, echogenicity, halo, vascularity, microcalcifications etc. Out of these, diagnostic accuracy of Echogenicity as a parameter has been studied by us.

In present study, which compared USG and FNAC diagnosis, out of 6 malignant lesions on FNAC, 4 (66.67%) were hypoechoic, 2 (33.3%) were Isoechoic. All the 5 anechoic (10%) and 1 hyperechoic (2%) nodules were found to be benign on FNAC. Out of 44 benign lesions on FNAC, 30 (68.2%) were isoechoic and 08 (18.2%) were hypoechoic. Thus the benign lesions were predominantly isoechoic whereas, malignant lesions were commonly hypoechoic. The sensitivity of hypoechoic nature on USG for diagnosis of malignancy was (66.67%) and the specificity was 81.82% with diagnostic accuracy of 80%.

Positive predictive value was found out to be 33.33% while there is a high Negative predictive value of 94.74%. There was a significant association found between hypoechoic nature and malignancy ($p\text{-value}=0.009091$).

Cappelli et al.⁷ in his study found out that hypoechoic nodules had 81% sensitivity, 47% specificity, 7% positive predictive value, 98% negative predictive value in detecting malignancy in thyroid nodules.

Prasad CV⁸ in his study found that, hypo echoic nature of the lesion could detect malignancy with a sensitivity, specificity, positive predictive value, negative predictive value of 72%, 88% 67% and 90% respectively.

Palaniappan et al.⁹ also showed that the risk of malignancy in hypoechoic nodules is about 6 times higher than the iso-hyperechoic nodules. They state that hypoechoic nature is an important feature in determining the malignancy risk and found significant association of hypoechoic nature with malignancy in their study.

Thus to summarise, as per our study, the sensitivity of hypoechoic nature on USG for diagnosis of malignancy is (66.67%) and the specificity is 81.82% with diagnostic accuracy of 80%. Positive predictive value is 33.3% while there is a high Negative predictive value of 94.74%. Also there is a significant association found between hypoechoic nature and malignancy ($p\text{-value}=0.009091$).

V. Conclusion

Detecting malignancy in a thyroid nodule is of utmost importance for timely management. Ultrasound is, efficient, easily available and cost effective modality to evaluate the thyroid nodules however a number of variations are seen in their morphology making the diagnosis less confident. A number of parameters are looked for while assessing a thyroid nodule. Hypoechoic nature of the nodule was found highly specific for malignancy with a high diagnostic accuracy and a high Negative Predictive value.

While the current study only tested Echogenicity of a nodule, a combination of all other morphological parameters like size, shape, margins, vascularity, calcifications etc. also needs to be taken into consideration while assessing a thyroid nodule, which raises the accuracy of a diagnosis.

References

- [1]. Singer PA, Cooper DS, Daniels GH, et al. Treatment guidelines for patients with thyroid nodules and well-differentiated thyroid cancer. American Thyroid Association. Archives of Internal Medicine. 1996; 156(19):2165-2172.
- [2]. Mazzaferri EL. Management of a solitary thyroid nodule. N Engl J Med. 1993; 328(8):553-9.
- [3]. Polyzos SA, Kita M, Efstathiadou Z, Goulis DG, Benos A, Flaris N, et al. The use of demographic, ultrasonographic and scintigraphic data in the diagnostic approach of thyroid nodules. Exp Clin Endocrinol Diabetes. 2009 Apr; 117(4):159-64.
- [4]. Morris LF, Ragavendra N, Yeh MW. Evidence-based assessment of the role of ultrasonography in the management of benign thyroid nodules. World J Surg. 2008 Jul; 32(7):1253-63.
- [5]. Popli MB, Rastogi A, Bhalla P, Solanki Y. Utility of gray-scale ultrasound to differentiate benign from malignant thyroid nodules. Indian J Radiol Imaging. 2012 Jan; 22(1):63-8.
- [6]. Cooper DS, Doherty GM, Haugen BR, Kloos RT, Lee SL, Mandel SJ. Revised American Thyroid Association Management Guidelines for Patients with Thyroid Nodules and Differentiated Thyroid Cancer. Thyroid 2009; 19(11):1167-214.
- [7]. Cappelli C, Castellano M, Pirola I, Cumetti D, Agosti B, Gandossi E, et al. The predictive value of ultrasound findings in the management of thyroid nodules. QJM. 2007 Jan; 100(1):29-35.
- [8]. Prasad CV. Evaluation of correlation between ultrasonography and FNAC of thyroid nodules. IAIM, 2016; 3(2):92-97.
- [9]. Palaniappan MK, Aiyappan SK, Ranga U. Role of Gray Scale, Color Doppler and Spectral Doppler in Differentiation Between Malignant and Benign Thyroid Nodules. Journal of Clinical and Diagnostic Research. 2016 Aug; 10(8):TC01-TC06.

Cases

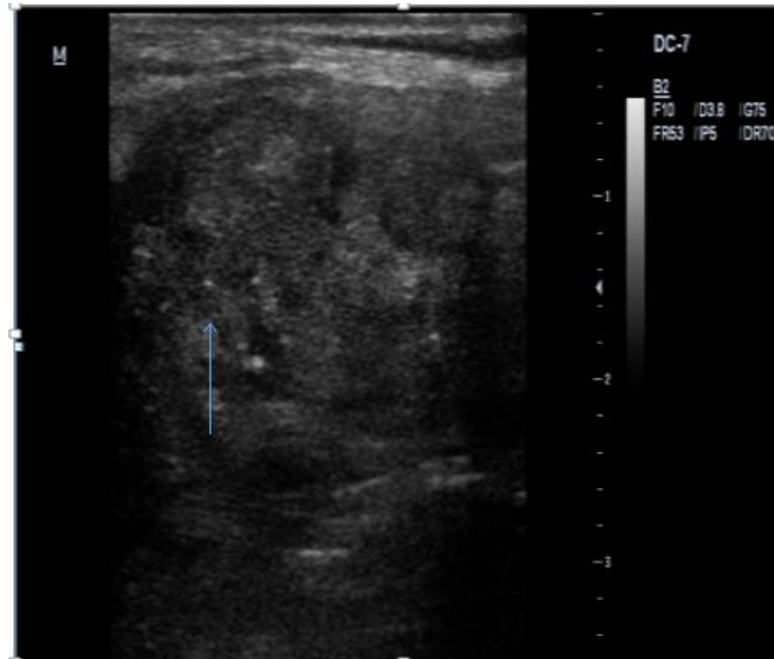


Image no.1- USG image showing hypoechoic solid, tall than wide nodule with irregular margins and thick, irregular and incomplete halo with microcalcifications (marked by arrow) within it. USG diagnosis of malignant nodule was given .Proved to be papillary carcinoma of thyroid on FNAC.

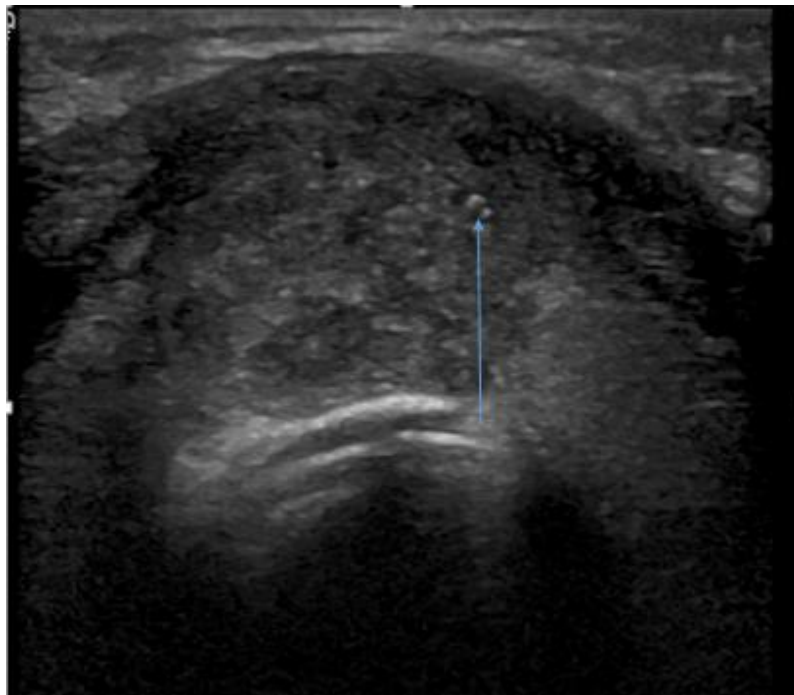


Image no. 2- Gray scale USG image showing a heterogeneously hypoechoic nodule with microcalcifications within (marked by arrow), USG diagnosis of papillary carcinoma was given, also proved to be papillary carcinoma of thyroid on FNAC.

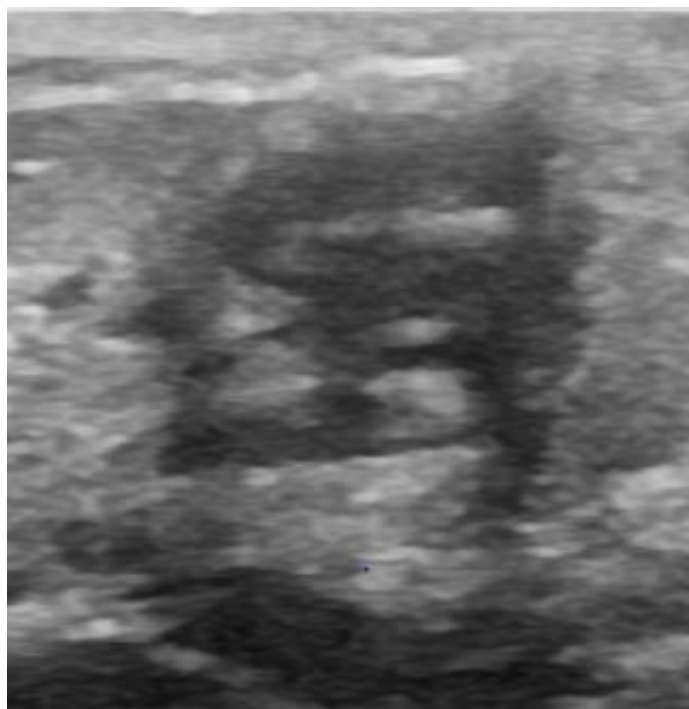


Image no. 3- Gray scale USG image showing a solid hypoechoic nodule, with irregular margins absent peripheral halo. USG diagnosis of malignant nodule was given, proved to be medullary carcinoma on FNAC

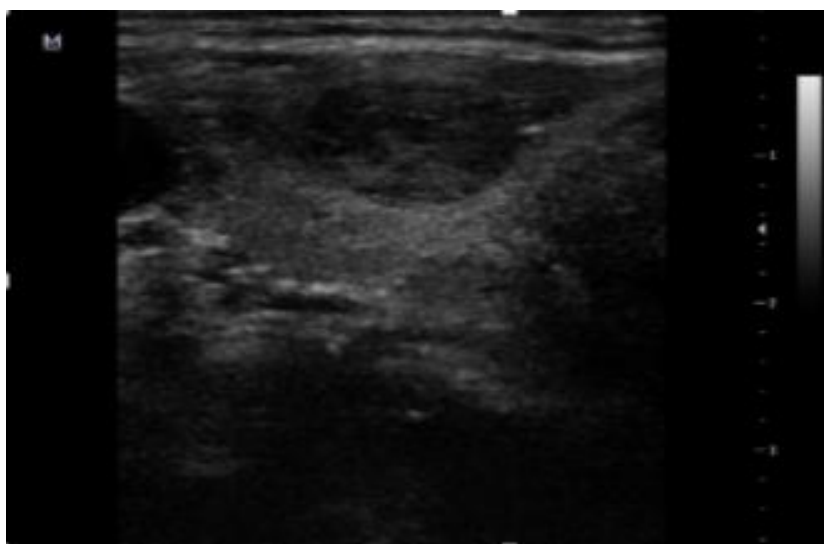


Image no. 4- Gray scale USG images showing a predominantly anechoic nodule with isoechoic solid component, wide than tall with regular margins and absent halo. USG diagnosis of benign nodule was made. FNAC diagnosis was of colloid nodule.

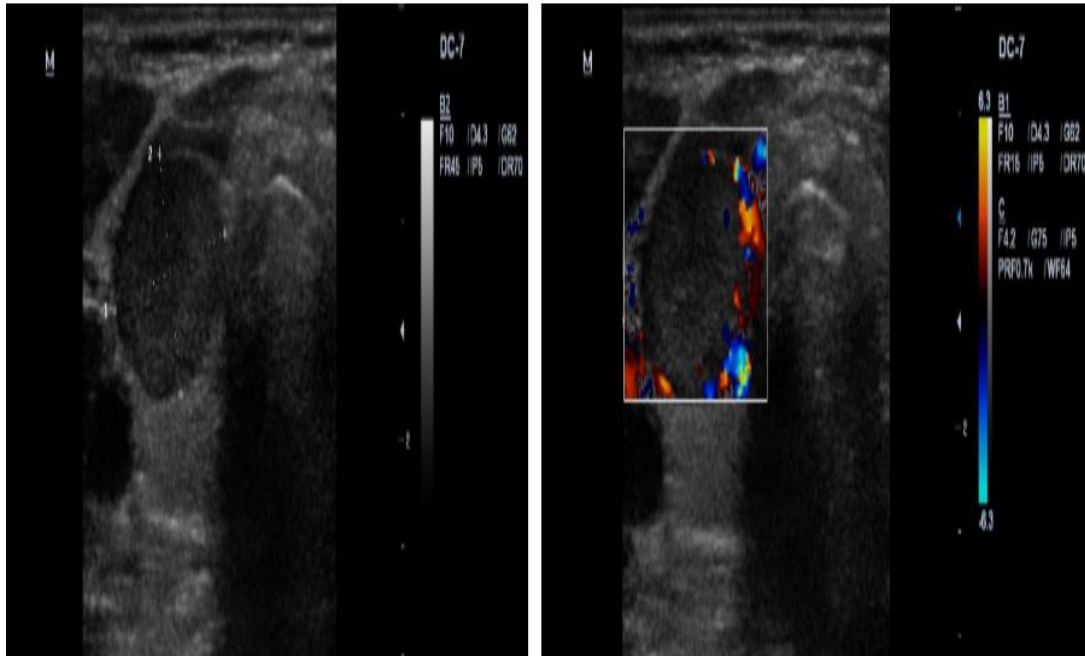


Image no. 7 - (a) Gray scale and (b) Colour Doppler images showing solid hypoechoic, tall than wide nodule with regular margins, absent halo and peripheral vascularity on Doppler, diagnosis of Malignant nodule was given ultrasound however proved to be benign colloid nodule on FNAC. (False Positive)

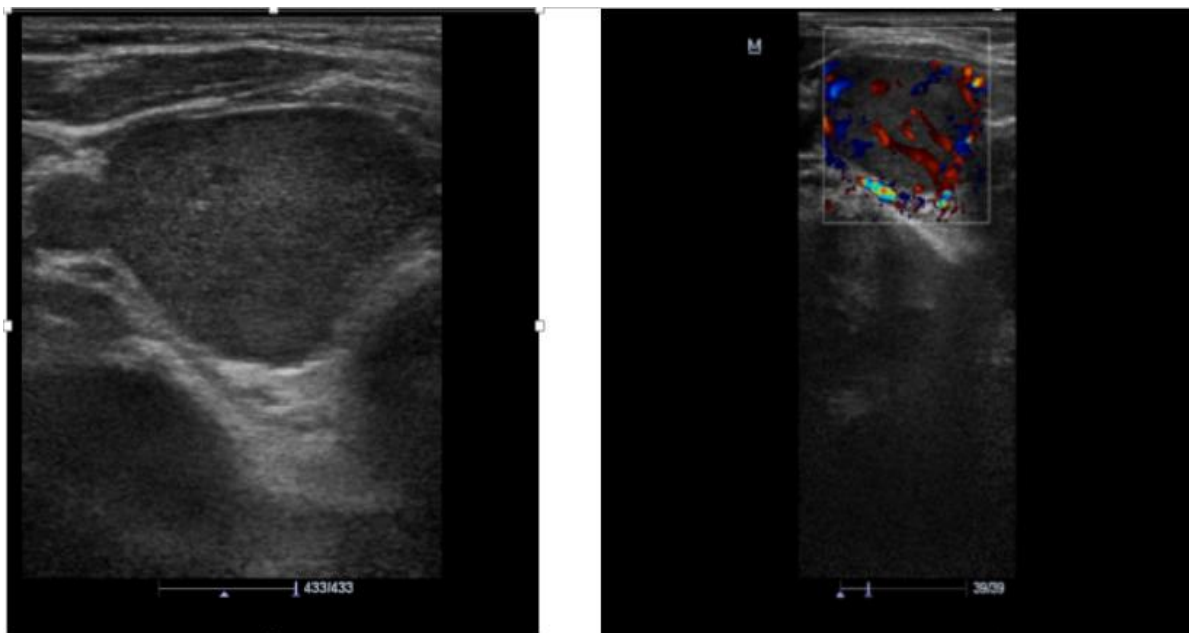


Image no. 8 - a) Gray scale & (b) Colour Doppler USG image showing hypoechoic solid nodule with regular margins and absent peripheral halo, showing intranodal as well as perinodal. USG diagnosis of malignant nodule was made. However proved to be colloid nodule of thyroid on FNAC. (False Positive)

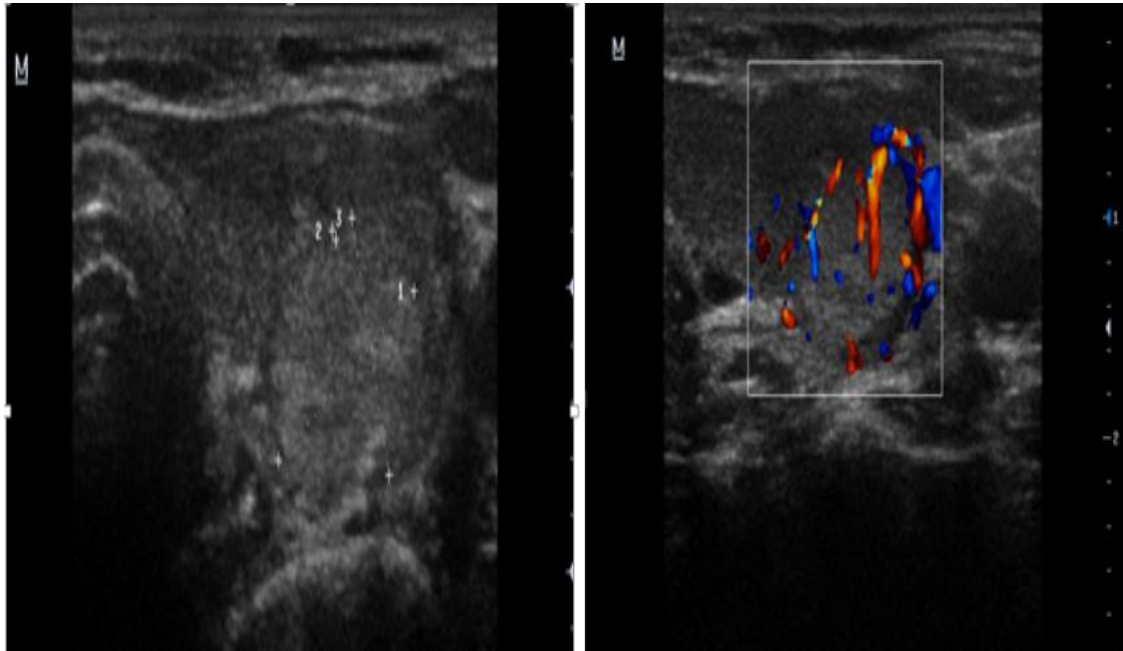


Image no. 9- (a) Gray scale & (b) Colour Doppler USG images showing hyperechoic nodule with irregular margins, showing perinodal as well as intranodal vascularity on Doppler . USG diagnosis of Malignant nodule was made. FNAC diagnosis was of hyperplastic nodule. (False Positive)

Dr. MeghaKumra. “Diagnostic Accuracy of Echogenicity as an Ultrasound Parameter for Determination of Malignancy in Solitary Thyroid Nodules.” IOSR Journal of Dental and Medical Sciences (IOSR-JDMS), vol. 18, no. 12, 2019, pp 32-40.