

Surgery for Spontaneous Intracerebral Hemorrhage: A Case Series

Thokchom Gojendra Singh¹, Brahamacharimayum Bobby Sarma²,
Nongthombam Hemantakumar Singh³
Laithangbam PKS⁴, Nongthombam Ratan Singh⁴

1-Associate Professor, Department of Neuro-Surgery 2- Assistant Professor, Department of Surgery; 3-Senior Neurophysician, Manipur Health Services, Imphal; 4-Professor-Department of Anesthesiology, Regional Institute of Medical Sciences, Imphal,

Corresponding author: Dr. Brahamacharimayum Bobby Sharma Assistant Professor, Department of Surgery Regional Institute of Medical Sciences, Imphal.

Abstract: Surgery for spontaneous hemorrhage (SICH) is debated as early trials for surgery could not prove better outcome than conservative medical management. However, removal of the mass effect of the hematoma should logically reduce secondary brain injury. Meanwhile, use of minimally invasive surgery for intracerebral hematoma is becoming popular with claim for better outcome. We speculate that preoperative stabilization along with better patient selection in accordance with the findings of earlier trials could improve patient outcome.

Key words: Spontaneous intracerebral hemorrhage, surgical outcome

Date of Submission: 26-11-2019

Date of Acceptance: 10-12-2019

I. Introduction

Spontaneous intracerebral hemorrhage (SICH) refer to a blood clot in the brain parenchyma without a history of preceding trauma or surgery. SICH affects 10-20 in 100,000 people every year and accounts for 20%-30% of all the strokes.¹Intracerebral hemorrhage (ICH) with or without intraventricular extension is a highly morbid disease process due to the mass effect and secondary injury that occur upon the surrounding brain.²Surgical intervention for evacuation of ICH and/or intraventricular hemorrhage (IVH) in order to remove the mass effect, prevents secondary injury and potentially reduce morbidity /mortality have been a matter of debate.^{3,4}Here, we present a series of 4 (four) cases of spontaneous intracerebral hemorrhage with surgical intervention and their outcome.

Case 1.

A 53-year-old woman presented to the emergency department with a sudden onset of giddiness, vomiting, weakness of left limbs and seizure episode with transient loss of consciousness. She had been diagnosed with essential hypertension about five years back and has been on amlodipine 5mg daily. She is a chronic smoker, consuming 10 cigarettes per day for the past 10 years or so. Her family history was unremarkable. There is no history of diabetes and or cardiac problems. On examination her blood pressure (BP) was found to be 180/110mmHg, pulse rate (PR)-68/min, oxygen saturation (SpO₂) of 96%. The size of the pupils 2mm bilaterally and reacting to light. Her Glasgow Coma Scale (GCS) at admission was E2V3 M5.

A non-contrast computerized tomography (CT) Scan brain demonstrated a highly attenuated (bright) intraparenchymal lesion in the right basal ganglia with a volume of about 60ml, midline shift (MLS) to the left (5mm) and without intraventricular extension. (Fig. 1A) After about 20-30% of the blood pressure reduction and stabilization of the vitals, the patient was operated 30 hours after the reported ictus

Following general anesthesia, a 6 cm curvilinear right frontal incision was made behind the hair line. A 4cm frontal craniotomy was performed followed by identification of the posterior aspect of the right frontal superior sulcus. A small corticectomy was done over the right superior frontal gyrus and trajected towards the hematoma i.e. basal ganglia. with the help of suction, irrigation and cautery with bipolar forceps, and the hematoma was evacuated. The bare brain area was lined with surgicell and homeostasis achieved. The intra operative B.P was controlled with propofol and labetalol infusion and kept within the range of 110/70 to 150/100 mmHg. The patient was put on ventilator for 24 hours in intensive care unit (ICU). The patient was extubated the next day after the post-operative CT scan of the brain (Fig.1B) showed near total evacuation of the hematoma. The patient was shifted to the ward on the 7th post-operateday (POD). The sutures were removed on

the 10th postoperative day (GCS of E4V4M6, left hemiparesis, motor power 2/5) and discharged on the 24th postoperative day.

Case 2.

A 48 years old male patient with history of hypertension on irregular medication presented with sudden onset of slurring of speech, weakness of right limbs, generalized tonic clonic seizures (GTCS) for a transient period (a few seconds). On admission his GCS was E3V3M6, Pupil size were- Right: 2mm, left: 3mm both reacting to light briskly, BP: 200/110 mm Hg., PR:64/min and SpO₂ of 94%. A non-contrast CT brain showed left basal ganglia bleed with intraventricular extension, measuring a volume of about 80ml with midline shift of 5 mm to the right (Fig 2A).

After stabilization of blood pressure, seizure control in the ICU the patient was operated after 36 hours of ictus. The hematoma was evacuated with a left frontal approach. The intraoperative blood pressure was maintained between 140/90-170/100 mmHg and the duration of surgery was 3 hours (approximately). He was put on ventilator for 24 hrs. and the endotracheal tube was removed the next day following post-operative CT Scan (Fig 2B) which showed near total evacuation. The post-operative GCS after extubation was E4V3M6 with slurring of speech, right hemiparesis with motor power of 2/5. The sutures were removed on the 10th POD and discharged on the 22nd POD. He was advised to continue physiotherapy, medications for seizure and hypertension. At 2 months follow up, he was able to walk with minimal support, slurring of speech and expressive aphasia still persisting.

Case 3.

A 40 years old male patient with history of hypertension and type 2 diabetes was brought to the hospital with complaints of sudden onset of GTCS followed by loss of consciousness. The GCS at admission was E1V2 M3. The pupil sizes were -left:4mm, right:3mm, sluggishly reacting to light and BP of 200/100 mm Hg, PR 60/min, SpO₂ of 90% and random blood sugar (RBS) 250mg/dl.

Non contrast CT Brain showed left basal ganglia bleed with intraventricular extension measuring volume of about 100ml and a midline shift of 6mm to the right (Fig 3A). After stabilization, the patient was operated within 4 hours of ictus. Left fronto temporoparietal decompressive craniectomy was done. Duration of surgery was 3 hours with detection of huge brain bulge and edema intraoperatively. He was kept on ventilator support postoperatively but expired on the 3rd postoperative day.

Case 4.

A 64 years old male patient with history of hypertension and chronic smoking presented with sudden onset of headache, giddiness, vomiting and weakness of left limbs. GCS at admission was E3V3M6, Pupils were 2mm bilaterally and normally reacting to light. The blood pressure was 170/100 mm Hg, PR:70/min, SpO₂ of 92% and RBS of 170mg with left hemiparesis of grade 3/5.

The non-contrast CT Brain showed right basal ganglia bleed of 70 ml volume (approx.) with no intraventricular extension and midline shift of 4mm to the left (Fig 4A). The patient was operated after 12 hours of ictus, approached by right frontal craniotomy with a surgical duration of 3hrs approximately. Intraoperatively B.P was maintained between 140/70 to 160/100 mmHg. He was kept on ventilator for 10 hours in ICU and extubated after reasonable findings in repeat CT Brain (Fig 4B). Postoperative GCS was E4V4M6. The sutures were removed on the 8th postoperative day and discharged on the 18th postoperative day. During follow-up, on the 50th day from discharge, the GCS was E4V5M6 with left hemiparesis grade 3/5.

II. Discussion

The exact pathophysiology for neurological deterioration following an intracerebral bleed is unclear. The possible mechanism includes the mass effect due to the volume of the clot, the toxins liberated by the degrading blood products, the ischemia surrounding the clot, the intraventricular bleed and secondary hydrocephalus if any.⁵

The logical reasoning, therefore would suggest the removal of the clot should reduce edema and intracranial pressure (ICP), limit ischemia and prove beneficial. But surprisingly, complete evacuation of the clot does not translate into neurological improvement. And most of the trials done so far have failed to clearly establish the efficacy of surgery.^{3,4}

Surgical trauma to an already traumatized brain and risk of fresh bleed could possibly explain the lack of benefits following surgery. Another hypothesis is that a hitherto unrecognized mechanism akin to post traumatic diffuse axonal injury probably plays an important role in determining the neurological status following a bleed.^{6,7}

A Cochrane review from 2008 by Prasad et al including ten randomized control trials (RCTs) including the STICH trial concluded that surgical evacuation added to the best medical management reduces mortality and disability.⁸

In sharp contrast to the previous studies, a recent report by Zheng et al.⁹ suggest that patient with hematoma more than 40ml of volume are more likely to have favorable outcome with surgery (13% vs 0%, p=0.005) and so do patients with intraventricular hemorrhage (IVH) (16.6% vs 7.2%, p=0.03).¹⁰

In yet another recent study analyzing significant prognostic factors in surgically treated patients of spontaneous ICH, Maila found male patients below 60yrs with right basal ganglionic bleed of volume less than 70ml and admission GCS of 8 and above carry a good prognosis especially if surgery is carried within 24 hours of ictus.¹⁰

Lack of clinical efficacy has been suggested to be due to the overall morbidity associated with large craniotomies and the cerebral trauma required to access deep-seeded lesions.⁴In our series, most of the patients operated within 12-36 hours of ictus. The third patient operated at 4 hours of ictus expired. The STICH trial^{7,8} has also observed benefit of early surgery (within 12-21 hours). Ultra-early surgery (within 4 hours of ictus) has been found to be associated with increased risk of bleeding.¹¹ We feel that pre-operative stabilization while preparing for surgery improves the outcome.

The volume of clot when more than 40 ml.⁹ but less than 70 ml.¹⁰ have been found to have favorable outcome. In this series, 3(three) patients who survived had hematoma volume within 60-80 ml. The one patient who expired (3rd patient) had volume of hematoma around 100 ml. We speculate that the large clot removed may give more space for rebleeding due to the lack of tamponade effect. The GCS status on admission is also important. The three patients who survived had admission GCS>8 and the third patient had GCS 6only. This finding is in accordance with the previous study.¹⁰However, we have not assessed the effect of minimally invasive surgery which is becoming popular.¹²

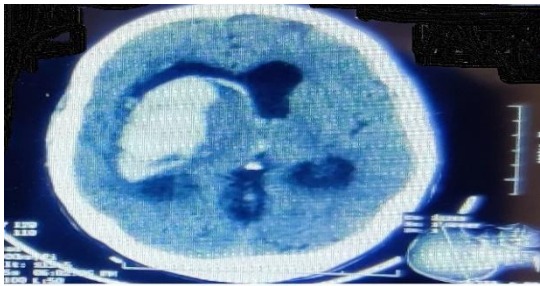
III. Conclusion

In conclusion, preoperative stabilization and selection of patients with GCS>8, hematoma volume within 40-70 ml. and early surgery (within 12-36 hours of ictus) may improve outcome.

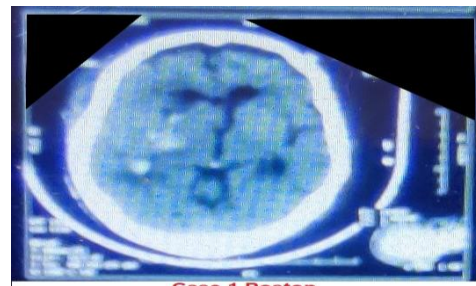
References:

- [1]. Hemphill JC 3rd, Greenberg SM, Anderson CS, Becker K, Bendok BR, Cushman M et al. Guidelines for the management of spontaneous intracerebral hemorrhage: A guideline for healthcare professionals from the American Heart Association/ American Stroke Association. *Stroke* 2015; 46:2032-60
- [2]. Sindelar BD, Patel V, Chowdhury S et al. (July 13, 2018). A case report in hemorrhagic stroke: A complex disease process and requirement for a multimodal treatment approach. *Cureus* 10(7): e2976. DOI 10.7759/cureus.2976
- [3]. Mendelow AD, Gregson BA, Fernandes HM, Murray GD, Teasdale GM, Hope Dt et al. Early surgery versus initial conservative treatment in patients with spontaneous supratentorial intracerebral hematomas in the international surgical trial in intracerebral hemorrhage (STICH): A randomized trial. *Lancet* 2005; 365:387-97.
- [4]. Mendelow AD, Gregson BA, Rowan EN, Murray GD, Gholkar A, Mitchell PM. STICH II Investigators. Early versus initial conservative treatment in patients with spontaneous supratentorial lobar intracerebral hematomas (STICH II): A randomized trial. *Lancet* 2013; 382:397-408.
- [5]. Naidech AM, Bernstein RA, Bassin SL, Garg RK, Leibling S, Bendok BR et al. How patients die after intracerebral hemorrhage. *Neurocrit. Care* 2009; 11:45-9.
- [6]. Xi G, Keep RF, Hoff JT. Mechanism of brain injury after intracerebral hemorrhage. *Lancet Neurol* 2006; 5:53-63.
- [7]. Zheng H, Chen C, Zhang J, Hu Z. Mechanism and therapy of brain edema after intracerebral hemorrhage. *Cerebrovasc. Dis* 2016; 42: 155-69.
- [8]. Prasad K, Mandelaw AD, Gregson B. Surgery for primary supratentorial intracerebral hemorrhage. *Cochrane Database Syst Rev* 2008. *Stroke* 2009; 40: e624-6.
- [9]. Zheng J, Li H, Zhao HX, Guo R, Lin S, Dong W, et al. Surgery for patient with spontaneous deep supratentorial intracerebral hemorrhage: A retrospective case control study using propensity score matching. *Medicine (Baltimore)* 2016; 95: e3024.
- [10]. Maila SK. Factors affecting the outcome of surgical evacuation of spontaneous deep intracerebral bleeds. *Br. J. Neurosurg* 2015; 29:668-71.
- [11]. Morgenstern LB, Demchuk AM, Kim DH, Frankowski RF, Grotta JC. Rebleeding leads to poor outcome in ultra-early craniotomy for intracerebral hemorrhage. *Neurology* 2001; 56:1294-9.
- [12]. ENRICH: the way you access matters (2018). Accessed: June 29, 2018; <https://www.enrichtrials.com>

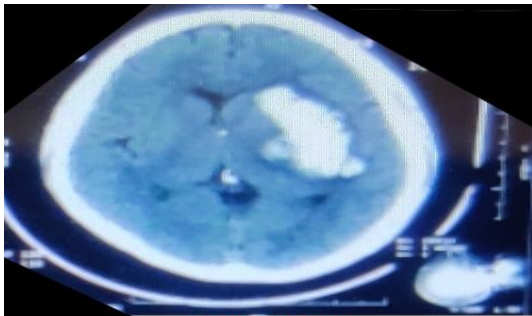
Computed Tomography images



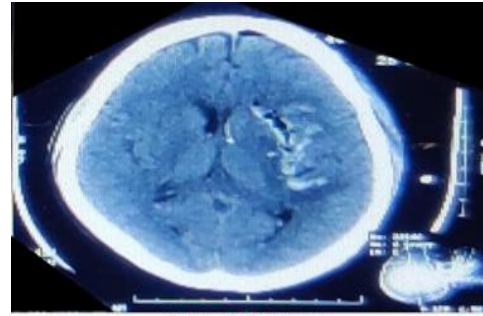
Case 1 Preop
Fig 1A. Intraparenchymal lesion in the right basal ganglia



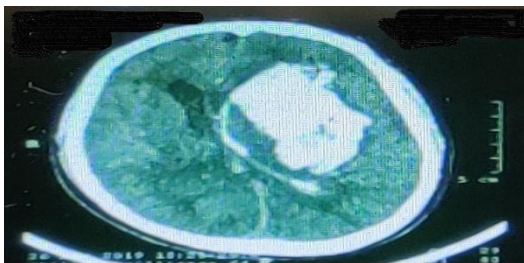
Case 1 Postop
Fig 1B. CT showing near total evacuation of the hematoma



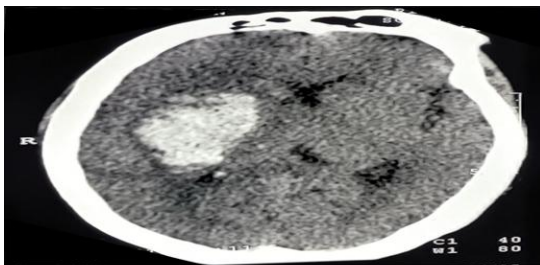
Case 2 Preop
Fig 2A Left basal ganglia bleed with intraventricular extension



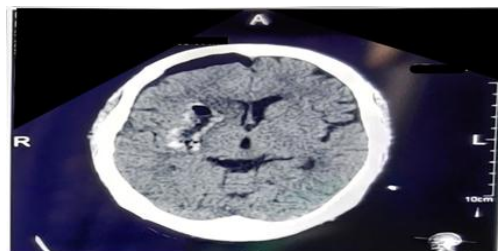
Case 2 Postop
Fig 2B CT showing near total evacuation postoperatively



Case 3 Preop
Fig 3A Left basal ganglia bleed with intraventricular extension



Case 4 Preop
Fig 4A Right basal ganglia bleed with midline shift to the left



Case 4 Postop
Fig4B Postoperative CT findings

Dr. Brahmacharimayum. "Surgery for Spontaneous Intracerebral Hemorrhage: A Case Series." IOSR Journal of Dental and Medical Sciences (IOSR-JDMS), vol. 18, no. 12, 2019, pp 52-55.