

Synchronous Primary Malignancy of Endometrium and Cervix: A case report

Shanu Veerasamy¹, Geetha Devadas¹ and Chandra Mouleeswari¹

¹Department of Histopathology, Anderson Diagnostics and Labs, Chennai, India

Corresponding Author: Shanu Veerasamy

Abstract: Synchronous primary tumours in the female genital tract is a rare phenomenon. Even rarer are the synchronous tumours involving the cervix and endometrium. We present a case of anatomically related yet histologically unrelated tumors. A 60 year old women presented with postmenopausal bleeding and white discharge per vaginum. Initial investigations revealed CIN3 changes in cervix for which extended radical hysterectomy with pelvic lymph node dissection was done. The histopathological examination revealed synchronous primary tumors of squamous cell carcinoma of cervix with endometrial adenocarcinoma. Correct diagnosis and timely intervention is the key for the management in such cases. These tumors have better survival rates and positive outcome if correctly diagnosed and differentiated from metastatic tumors.

Keywords: cervix, endometrium, synchronous tumours.

Date of Submission: 27-11-2019

Date of Acceptance: 12-12-2019

I. Introduction

Synchronous primary tumours in the female genital tract is a rare phenomenon⁽¹⁾. Two or more histologically distinct malignancies detected simultaneously are called synchronous tumours⁽²⁾. Most such cases are combined endometrial and ovarian cancer of unknown etiology and pathogenesis⁽³⁾. Rarely synchronous malignant tumours of endometrium and cervix have been reported in the world literature.

II. Case Report

A 60 years old lady presented with complaints of postmenopausal bleeding and whitish discharge per vaginum. She is a known case of diabetes, hypertension and hypothyroidism. Endometrial curettings and cervix biopsy was done which revealed CIN - III changes in cervix biopsy and endometrial curettings was scanty for opinion.

Hence with provisional diagnosis of squamous cell carcinoma of cervix, the patient was operated for extended radical abdominal hysterectomy with bilateral salpingo oophorectomy and bilateral pelvic lymph adenectomy.

As a stand out laboratory, we received total abdominal hysterectomy with bilateral salpingo oophorectomy with bilateral pelvic lymph nodes specimen with clinical details.

Macroscopically, the uterus was approximately 13 x 10 x 8 cm in dimension and endometrial tumour measuring 3.5 x 1 x 1cm was evident in the uterine cavity. The cut surface of tumour was grey white solid, accompanied by areas of necrosis and invaded the superficial myometrium. Myometrium showed a large intramural nodule measuring 6 cm in diameter with cystic changes. Cervix showed a vague grey white area with no gross tumour made out.

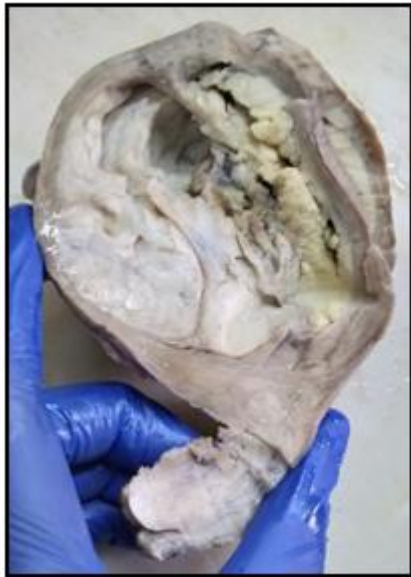

Fig 1: Endometrium showing irregular grey white proliferative tumour with vague grey white area in cervix.

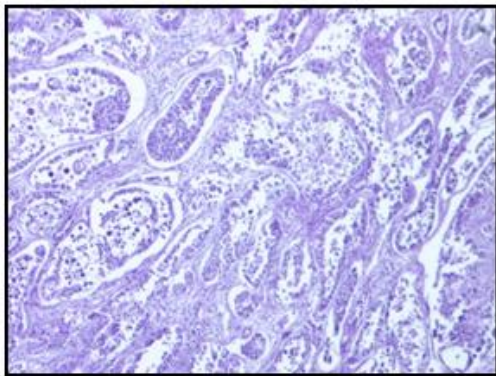


Fig 2: Section showing endometrial endometrioid adenocarcinoma (H&E,

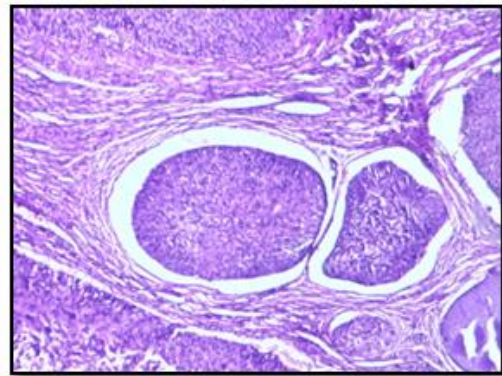


Fig3: Section showing cervical carcinoma with invasion and atypical mitosis (H &E, 20x)

Microscopically, the uterine cavity mass exhibited areas of closely packed glands with papillary configuration lined by malignant stratified columnar epithelium. The extent of nuclear atypia was moderate with eosinophilic cytoplasm. Sections from cervix shows dysplastic squamous epithelium with underlying microinvasive tumour dispersed in sheets and cords showing malignant cells showing scant to moderate cytoplasm and ovoid to round pleomorphic hyperchromatic nuclei infiltrating the fibrocollagenous stroma. The pelvic lymph nodes showed adenocarcinomatous deposits. Bilateral fallopian tubes and ovary were normal. Isthmus was uninvolved.

Immunohistochemically, the tumour in uterine cavity was positive for ER,PR with KI67 index , However the tumour in cervix were negative for both and p16 was positive for cervical carcinoma. Thus, we diagnosed the patient with endometrial carcinoma (pT1aN1) with microinvasion squamous cell carcinoma (pT1a1) presenting concomitantly.

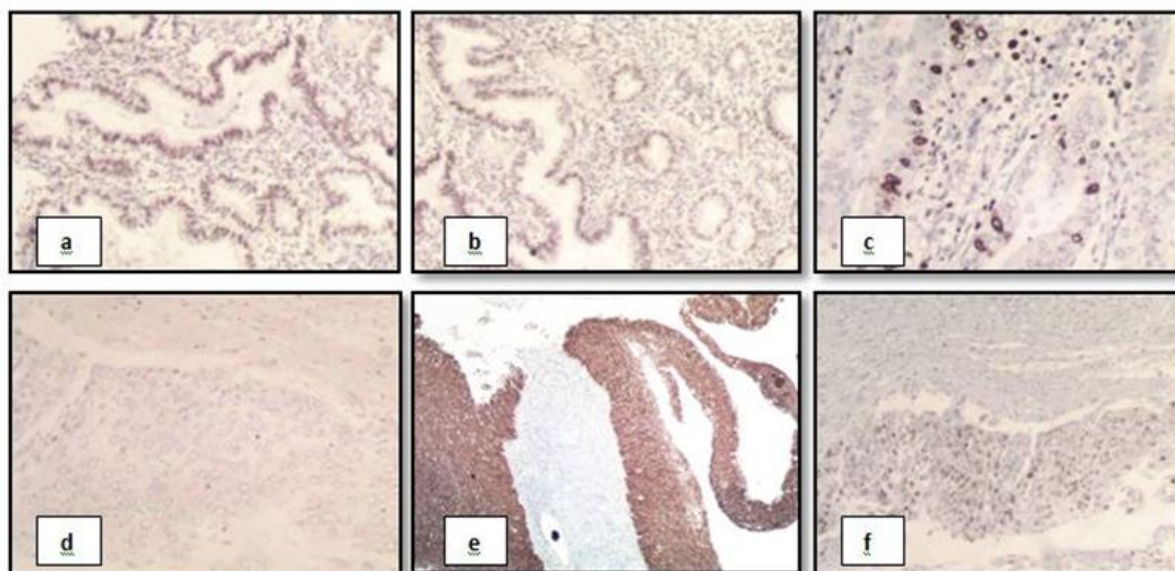


Fig 4: The tumour cells in endometrium shows ER,PR positive (a,b) whereas tumour cells in cervix shows ER negative (d) and P16 positive (e). Both tumour cells shows focal positivity for Ki67(c,f) (20x)

III. Discussion

Tumours are categorized as synchronous when they develop concomitantly. Only 1% to 6% of all genital tract neoplasms are synchronous primary genital cancers⁽¹⁾. Out of this the most common synchronous tumour is that of ovarian and endometrium⁽²⁾.

The exact etiology of this simultaneous presentation is still unknown. There are few hypothesis postulated in the literature regarding its origin. These tumors may arise because of the treatment of another malignancy or may be a part of any syndrome, or they might share common etiologic factors, such as the same environmental factors or genetic predisposition⁽⁴⁾.

The further treatment depends on age, cancer stage and grade, the extent of myometrial invasion and lymphatic metastasis status. Tumor staging is the most important factor when evaluating the prognosis of endometrial cancer⁽⁵⁾.

On literature review, apart from synchronous presentation of carcinoma ovary and endometrium, few cases of cancer ovary and cervix, endometrium and cervix, and ovary and fallopian tube are also reported. The maximum number of affected pelvic organs in a synchronous gynecological malignancy reported is five (ovary, bilateral tubes, endometrium, and cervix)⁽⁶⁾.

Tong SY et al⁽⁷⁾ reported 20 patients suffered from synchronous tumours of female genital tract. The most frequently observed synchronous neoplasm was ovarian cancer with coexisting endometrial cancer. The mean age of patient presenting with synchronous tumours of endometrium and ovary was 45.2 years. The mean duration of survival was 57 months.

Eser et al⁽⁸⁾ reported 55(1.3%) women with synchronous gynecological tumours out of 4185 gynecological tumours. The most frequent synchronous genital lesions were ovarian and endometrial cancers in 43 patients (81%). The median age at diagnosis of women with endometrial and ovarian cancer was 53.6 (33-76) years.

A single case study of Synchronous cervical and endometrial neoplasm was reported by Madhala D et al⁽²⁾, suggested that prognosis of patients with synchronous tumours is more favourable when compared to metastatic lesions of individual tumours. In our study, patient was diagnosed to metastatic adenocarcinomatous deposits in pelvic lymph nodes.

A case of cervical adenocarcinoma presenting as synchronous primary carcinoma with uterine adenocarcinoma was reported by Xu M et al⁽¹⁾ in 2018. They found independent primary endometrial and cervical tumour presenting concomitantly was a rare and uncommon phenomenon.

In a study done by Lv S et al⁽⁹⁾, synchronous dual malignancies of cervix and endometrium was reported. Their patient underwent radical hysterectomy with bilateral salphingo-oophorectomy, pelvic lymphadenectomy. The patient underwent a followup for 3 months and no recurrence was observed

IV. Conclusion

In conclusion , independent primary endometrial and cervical tumours are distinguishable both clinicopathologically and immunohistochemically. Synchronous primary gynecological cancers of endometrium and cervix is very rare. The stage of presentation of disease determines the prognosis.

References

- [1]. Mengfei Xu, Feng Zhou, Lili Huang et al; Concomitant endometrial and cervical adenocarcinoma- a case report and literature review. *Medicine* 2018; 97(1):1-3.
- [2]. Madhala D , Shanmugasundaram G, Narayanan SSC et al; Synchronous primary carcinoma of cervix and endometrium. *Annals of Pathology and Laboratory Medicine* 2017;4(2):33-36.
- [3]. Kambi DP, Mallikarjuna M N, Santosh CS et al; Synchronous malignancies of ovary, fallopian tube and cervix- A rare case. *International Journal of Biomedical And Advance Research* 2013;04 [09].
- [4]. Takalkar U, Asegaonkar BN, Kodlikeri P, Asegaonkar S, Sharma B, Advani SH, *et al.* An elderly woman with triple primary metachronous malignancy: A case report and review of literature. *Int J Surg Case Rep* 2013;4:593-6.
- [5]. Hui P, Baergen R, Cheung Y, Kurman RJ, Carcangiu ML, Herrington CS, Yong RH, *et al.* Gestational trophoblastic neoplasms. WHO Classification of Tumors of Female Reproductive Organs IARC, Lyon:2014;158–61.
- [6]. Atasever M, Yilmaz B, Dilek G, Akcay EY, Kelekci S. Synchronous primary carcinoma in 5 different organs of a female genital tract: An unusual case and review of the literature. *Int J Gynecol Cancer* 2009;19:802-7.
- [7]. Seo-Yun Tong, Yong-Sek Lee, Jong-Sup Park *et al.*; Clinical analysis of synchronous neoplasms of female reproductive tract. *European Jnl of Obs and Gyn and Reproductive Biology* 2008 ; 136:78- 82.
- [8]. Eser S, Gulhan I, Özdemir R *et al.* Synchronous primary cancers of the female reproductive tract in Turkish Women. *Asian Pacific J Cancer Prev* 2011;12:857-859.
- [9]. Lv S, Xue X, Sui Y, *et al.* Synchronous primary malignant neoplasms of the cervix and endometrium. *Mol Clin Oncol* 2017;6:661–4.

Shanu Veerasamy. “Synchronous Primary Malignancy of Endometrium and Cervix: A case report.”
IOSR Journal of Dental and Medical Sciences (IOSR-JDMS), vol. 18, no. 12, 2019, pp 51-54.