

Variations in the Branching Pattern of the Popliteal Artery As Detected By Multidetector CT Angiography.

Dr. Abhijit N Markande¹, Dr. Devadas Acharya. K²

¹(Post graduate, Department of Radiology, Yenepoya Medical College, Mangaluru.)

²(Professor and Head of department of Radiology, Yenepoya Medical College, Mangaluru.)

Abstract:

Introduction: The popliteal artery is the commonest blood vessel to get involved in peripheral artery aneurysm due to atherosclerosis and in entrapment syndrome. A detailed awareness on the anatomy of the terminal branches of the popliteal artery is associated with increased success rates of percutaneous surgical procedures as it allows suitable surgical planning.

Aims: To evaluate variants of the popliteal artery (PA) terminal branches with 16 slice multidetector computed tomographic angiography.

Materials and method: A total of 168 extremities of 200 patients undergoing a MD CTA examination were included in the study. Of these, 32 extremities were excluded due to popliteal artery thrombosis or amputation or having metallic implant. The terminal branching pattern of the PA was classified according to the classification scheme proposed by Kim.

Results: In 168 extremities (91.6 %) branching of PA occurred distal to the knee joint (Type I); in 8 cases (4.72%) PA branching was superior to the knee joint (Type II); and 6 cases (3.5%) of Type III. Among these types the most frequent branching patterns were Type IA 90.56%, Type IIA1 (2.36%), Type IIA2 (2.36%) and type III (2.36%).

Conclusion: Variations in popliteal artery terminal branching pattern occurred in 9.44% of patients. Pre-surgical detection of these variations with MD CTA may help to reduce the risk of iatrogenic arterial injury by enabling a better surgical treatment plan.

Keywords: Popliteal artery, branching patterns, vascular variations, multidetector CT angiography

Date of Submission: 09-12-2019

Date of Acceptance: 24-12-2019

I. Introduction

Popliteal artery is the deepest neurovascular structure present in the popliteal fossa. It extends from adductor hiatus, to the lower border of popliteus, where it divides into its terminal branches.¹ A detailed awareness on the anatomy of the terminal branches of the popliteal artery by the ortho-surgeons, vascular surgeons, reconstructive surgeons and radiologists is associated with increased success rates of percutaneous surgical procedures as it allows suitable surgical planning.^{2,3} The popliteal artery is the commonest blood vessel to get involved in peripheral artery aneurysm due to atherosclerosis and in entrapment syndrome.^{4,5} In the last few decades, the multidetector computed tomographic angiography (MD CTA) is used frequently as compared with digital subtraction angiography (DSA) in diagnostic assessment of lower extremity of arterial disease has increased the awareness of popliteal artery variations. There are several studies involving the use of DSA in the assessment of popliteal artery variations.^{2,6-14}

However, few studies are there assessing the popliteal artery terminal branching variations with MD CTA.^{15,16} In the current retrospective study, variations in the branching pattern of the popliteal artery have been assessed using 16 slice –multi-detector CT angiography.

II. Materials and Methods

Patient Selection

At our institution, between October 2018 and October 2019, 100 consecutive patients underwent lower extremity CTA because of suspected arterial occlusive disease. We reviewed the CTA data retrospectively for anatomic assessment of the popliteal artery and its branches.

The study consisted of 200 extremities in 100 patients (16 females, 84 male, 32 to 91 years old). The study protocol was approved by the Institutional Ethics Committee.

Exclusion criteria:

- Patients who have undergone below knee amputation
- Total knee replacement prosthesis
- Metallic implants below knee
- Complete thrombosis of Popliteal artery

Imaging Technique

Multidetector CT angiography of the lower limbs was obtained with General Electric (GE) Medical system Brightspeed Light 16 slice MDCT machine with 5mm collimation, 0.6mm reconstruction interval, gantry rotation speed of 0.8 seconds, pitch of 1.375:1. 120kV and automated tube current adaptation(100-700mA). Patients were placed in the supine position with feet first. The scans covered the area from the level of the coeliac axis to the tip of the foot

For venous access, the antecubital vein and an 18-gauge IV cannula was used. A total of 100–120 cc contrast material with high iodine concentration (350 mgI/ml) was injected at a 5 cc/sec injection rate. Scan timing was determined by automated bolus triggering; the region of interest was placed on the abdominal aorta; the threshold was set as 200 HU. The scan was started 8 seconds after reaching the threshold.

Image Analysis:

The scans were reviewed on a direct display console. Sagittal and coronal reconstructions were made wherever necessary. Newer techniques in Multislice CT like curved planar reformatting, volume rendering, Maximum and Minimum Intensity Projections was done as and when necessary. CTA images were reviewed by two radiologists.

The branching pattern of the popliteal artery has been classified based on the classification scheme proposed by Kim et al.⁸ as follows. Type I: Branching of the popliteal artery (PA) at the normal, expected level, i.e., below the level of medial tibial plateau. This classification also proposes three subgroups for Type I: In Type IA (normal), the first branch of the popliteal artery is the anterior tibial artery (ATA) with the continuing segment of the main artery, known as tibioperoneal trunk, further divided into peroneal (PRA) and posterior tibial arteries (PTA). In Type IB trifurcation, branching of ATA, PTA, and PRA is within a distance of 0.5 cm without formation of a true tibioperoneal trunk. In Type IC, PTA is the first branch, and ATA and PRA arise from the tibioperoneal trunk. In Type II, there is branching of PA above the normal level. Similar to the Type I variation, Type II has also three subgroups with further subgrouping. Type IIA denotes a popliteal artery that branches at or above the joint space. Its subdivisions are as follows: Type IIA1, normal proximal course of ATA, and Type IIA2, proximal and medial course of ATA. Type IIB is defined as the branching of PTA at or superior to the joint level, and branching of ATA and PRA from the tibioperoneal trunk. Type IIC is defined as branching of PRA at or superior to the joint level. In Type III, there is hypoplasia or agenesis in the branches of PA with an alteration in distal blood supply. The Type III pattern includes the following subgroups: Type IIIA shows distal substitution of PTA by PRA, along with hypoplastic or aplastic PTA. Type IIIB is defined as substitution of the dorsalis pedis artery (DPA) by PRA, along with hypoplastic or aplastic ATA. Type IIIC has distal substitution of PTA and DPA by PRA in conjunction with hypoplastic or aplastic ATA and PTA.

III. Results

A total of 100 patients were examined who were suspected to have peripheral arterial disease. 32 extremities were excluded due to complete thrombosis of popliteal artery (27), amputation (1) and metallic implant (4). Hence the study consisted of 168 extremities.

Type I branching pattern was seen in 154 (91.6%)extremities with type I A seen in 152 (90.56%) and type I B seen in 2(1.16%) extremities. Type I C was not observed in our study.

Type II branching pattern was seen in in 8 (4.72%) extremities with type II A1 seen in 4(2.36%) and type II A2 seen in 4 (2.36%) extremities. Type II B and type II C was not observed in our study.

Type III branching pattern was seen in 6(3.5%) extremities with type IIIA seen in 2(1.16%) and type III B in 4(2.36%) extremities Type III C was not observed in our study.

Popliteal artery branching pattern	Results		
	Right	Left	Percentage
Type I A	78	74	90.56
TYPE I B	2	0	1.16
TYPE I C	0	0	0
TYPE II A1	2	2	2.36
TYPE II A2	2	2	2.36
TYPE II B	0	0	0

TYPE II C	0	0	0
TYPE IIIA	2	0	1.16
TYPE IIIB	0	4	2.36
TYPE IIIC	0	0	0

Table no: 1 – Distribution of the popliteal artery branching pattern

IV. Discussion:

In the present study the variation in the branching of the popliteal artery occur with an incidence of 9.44% therefore not that infrequent. Our findings are consistent with variations as reported in other studies are 7.4-17.6^{2,6-8, 17-19} A good knowledge of popliteal artery branching variation is necessary to prevent misinterpretations of the imaging findings. The interpretation of this variation is important for interventional radiology and surgery.^{11, 18, 19} The awareness of this variation is a precondition for the success of the outcomes of vascular grafting, vascular repair, angioplasty and embolectomy.^{7, 9, 11, 18-20} The type of appropriate surgical approach is dependent on the variation in the branching pattern.⁷

In the study by Klecker et al. that examined the clinical significance of the aberrant anterior tibial artery using magnetic resonance angiography (MRA) in 1116 patients, the authors concluded that a good knowledge of the aberrant anterior tibial artery may reduce arterial complications in a variety of orthopedic interventions such as high tibial osteotomy, revision total knee arthroplasty, lateral meniscal repair, posterior cruciate ligament reconstruction, and tibial tubercle osteotomy of the knee joint, including arthroscopy²¹.

Tindall et al. observed that in all patients with high origin of the anterior tibial artery, the artery was in direct contact with the posterior cortex of the tibia. The anterior tibial artery is vulnerable in this variation using sharp instruments when a transverse tibial cortex was performed in knee procedures—particularly high tibial osteotomy and total knee replacement.²²

Balloon catheter technology, used to treat lower extremity ischemia in diabetic patients, allows percutaneous transluminal angioplasty of small arteries, which could be hindered by different ATA variations in the leg^{18,23}. A change in the angioplasty technique is needed if a Type III branching pattern is detected^{11,18,24}.

In addition, harvesting of the PA for the fibular free flap transfer procedure is contraindicated if a Type III C pattern is present. This procedure could result in a catastrophic ischemia of the foot as the peroneal artery the only artery that feeds the distal parts of the limb in the Type III C branching pattern^{18,24}.

However, to our knowledge, only few studies for variation in popliteal artery branching were used based MD CTA. Both Yanik et al. and Calisir et al. have recently evaluated the popliteal artery and its branches and classified its branching patterns using MD CTA; they concluded that MD CTA could become the preferred method for evaluating arterial variations of the lower limb^{18,19}. Our study and these studies were carried out in a retrospective manner using a MD CTA.

The most common variant of the popliteal artery detected by angiography is a Type I variation, with a frequency between 89% and 96%^{2,7,9,11,12,18}. Among these cases, normal arterial branching classified as Type IA represents the most common. In the studies by Yanik et al. and Calisir et al. examining the variations of the popliteal artery branching using with MD CTA, the authors found the frequency of a Type I pattern as 88.8% and 87%, and a Type IA pattern as 83.6% and 87%, respectively^{18,19}. Our results are similar to these data, with the incidence of Type I and Type 1A at 91.6% and 90.56%, respectively. Similar to previous DSA studies and Calisir et al. in an MD CTA study, we observed that the incidence of a type IB branching pattern was higher than the incidence of type IC^{2,7,8,19}.

The reported frequency for the Type II pattern varies between 1.6% and 7.8%^{2,7,8,11,18,19}, and this pattern occurred at 4.72% in our case. Type IIC, reported in only three cases in the literature, was not present in any of our patients. Also, another pattern classified as Type IID and reported in a single case by Mavili et al., which exhibits a high trifurcation of PA and medial course of ATA proximally and lateral course of ATA distally, has not occurred in any of our cases¹¹. A possible advantage of MD CTA in this group may result from its ability to image the popliteus muscle, which affects the subgrouping of Type IIA.

The Type III variation pattern has been reported to occur in the range 1–7.6%^{2,7,8,11,18,19}, and carries a particular importance, as its assessment presents certain technical challenges in atherosclerotic patients. Gradual decrease in the dimensions of the hypoplastic artery, absence of collateral circulation, a straight course of the distal PRA in PTA and dorsalis pedis artery (DPA) tracings, and its not reducing in size at the level of the division should suggest a variation². Particularly in such cases, MD CTA not only provides luminal information, but also enables evaluation of the vessel wall, potentially facilitating the process. Yanik et al. and Calisir et al. reported the frequency of the Type III pattern to be 3.4% and 3.6%, respectively, whereas Type IIIB was not observed by Yanik et al. and Type IIIC was not observed in either of these studies. In our study, a Type III pattern occurred in 3.5% of our cases (Type IIIA 1.16%, Type IIIB 2.36%, Type IIIC 0%)

One of the potential limitations of the present study is that CTA findings were not compared with DSA, MRA, US or surgical findings. Such a comparison would be useful for further evaluation of the performance of CTA in delineating lower extremity arterial anatomy.

V. Conclusion:

In conclusion, proper characterization of the anatomical properties of the popliteal artery requires an adequate knowledge of its terminal branching variants. In the present study, the incidence of variation in branching pattern of the popliteal artery was observed in 9.44% of cases. This result shows that variations in popliteal branching are not infrequent. The increasing rate of surgical reconstruction and vascular surgical procedures of the lower extremity places more significance on having detailed anatomical information. In this regard, awareness of the terminal branching pattern of popliteal artery before intervention with MD CTA is important, both in the planning of appropriate surgery and to reduce unexpected arterial injury.

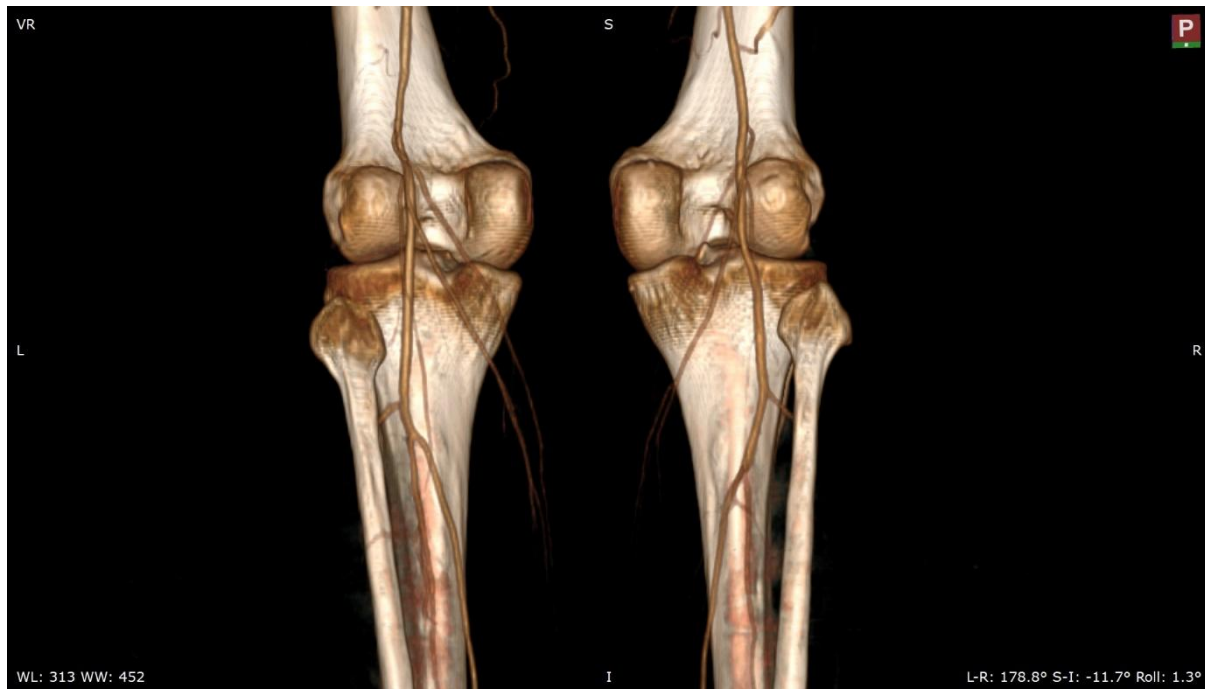


Figure 1: Volume rendered image shows the normal branching pattern of the popliteal artery Type I A

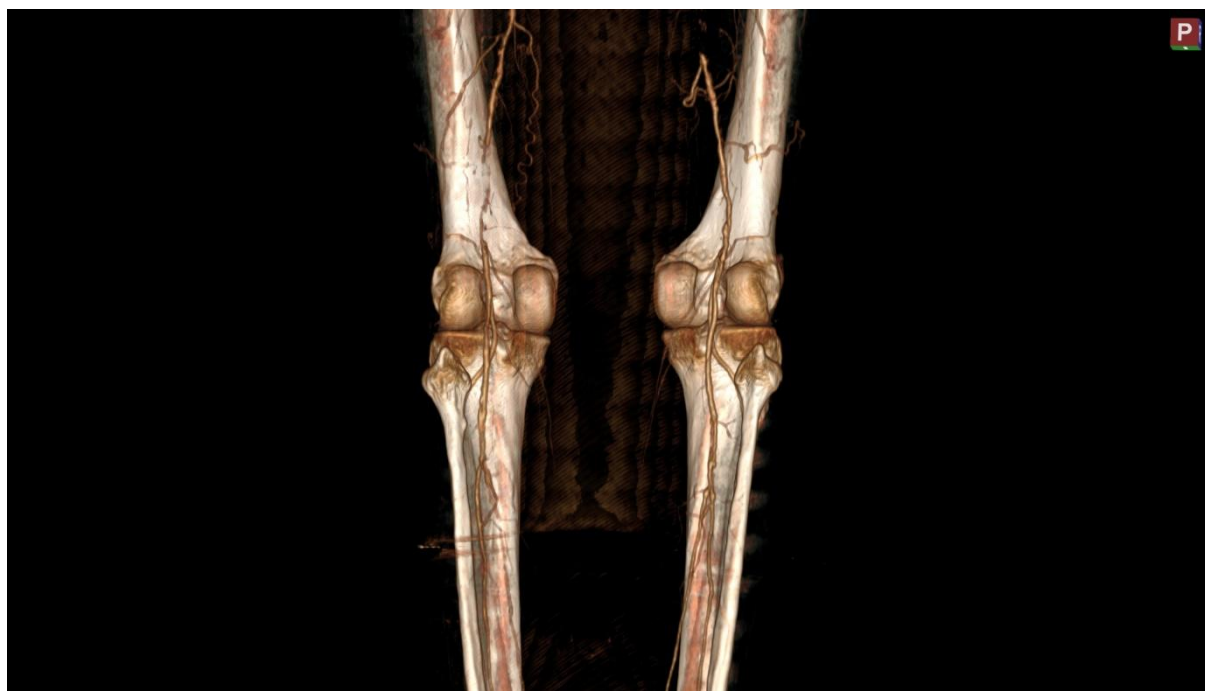

Figure 2: Volume rendered image shows the high branching pattern of the anterior tibial artery with medial course of the proximal portion of the anterior tibial artery on both sides- type II A2.

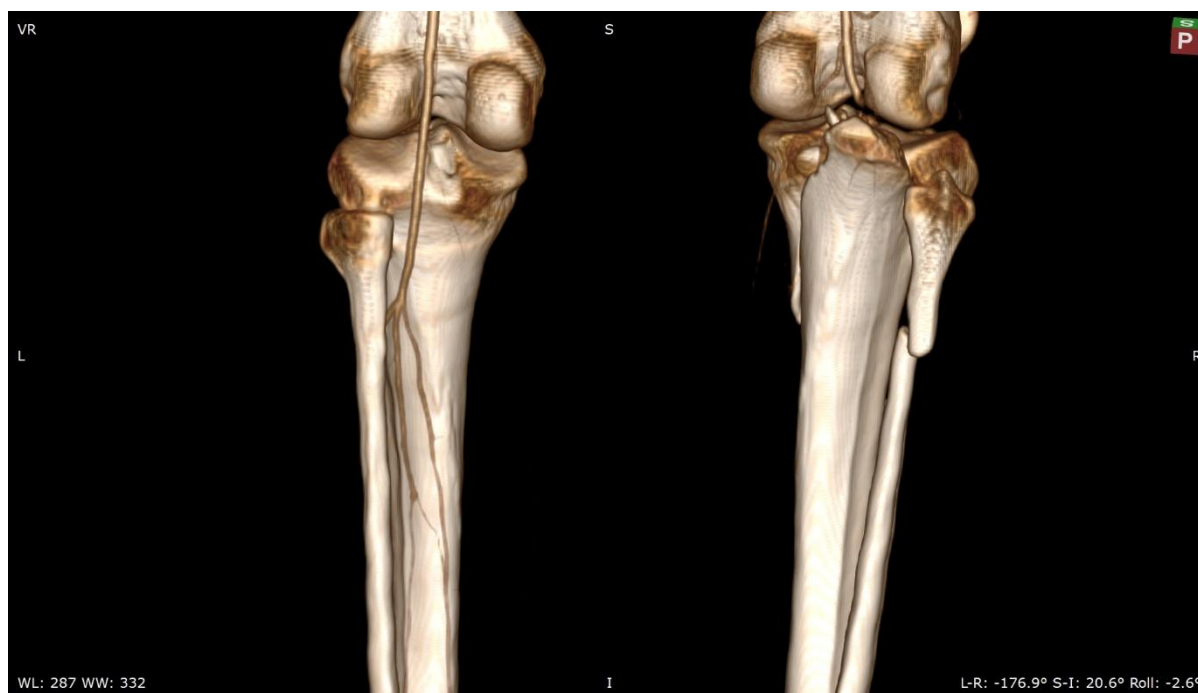

Figure 3: Volume rendered image shows the trifurcation, branching of ATA, PTA, and PRA is within a distance of 0.5 cm without formation of a true tibioperoneal trunk – type I B on left side and thrombosis of the distal popliteal artery with comminuted intra articular fracture of the tibial plateau and proximal fibular shaft on right side.

References:

- [1]. Susan Standring, Gray's anatomy. The Anatomical Basis of Clinical Practice, 40th edition, 2008; 414-415
- [2]. Day CP, Orme R. Popliteal artery branching patterns an angiographic study. *Clin Radiol.* 2006;61:696-699.
- [3]. Son KH, Cho JH, Lee JW, Kwack KS, Han SH. Is the anterior tibial artery safe during ankle arthroscopy?: anatomic analysis of the anterior tibial artery at the ankle joint by magnetic resonance imaging. *Am J Sports Med.* 2011;39:2452-2456
- [4]. Bilateral High-Origin Anterior Tibial Arteries and Its Clinical Importance, K Sharma, MK Haque, DI Mansur, Vol 10, No 1 (2012)
- [5]. Matthew A. Mauro, Paul F. Jaques (1988), *AJR* 150:435-437, February 1988 0361-803X/88/1 502-0435 © American Roentgen Ray Society.
- [6]. Kawarada O, Yokoi Y, Honda Y, Fitzgerald PJ. Awareness of Anatomical Variations for Infrapopliteal Intervention. *Catheter Cardiovasc Interv.* 2010;76:888-894.
- [7]. Kil SW, JGS Anatomical Variations of the popliteal Artery and its Tibial Branches: Analysis in 1242 Extremities. *Cardiovasc Intervent Radiol.* 2009;32:233-240.
- [8]. Kim D, Orron DE, Skillman JJ. Surgical significance of popliteal arterial variants. A unified angiographic classification. *Ann Surg.* 1989;210:776-781.
- [9]. Kropman RHJ, Kiela G, Moll FL, de Vries JP. Variations in anatomy of the popliteal artery and its side branches. *Vasc Endovascular Surg.* 2011;45:536-540.
- [10]. Maura MA, Jaques PF, Moore M. The popliteal artery and its branches: embryologic basis of normal and variant anatomy. *Am J Roentgenol.* 1988;150:435-437.
- [11]. Mavili E, Dönmez H, Kahriman G, Özaşlamacı A, Özcan N, Taşdemir K. Popliteal artery branching patterns detected by digital subtraction angiography. *Diagn Interv Radiol.* 2011;17:80-83.
- [12]. Szpinda M. Angiographic study of the tibioperoneal trunks in patients with aorto-iliac occlusive disease. *Ann Anat.* 2005;187:405-410.
- [13]. Bardsley JL, Staple DW. Variations in Branching of the Popliteal Artery. *Radiology.* 1970;94:581-587.
- [14]. Sanders RJ, Alston GK. Variations and anomalies of the popliteal and tibial arteries. *Am J Surg.* 1986;152:531-534.
- [15]. Bose E, Ramanathan V, Seshayyan S. An angiographic study in terminal branching pattern of popliteal artery and its clinical connotation. 6(2):5.
- [16]. Öztekin PSÖ, Ergun E, Cıvgın E, Yigit H, Kosar PN. Variants of the popliteal artery terminal branches as detected by multidetector CT angiography. *Open Medicine [Internet].* 2015 [cited 2019 Dec 3];10(1).
- [17]. Sanders RJ, Alston GK. Variations and anomalies of the popliteal and tibial arteries. *Am J Surg.* 1986;152:531-534.
- [18]. Yanik B, Bulbul E, Demirpolat G. Variations of the popliteal artery branching with multidetector CT angiography. *Surg Radial Anat.* 2015;37:223-230.
- [19]. Calisir C, Simsek S, Tepe M. Variations of popliteal artery branching in 342 patients studied with peripheral CT angiography using 64-MDCT. *Jpn J Radiol.* 2015;33:13-20.
- [20]. Aktanlıkiz ZA, Ucerler H, Ozgur Z. Anatomic variations of popliteal artery that may be a reason for entrapment. *Surg Radial Anat.* 2009;31:695-700.
- [21]. Klecker RJ, Winalski CS, Aliabadi P, Minas T. The aberrant anterior tibial artery: magnetic resonance appearance, prevalence, and surgical implications. *Am J Sports Med.* 2008;36:720-727.
- [22]. Tindall AJ, Shetty AA, James KD, Middleton A, Fernando KW. Prevalence and surgical significance of a high-origin anterior tibial artery. *J Orthop Surg (Hong-Kong)* 2006;14:13-16.

- [23]. Atansova M, Georgiev GP, Jelev L. Intriguing variations of the tibial arteries and their clinical implications. *Int J Anat Var.* 2011;4:45–47.
- [24]. Chow CL, Napoli A, Klein MB, Chang J. Vascular Mapping of the Leg with Multi-Detector Row CT Angiography prior to Free-Flap Transplantation. *Radiology.* 2005;237:353–360.

Dr. Abhijit N Markande. "Variations in the Branching Pattern of the Popliteal Artery As Detected By MultidetectorCT Angiography." *IOSR Journal of Dental and Medical Sciences (IOSR-JDMS)*, vol. 18, no. 12, 2019, pp 42-47.