

## Correlation between Langerhans cells and mast cells in Oral Squamous Cell Carcinoma – An insight

Singh S.S<sup>1\*</sup>, Chettiankandy T.J<sup>1</sup>, Rodricks K<sup>1</sup>, Bisht S<sup>1</sup>

<sup>1</sup>Department of Oral Pathology, Government Dental College & Hospital, Mumbai, India

---

### **Abstract:**

**Background:** Ample research is being conducted at present to tackle the global malice of oral squamous cell carcinoma. There is a need to understand the carcinogenetic process by exploring various biological markers and cells involved. Langerhans cells are antigen-presenting cells that are known to have an anti-tumorigenic role while mast cells are an inherent part of inflammatory cascade that lead to microenvironmental conditions favorable for invasion. The present study aims at analyzing the correlation between the two and understanding their role in development of carcinoma.

**Materials and Methods:** Tissue blocks were obtained from the archives of the department consisting of histopathologically confirmed cases of oral squamous cell carcinoma. Two sections were obtained from each specimen, one of which was observed immunohistochemically for CD-1a positive Langerhans cells while the other was observed for mast cells by means of Toluidine blue staining. The number of cells in question were counted for all the samples and compared to those in normal tissues of the control group.

**Results:** Langerhans cells were observed to decline in oral squamous cell carcinoma as compared to normal tissues with lower number of cells found as the differentiation of the lesion became poorer. While, the number of mast cells increased up to three-fold the times of that in normal tissues.

**Conclusion:** The decline in number of Langerhans cells could indicate the loss of ability of the body tissues to contain the carcinogenetic process. The concomitant increase in number of mast cells possible indicates their role in creating conditions favorable for microinvasion.

**Key Word:** Dendritic cells, inflammation, microinvasion, tumor microenvironment.

---

Date of Submission: 16-03-2020

Date of Acceptance: 01-04-2020

---

### I. Introduction

Oral squamous cell carcinoma (OSCC) is one of the penultimate causes of morbidity and mortality in developing countries comprising of more than 30 percent of reported cancer cases in our country<sup>1</sup>. Despite extensive research conducted to tackle this global health priority, there has been only a modest improvement in patient survival rate<sup>2</sup>. Thus, there is a need for continuum of research to be conducted regarding various aspects of this global malice to better understand its pathogenesis and immunological basis.

An intact immune system is required for all higher organisms to detect and destroy invading microorganisms and to eliminate cells that undergo malignant transformation<sup>3</sup>. The dendritic cells (DCs) represent a large family of antigen-presenting cells that circulates through the bloodstream and are distributed in nearly all tissues of the body. DCs occupy a unique role in the innate immune system by serving as a bridge to the adaptive immune response, and have a powerful capacity to activate immunologically immature T-cells in an antigen specific way<sup>4</sup>. The epithelial residents of dendritic cells are Langerhans cells, which guard the mucosa, altering the immune system not only to pathogen entry but also of tolerance to self-antigen and commensal microbes<sup>5</sup>.

Mast cells, on the other hand, are long-lived tissue-resident cells with an important role in many inflammatory settings including host defense to parasitic infection and in allergic reactions. They have been found to be significantly associated with increased mitotic activity, extracellular matrix degradation, angiogenesis, intensification of microvascular, increased permeability, and recruitment of inflammatory cells including macrophages<sup>6</sup>. Studies have shown that mast cells accumulate around the margin of these cutaneous malignancies<sup>7-12</sup>. There is compelling evidence that mast cell accumulation among the peri-tumoral inflammatory infiltrates contributes to a permissive microenvironment for carcinogenesis and metastasis<sup>13-15</sup>.

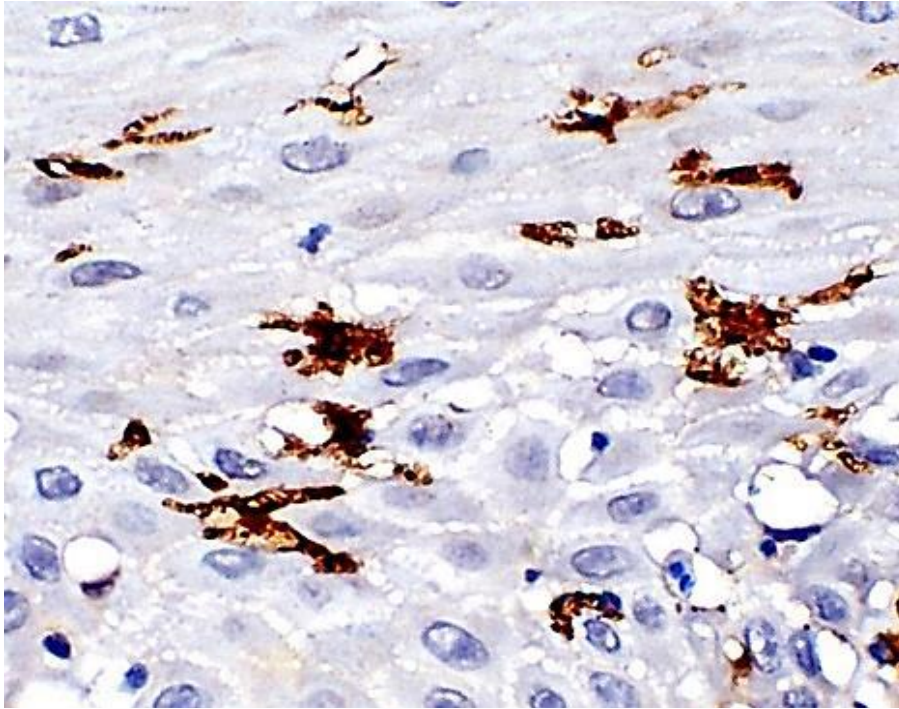
In this context, the following pilot study was carried out to assess the relative change in the quantification of these immunomodulatory cells i.e. Langerhans cells and mast cells occurring within OSCC as compared to the tissues in a normal state.

### II. Material and Methods

*Correlation between Langerhans cells and mast cells in Oral Squamous Cell Carcinoma – An insight*

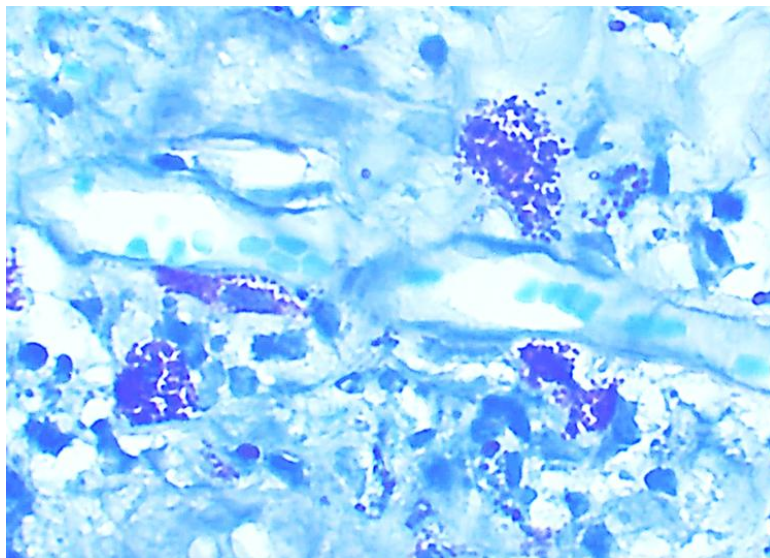
Formalin fixed paraffin embedded tissue (FFPE) specimens of histopathologically diagnosed cases of oral squamous cell carcinoma and normal tissues as controls were obtained from the archives of department of Oral Pathology. Sample size of 5 tissue specimens per group was selected for this demonstration. The archival blocks of normal tissues consisted of specimen obtained from patients that had voluntarily undergone crown lengthening procedure.

Two sections of 4µm each were obtained from each FFPE specimen. One section of each specimen was immunohistochemically stained with mouse anti-human CD-1a (Clone 010, DAKO; Agilent Technologies, Inc., Santa Clara, CA, USA) monoclonal antibody and super sensitive polymer-HRP IHC detection system for the immunohistochemical detection of CD-1a positive Langerhans cells (**Figure 1**). Each batch was stained with phosphate buffered saline (PBS) instead of primary antibody as the negative control.



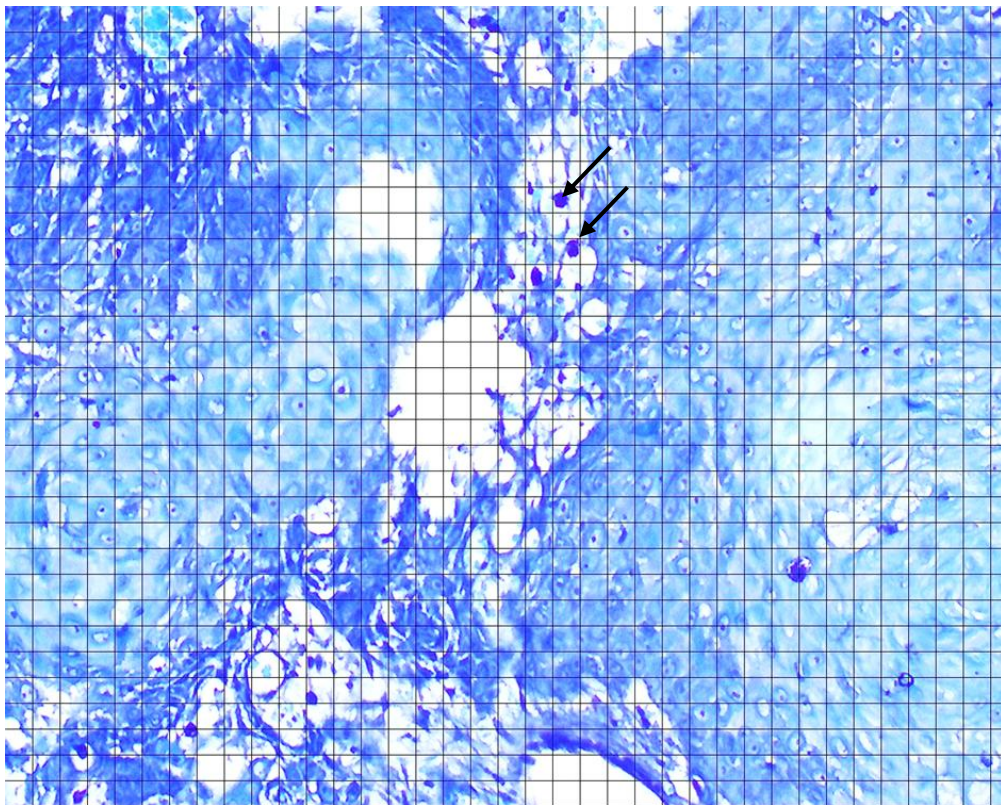
**Figure 1: CD-1A positive Langerhans cells as observed by immunohistochemistry**

Whereas, the other section of the same specimen was stained with Toluidine blue O (C. I. 52040, Merck) to observe mast cells<sup>16</sup>. (**Figure 2**)



**Figure 2: Degranulated mast cells as observed by Toluidine blue staining**

Under 10x magnification of light microscope, three fields having reasonably adequate number of cells in question were selected<sup>17</sup>. Motic v2.0 software was used to obtain the microscopic picture and for analytical grids to aid in counting of the cells (**Figure 3**).



**Figure 3: Example of one field under 10x magnification using grids to facilitate counting of cells in question (depicted by arrows)**

The cell qualified to be counted as a Langerhans cell if it satisfied the following criteria<sup>5</sup>:

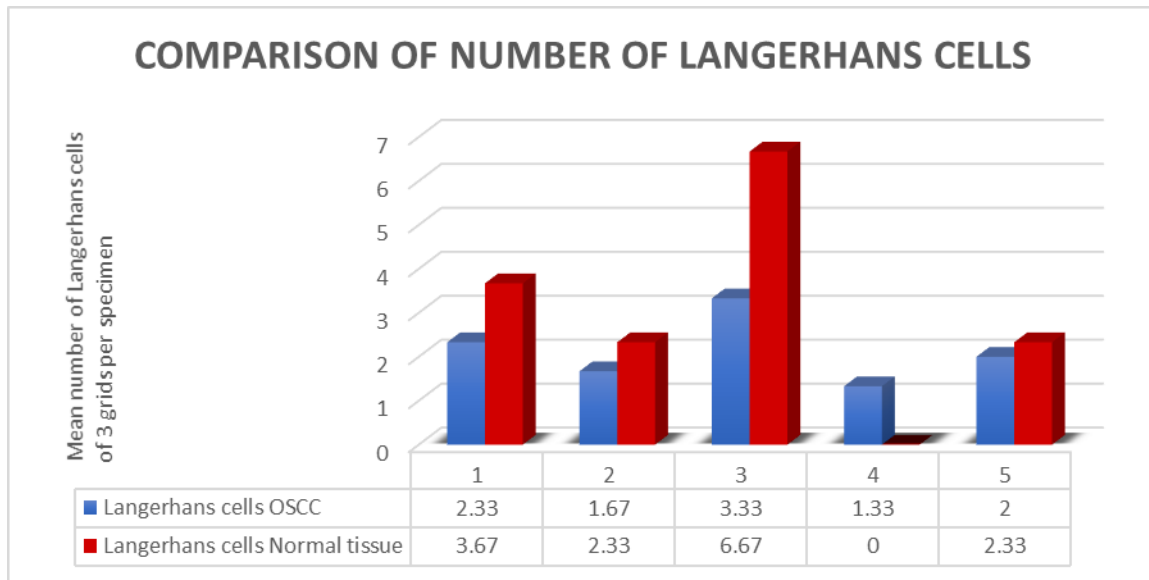
- (a) Brownish localization of CD1a staining within a completely visible cell body
- (b) Cell surface showed presence of at least one dendritic process.

The number of cells in question were counted in each field and their mean was obtained for each section of tissue specimen.

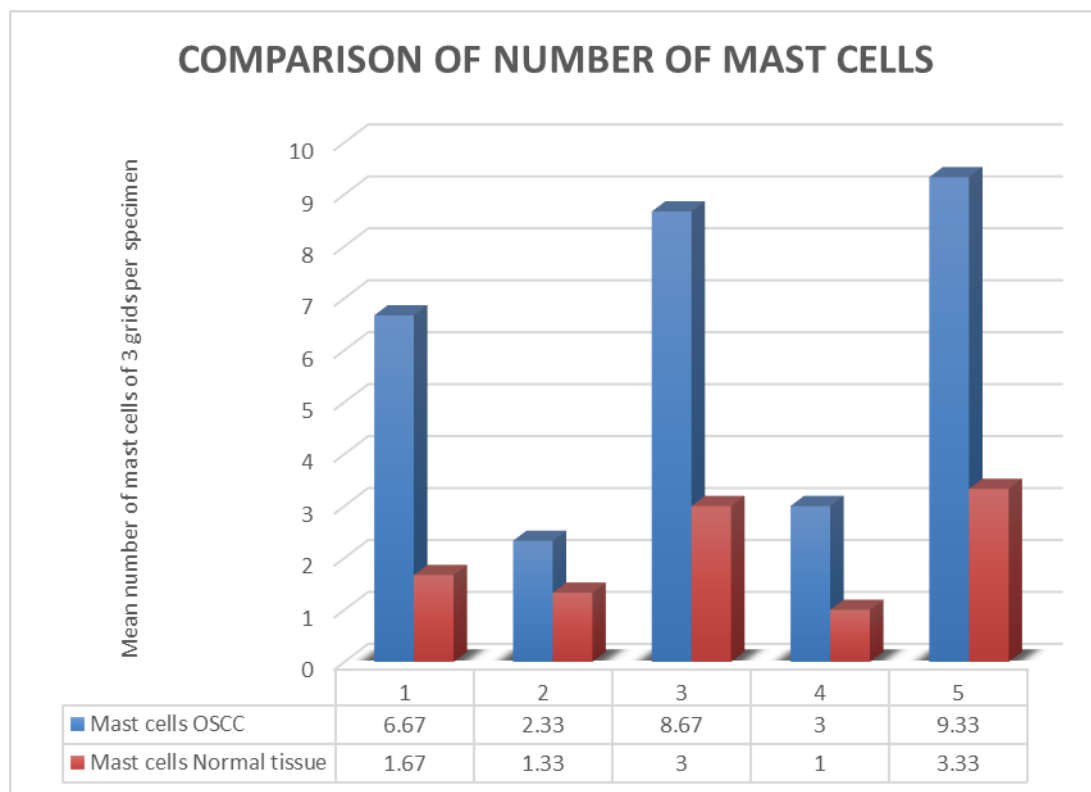
### **III. Results**

The cases in both groups comprised of 3 specimens of female patients and 2 specimens of male patients. Amongst the OSCC specimens, 4 were histopathologically confirmed as well differentiated OSCC whereas only one specimen was that of moderately differentiated OSCC. The intraoral site of occurrence of all the cases of well differentiated OSCC was in the buccal vestibule except 1 which involved the alveolus and that of the case with moderately differentiated OSCC was the tongue.

There was an observed decline in the number of Langerhans cells in tissues of OSCC as compared to that in normal tissues which is summarized in **Table 1**. The number of mast cells was found to increase in OSCC generally as much as three times the number of mast cells in normal tissues as depicted in **Table 2**.



**Table 1: Bar diagrammatic representation of observed number of Langerhans cells in OSCC as compared to normal tissues.**



**Table 2: Bar diagrammatic representation of observed number of mast cells in OSCC as compared to normal tissues.**

The mean number of Langerhans cells in normal tissues was 2.13 while that observed in OSCC was 3. Whereas, the mean number of mast cells in normal tissues was 2.07 while that observed in OSCC was 6. The number of both, Langerhans cells as well as mast cells, were lesser in the case of moderately differentiated OSCC specimen as compared to the well differentiated OSCC specimens. This could possibly point towards decline in number of both the cell populations as the differentiation of epithelial cells decreases, however, the observation cannot be justified by this pilot study and needs to be confirmed in subsequent studies using a greater sample size consisting of varying differentiations of OSCC.

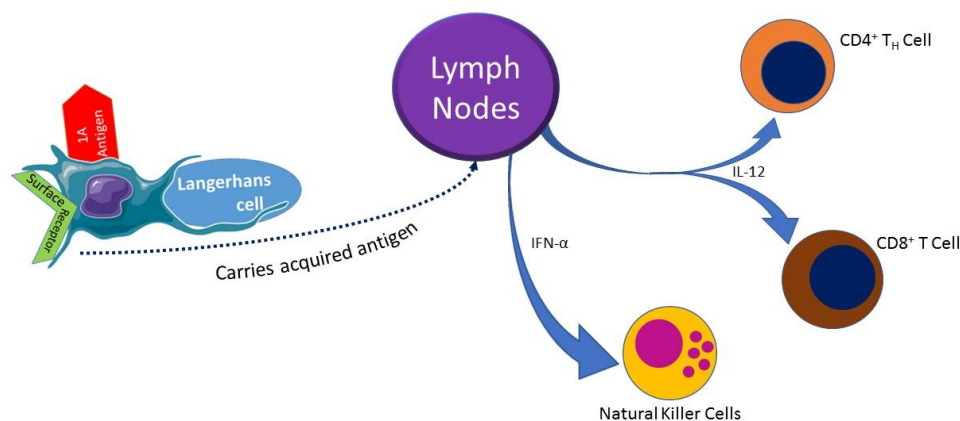
Another observation indicates that most of the mast cells found within the stroma of OSCC tissues were degranulated suggestive of the role of their released products in facilitating the carcinogenetic process.

#### IV. Discussion

Langerhans cells (LCs) are dendritic antigen presenting cells<sup>18</sup> which originate from the bone marrow. The function of LCs is to recognize antigen, process it and present it to T cells. They intercept and bind new antigens detected in the squamous epithelium. They are responsible for initial stimulation of naïve T lymphocytes and secondary immune response by stimulating memory T cells<sup>19,20</sup>.

Albert et al<sup>21</sup> demonstrated that dendritic cells, which phagocytosed apoptotic cells, are able to initiate an anti-tumor immune response<sup>22</sup>. The dendritic cells found within the tumor microenvironment have a relatively immature and inactive phenotype, characterized by low levels of proinflammatory cytokine production and decreased or low levels of co-stimulatory molecules like CD80 and CD86, and MHC class II expression<sup>23</sup>. Many tumor derived cytokines that possess immunosuppressive activity, can impede the development of fully mature DCs, such as VEGF, M-CSF, IL-6, GM-CSF, IL-10, gangliosides and TGF- $\beta$ <sup>24,25</sup>. Several researchers have investigated the distribution of LC's in squamous cell carcinoma, however, none have yielded consistent results. Earlier reports were highly variable with some reporting a decrease<sup>26,27</sup> whereas some observed an increase<sup>28,29</sup> and few reported no change<sup>30</sup>.

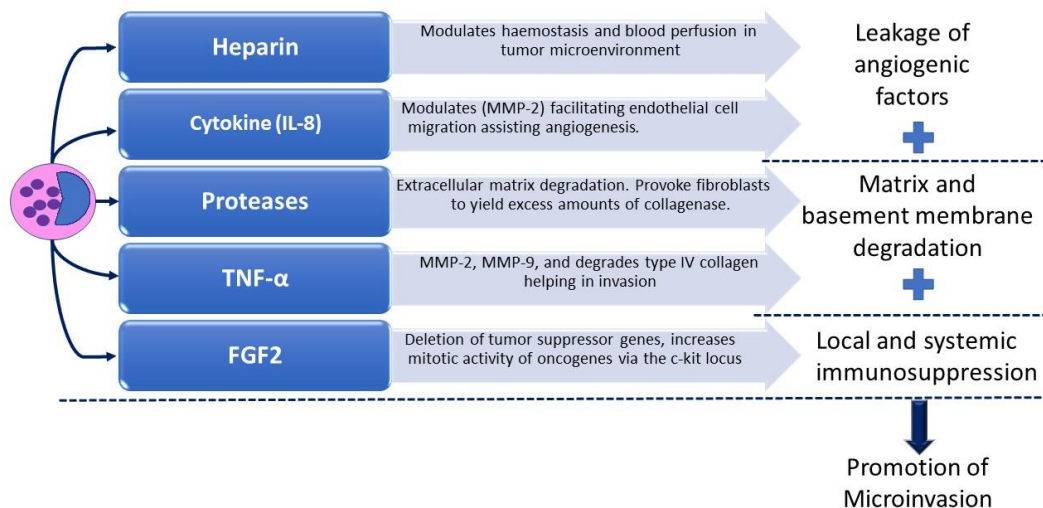
However, all the studies consistently observed a predominant site of enhanced LC at the infiltrating margin of the lesion. Also, LCs play a role in priming of lymphocytes in response to various antigens (**Figure 4**). A significant observation has been that LC's were more abundant in well/moderately differentiated than in poorly differentiated OSCC<sup>31,32</sup>. Also, fewer LCs were observed in metastatic lesions than in primary lesions<sup>33</sup>.



**Figure 4: Langerhans cells present acquired antigen to mucosa-draining lymph nodes which induces proliferation in antigen specific T-cells**

Mast cells possess many properties that enable them to participate in a diverse range of biological activities. They phagocytose, process antigens, produce cytokines and release a variety of preformed (eg, histamine, proteoglycans and proteases) and newly formed (eg, leukotrienes and prostaglandins) physiological mediators<sup>34</sup>. Mast cells carry on selection of adhesion molecules, immune response receptors and other surface molecules which permit them to react to multiple specific and nonspecific stimuli. These widespread biological characteristics, their universal distribution and tactical locations near blood vessels, nerves, inflamed tissues and neoplastic foci enable them to play a central role in a variety of physiologic, immunologic and pathologic processes.

The effects of mast cell mediators on the development and spread of malignancies are likely to be mediated through multiple pathways (**Figure 5**), including immunosuppression, enhancement of angiogenesis, disruption of the extracellular matrix and promotion of tumor cell mitosis<sup>35</sup>. Based on the condition of the micro environment, there can be stimulation, mitogenesis and chemotaxis of mast cells<sup>36</sup>. They can lead to the production of heparin which modulates haemostasis and blood perfusion in tumor microenvironment<sup>37</sup>. Cytokine (IL 8) modulates matrix metalloproteinase 2 (MMP 2) facilitating endothelial cell migration assisting angiogenesis<sup>38</sup>. Proteases help in extracellular matrix degradation. They provoke fibroblasts to yield excess amounts of collagenases. TNF  $\alpha$  influences MMP2, MMP 9 and degrades type IV collagen helping in invasion. FGF 2 assists in deletion of tumor suppressor genes, increase mitotic activity of oncogenes via the c-kit locus<sup>39</sup>.



**Figure 5: Various mechanisms involving the mast cells in the carcinogenic process**

These mechanisms provide an insight about the possible role of the antigen-presenting Langerhans cells in tumor immunity, degradation of the stromal matrix and creation of an environment favorable for microinvasion by the products released by mast cells and also an interrelation between the two cell populations by means of ILs.

## V. Conclusion

The decline in number of Langerhans cells could be responsible for the inability of the tissues to restrict the carcinogenic process. Whereas, the concomitant increase in mast cell population within the stroma could be indicative of creation of conditions favourable for the process of microinvasion. The sample size of this pilot study may be inadequate for significantly asserting the roles of cells in the carcinogenic process. Thus, further studies are required with a larger sample size with adequate number of samples in various differentiated stages of OSCC and also in oral potentially malignant disorders is recommended to determine the detailed correlation between the changes in population Langerhans cells and mast cells in OSCC.

## References

- [1]. Coelho, Ken. Challenges of the Oral Cancer Burden in India. *J Can Epidemiology*. 2012. 701932. 10.1155/2012/701932.
- [2]. Fang J, Li X, Ma D, Liu X, Chen Y, Wang Y, Lui VW, Xia J, Cheng B, Wang Z. Prognostic significance of tumor infiltrating immune cells in oral squamous cell carcinoma. *BMC cancer*. 2017 Dec 1;17(1):375.
- [3]. Lotze MT, Thomson AW, editors. *Dendritic cells: biology and clinical applications*. Elsevier; 2001. pp 314
- [4]. Cutler CW, Jotwani R. Antigen-presentation and the role of dendritic cells in periodontitis. *Periodontology* 2004;35(1):135-57.
- [5]. Upadhyay J, Rao NN, Upadhyay RB. A comparative analysis of langerhans cell in oral epithelial dysplasia and oral squamous cell carcinoma using antibody CD-1a. *Journal of cancer research and therapeutics*. 2012 Oct 1;8(4):591
- [6]. Michailidou EZ, Markopolos AK, Antoniadis DZ. Mast cells and angiogenesis in oral malignant and premalignant lesions. *Open Dent J*. 2008;2:126–32.
- [7]. Cawley E, Hoch-Ligeti C. Association of tissue mast cells and skin tumors. *Arch Dermatol* 1961;83(1):146–150.
- [8]. Duncan L, Richards L, Mihm Jr M. Increased mast cell density in invasive melanoma. *J Cutan Pathol* 1998;25(1):11–15
- [9]. Ribatti D, Ennas M, Vacca A, et al. Tumor vascularity and tryptase-positive mast cells correlate with a poor prognosis in melanoma. *Eur J Clin Invest* 2003;33(5):420–425.
- [10]. Toth T, Toth-Jakatics R, Jimi S, et al. Cutaneous malignant melanoma: correlation between neovascularization and peritumor accumulation of mast cells overexpressing vascular endothelial growth factor. *Hum Pathol* 2000;31(8):955–960.
- [11]. Humphreys T, Monteiro M, Murphy G. Mast cells and dendritic cells in basal cell carcinoma stroma. *Dermatol Surg* 2000;26(3):200–204.
- [12]. Aoki M, Pawankar R, Niimi Y, et al. Mast cells in basal cell carcinoma express VEGF, IL-8 and RANTES. *Int Arch Allergy Immunol* 2003;130(3):216–223.
- [13]. Coussens L, Werb Z. Inflammatory cells and cancer: think different!. *J Exp Med* 2001;193(6):F23–26.
- [14]. Nakayama T, Yao L, Tosato G. Mast cell-derived angiopoietin-1 plays a critical role in the growth of plasma cell tumors. *J Clin Invest* 2004;114(9):1317–1325.
- [15]. Theoharides T, Conti P. Mast cells: the Jekyll and Hyde of tumor growth. *Trends Immunol* 2004;25(5):235–241.
- [16]. Ribatti D. The staining of mast cells: a historical overview. *Int arch Allergy Imm*. 2018;176(1):55-60.
- [17]. Narwal A, Saxena S. A comparison of langerhans cell numbers in tobacco-associated leukoplakia and oral squamous cell carcinoma. *Int J Oral Med Sci*. 2011;10(3):125-31.
- [18]. Silberberg I. Apposition of mononuclear cells to Langerhans cells in contact allergic reactions. An ultrastructural study. *Acta Derm Venereol*. 1973;53:1–12
- [19]. Barrett AW, Cruchley AT, Williams DM. Oral mucosal Langerhans' cells. *Crit Rev Oral Biol Med*. 1996;7(1):36–58

## *Correlation between Langerhans cells and mast cells in Oral Squamous Cell Carcinoma – An insight*

- [20]. Lombardi T, Hauser C, Budtz-Jørgensen E. Langerhans cells: Structure, function and role in oral pathological conditions. *J Oral Pathol Med.* 1993;22(5):193–202.
- [21]. Albert ML, Sauter B, Bhardwaj N. Dendritic cells acquire antigen from apoptotic cells and induce class I-restricted CTLs. *Nature*, 1998, 392(6671): 86–89.
- [22]. Gottfried E, Kreutz M, Mackensen A. Tumor-induced modulation of dendritic cell function. *Cytokine & growth factor reviews.* 2008;19(1):65–77.
- [23]. Gabrilovich D. Mechanisms and functional significance of tumor-induced dendritic-cell defects. *Nat Rev Immunol*, 2004, 4(12): 941–952.
- [24]. Kao JY, Gong Y, Chen CM, et al. Tumor-derived TGF- $\beta$  reduces the efficacy of dendritic cell/tumor fusion vaccine. *J Immunol*, 2003, 170(7):3806–3811.
- [25]. Lisi P. Investigation on Langerhans' cells in pathological human epidermis. *Acta Dermatol Venerol*, 1973;53: 425–428.
- [26]. Fernandez-Bussy R, Cambazard F, Mauduit G, et al. T cell subsets and Langerhans' cells in skin tumours. *Eur J Cancer Clin Oncol*, 1983;19(7): 907–913.
- [27]. McArdle JP, Knight BA, Halliday GM, et al. Quantitative assessment of Langerhans cells in actinic keratosis, Bowen's disease, keratoacanthoma, squamous cell carcinoma and basal cell carcinoma. *Pathology*, 1986;18(2): 212–216.
- [28]. Kurihara K, Hashimoto N. The pathologic significance of Langerhans cell in oral cancer. *J Oral Pathol*, 1985;14(4):289–298.
- [29]. Gatter KC, Morris HB, Roach B, et al. Langerhans' cells and T-cells in human skin tumours: An immunohistological study. *Histopathology*, 1984;8(2): 229–244.
- [30]. van Heerden WFP, Raubenheimer EJ, van Rensburg EJ, et al. Lack of correlation between DNA ploidy, Langerhans cells population and grading in oral squamous cell carcinoma. *J Oral Pathol Med*, 1995;24(2): 61–65.
- [31]. Reichert TE, Scheuer C, Day R, et al. The number of intratumoral dendritic cells and  $\zeta$ -chain expression in T cells as prognostic and survival biomarkers in patients with oral carcinoma. *Cancer*. 2001;91(11): 2136–2147
- [32]. Kikuchi K, Kusama K, Taguchi K, et al. Dendritic cells in human squamous cell carcinoma of the oral cavity. *Anticancer Res*, 2002;22(2A):545–557.
- [33]. Lee BP, Juvet SC, Zhang L. Prostaglandin E2 signalling through prostanoid receptor 2 impairs proliferative response of double negative regulatory cells. *Int Immunopharmacol* 2009;9(5): 534–39.
- [34]. Michailidou EZ, Markopolos AK, Antoniadis DZ. Mast cells and angiogenesis in oral malignant and premalignant lesions. *Open Dent J* 2008;2:126–32.
- [35]. Ch'ng S, Wallis RA, Yuan L, Davis PF, Tan ST. Mast cells and cutaneous malignancies. *Mod Pathol*, 2006;19(1):149–59.
- [36]. Marshall JS. Mast cell responses to pathogens. *Nat Rev Immunol* 2004;4(10):787–99.
- [37]. Cormack DH. *Essential histology*. Lippincott Williams & Wilkins; 2001. pp 129
- [38]. Norrby K. Mast cells and angiogenesis. *Apmis*. 2002;110(5):355–71.
- [39]. Walsh LJ, Trinchieri G, Waldorf HA, Whitaker D, Murphy GF. Human dermal mast cells contain and release tumor necrosis factor alpha, which induces endothelial leukocyte adhesion molecule 1. *Proceedings of the National Academy of Sciences.* 1991;88(10):4220–4

Sanpreet S Sachdev, et al. "Correlation between Langerhans cells and mast cells in Oral Squamous Cell Carcinoma – An insight." *IOSR Journal of Dental and Medical Sciences (IOSR-JDMS)*, 19(3), 2020, pp. 01-07.