

Management of Intracranial Epidural Haematoma

Nasiru Jinjiri Ismail, Ali Lasseini

Regional Centre for Neurosurgery (RCN), Usmanu Danfodiyo University Teaching Hospital, Sokoto, Nigeria.

Corresponding Author: Dr Nasiru Jinjiri Ismail

Regional Centre for Neurosurgery (RCN), UDUTH, Sokoto, Nigeria.

Abstracts

Background

Intracranial epidural haematoma (EDH) is one of the common causes of death and disability in patients with head injury globally. Urgent cranial computerized tomography (CT) scan is needed for the definitive diagnosis, while adequate resuscitation and prompt surgical intervention when indicated results in good neurological outcome.

Objective of the Study

The objective of this study was to outline the profile of intracranial epidural haematoma managed in our institution.

Methods

A retrospective analysis of patients with diagnosis of intracranial epidural haematoma managed between January 2014 and December 2018.

Results

We found a total of forty patients managed over the study period. Males constituted the majority (36/40) with male to female ratio of 9:1. Eighty-three percent (n=33) of the patients were between eleven to forty years. None of the patient had health insurance coverage. A significant number of patients (n=27, 67.5%) presented between one to seven days of injury. All patients had cranial computerised tomography(CT) scan, but only 62.5% (n=25) got the scan done within 24 hours of admission. Thirty-three patients (83%) underwent surgical operation; 4 within one day, 23 between one to seven days, while 6 after seven days of admission. Thirty-three patients recovered fully, four had residual deficits, and three cases of mortality recorded.

Conclusion

Intracranial epidural haematoma affects young males predominantly in our settings. Most patients present acutely within first week of head injury and had surgical intervention. The outcome was generally good although, three mortality was recorded.

Keywords: intracranial epidural haematoma, traumatic brain injury, management.

Date of Submission: 17-03-2020

Date of Acceptance: 02-04-2020

I. Introduction

Head injury is the leading cause of morbidity and mortality in individuals of reproductive age globally.^{1,2,3} Generally, head injury has a reported mortality of up to 29%, and rising to 37% in cases of severe head injury.^{4,5} Epidural(extradural) haematoma is among the major causes of death and disability in patients with head injury.^{3,6} It is the accumulation of blood in the space between the inner table of the skull and the dura matter.^{3,7} It classically follows disruption of the middle meningeal artery with consequent bleeding that separates the dura from the inner table.⁶ Other sources of bleeding include the dural veins and the diploe of fractured skull bone.

Intracranial epidural haematoma occurs in about 1-3% of head injury⁸ and 5-15% of fatal head injuries, and commonly affects male patients between 10 to 60years of age.⁹ Epidural haematoma may present acutely within minutes of the injury or several hours later with altered sensorium and/or other features of raised intracranial pressure. It can also occur rarely in a chronic fashion.⁹ A non-contrast computerized tomography scan is usually preferred in the evaluation of epidural haematoma, timely and adequate resuscitation and surgical evacuation is paramount in reducing morbidity and mortality. Non-operative management can be done in certain cases of epidural haematoma with no indication for surgical intervention.

Objective

The objective of this study was to outline the profile of intracranial epidural haematoma managed in our institution.

II. Methods

The study was a retrospective analysis of patients with epidural haematoma managed in our institution between January 2014 to December 2018. Relevant clinical and radiological information was obtained from patients' medical records and analysed.

III. Results

We found a total of 40 patients managed over the study period. Ninety percent (36/40) of the patients were male, between the ages of 11 to 30 (67.5%).

Table 1: Distribution based on age at presentation

Age group (years)	Frequency	percentage
<11	2	5.0
11-20	14	35
21-30	13	32.5
31-40	6	15
41-50	3	7.5
>50	2	5.0
Total	40	100.0

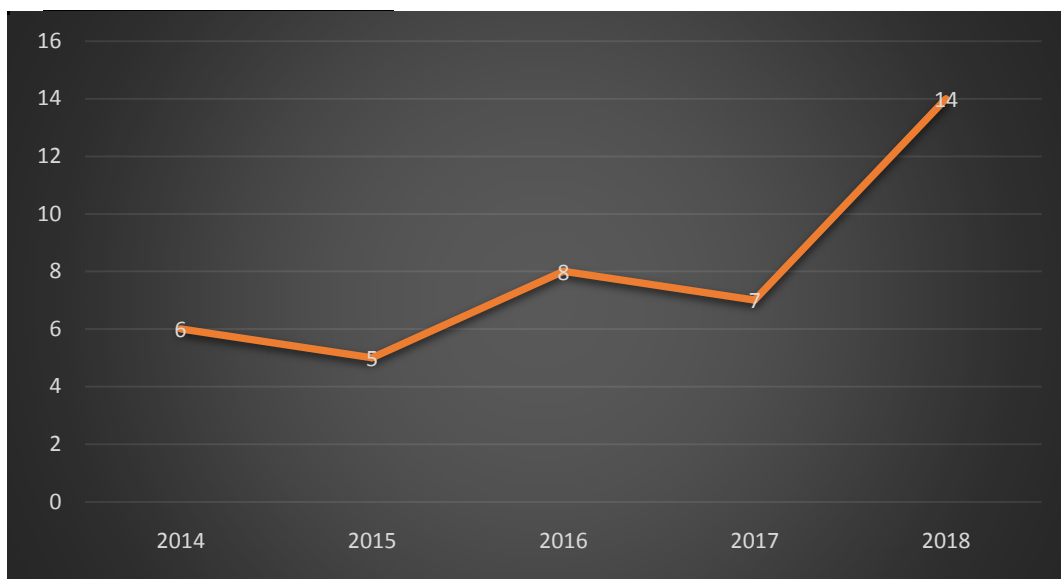


Figure 1: Distribution based on year of occurrence of Epidural haematoma

Road traffic accident was the leading cause of the head injury (65%) followed by assault (20%). The commonest presenting symptoms was transient loss of consciousness (LOC) followed by vomiting and then headache. (table 2)

Table 2: Clinical features

Clinical feature	Frequency	Percentage
Loss of consciousness	40	100
Headache	22	55
Vomiting	24	60
seizure	6	15
Motor deficit	19	47.5
Lucid interval	9	22.5

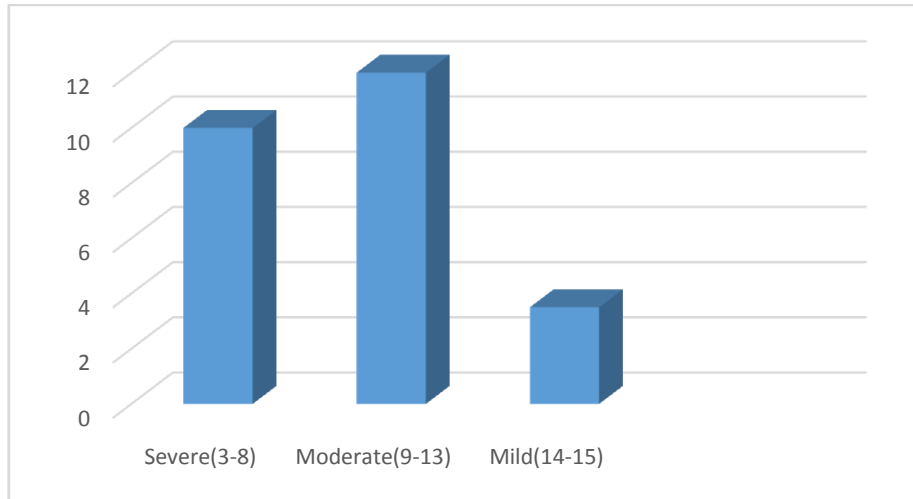


Figure 2: Glasgow coma score at presentation

Majority of patients presented with Glasgow coma score between 9-13 (figure 2). Twenty-seven patients presented between 1 to 7 days of injury, 9 patients came to hospital within 24 hours of injury, while 4 patients presented after a week of head injury.

Temporo-parietal was the commonest site of haematoma collection (15/40), followed by parieto-occipital (9/40), frontal (6/40), temporal (4/40), fronto-temporal (4/40) with one case each for posterior fossa and bifrontal area.

Majority of patients had surgical evacuation of the haematoma (33/40) while four patients were managed conservatively. Two patients discharged themselves against medical advice while one died before surgical intervention.

Table 3: Treatment Outcome

Outcome	Frequency	Percentage
Good recovery	33	82.5
Residual motor deficit	4	10.0
Death	3	7.5
Total	40.0	100.0

Sixty five percent of the patients (26/40) were referred from other states with the closest being about 150km away our facility. This was due to lack of imaging facilities and/or neurosurgical services in the referring centres. Half of the patients spent 10-20 days on admission, 12 patients were on admission for less than 10 days while 8 patients stayed on admission for more than 20 days.

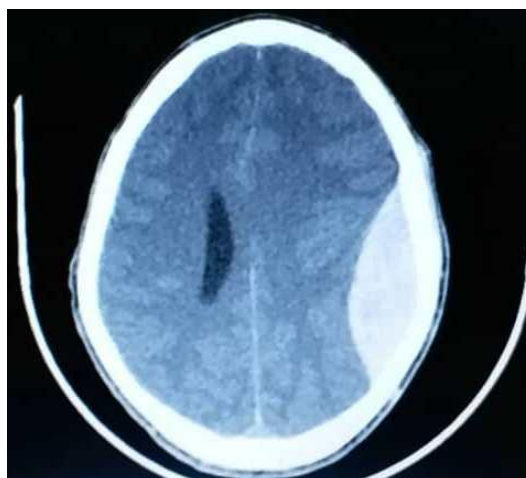


Figure 3: Axial cut computerised tomography scan showing parietal epidural haematoma

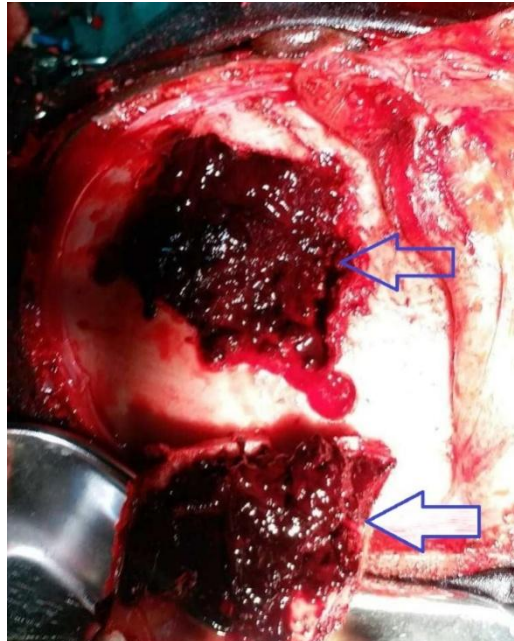


Figure 4: intraoperative photograph showing epidural haematoma with bone flap raised.

IV. Discussion

Intracranial epidural haematoma occurs most commonly in young male individuals in our society (table 1). This further corroborates other findings in the literature.^{2,3,9} while the commonest site remains the temporoparietal region which contains the commonest source of the bleeding. The incidence is on the rise (figure 1) probably because of increasing population, use of automobiles, rates of violence, and use of neuroimaging in the evaluation of head injured patients. Road traffic accident is the leading cause of intracranial epidural haematoma (figure 3 and 4) in our environment, followed by assault and then fall from height, with very rare incidence of sport-related injuries. Unlike the findings of a study in Korea that reported falls to account for most causes of epidural haematoma.¹⁰ Altered conscious level, headache and motor deficits were the main clinical features observed in our patients (table 2). It's of note that, less than one quarter of the patients presented with the classic lucid interval. This similar to the finding of previous study.¹¹

The management of head injury and intracranial epidural haematoma in our settings is quite challenging because of delays in presentation, neuroimaging, and surgical intervention. This is due to poor health insurance coverage as most patients had to settle hospital bills from their pockets. This is further compounded by the low socioeconomic status of most of the populace. The outcome of management was fairly good though a significant mortality was recorded (table 3).

V. Conclusion

Intracranial epidural haematoma affects young males predominantly in our settings. Most patients present acutely within first week of head injury and had surgical intervention. The outcome was generally good although, three mortality was recorded.

References

- [1]. Respicious B, Edwin RL, Abel MN, Othman K. Management and outcome of traumatic brain injury patients at Muhimbili Orthopaedic Institute Dar es Salam, Tanzania. *Pan Afr Med J.* 2017;26:140
- [2]. Qureshi JS, et al. Head injury triage in a sub Saharan African Urban Population. *International Journal of Surgery.* 2013;11:265-269
- [3]. Dakurah TK, Abdullah HM, Adams F, Bannerman-Williams E, Abaidoo B. Retrospective descriptive study on Non-operative Management of Epidural Haematoma in a cohort of Patients at the Korle Bu Teaching Hospital. *Clin Surg.* 2017;2:1802
- [4]. Muhammad I. Management of head injury at ABU Hospital, Zaria. *East Afr Med J.* 1990;67:447-51
- [5]. Nnadi MO, Bankole OB, Fente BG. Outcome of head injury in a tertiary hospital in Niger Delta, Nigeria: A prospective study. *Afr J Med Health Sci.* 2014;13:51-5
- [6]. Rosyidi RM, Priyanto B, AlFauzi A, Sutiono AB. Toward zero mortality in acute epidural hematoma: A review in 268 cases problem and challenges in the developing country. *Interdisciplinary Neurosurgery.* 2019;17:12-18
- [7]. Kiboi JG, Nganga HK, Kitunguu PK, Mbuthia JM. Factors Influencing the Outcome in Extradural Haematoma Patients. *The Annals of African Surgery.* 2015;12(1):14-18
- [8]. Dr Md Sarwar et al. Association of skull fracture with extradural haematoma in patients with head injury. *Journal of Medical Science and Clinical Research.* 2019;7(1):946-951
- [9]. Ghosh P, Roy K, Saha SK, Nadkarni A, Dixit S. Delayed presenting traumatic Extradural Haematoma. *Asian Journal of Medical Sciences.* 2018;9(4):41-45

- [10]. Jeong Y.H, Ji W.O, Cho S. Clinical Outcome of Acute Epidural Hematoma in Korea: Preliminary Report of 285 Cases Registered in the Korean Trauma Data Bank System. *Korean J Neurotrauma* 2016;12(2):47-54
- [11]. Greenberg M.S. *Handbook of Neurosurgery*. Seventh edition, page 894, 2010, thieme, Greenberg Graphics, inc, Tampa, Florida.

Nasiru Jinjiri Ismail, et al. "Management of Intracranial Epidural Haematoma." *IOSR Journal of Dental and Medical Sciences (IOSR-JDMS)*, 19(3), 2020, pp. 51-55.