

## Fibrous Dysplasia of the Proximal Femur with Hip Osteoarthritis Treated with Total Hip Arthroplasty: A Case Report and Literature Review

Abdirahman Ahmed Osman<sup>1</sup>, Jinwu Bai<sup>2</sup>, MohamedDiatyDiarra<sup>3</sup>,  
Qiang Zheng\* M.D, PhD

<sup>1</sup>Department of Orthopedics, the Second Affiliated Hospital, Zhejiang University School of Medicine, Zhejiang University, Hangzhou 310009, People's Republic of China

<sup>2</sup>Department of Orthopedics, the Second Affiliated Hospital, Zhejiang University School of Medicine, Zhejiang University, Hangzhou 310009, People's Republic of China.

<sup>3</sup>Department of Orthopedics Hospital of Hangzhou Normal university

Corresponding Author to: Qiang Zheng\* M.D, PhD

\*Department of Orthopedics, the Second Affiliated Hospital, Zhejiang University School of Medicine, Zhejiang University, Hangzhou 310009, People's Republic of China.

**Abstract:** The Fibrous dysplasia (FD) is an uncommon benign skeletal lesion of bone that may involve one bone (monostotic) or multiple bones (polyostotic). It most commonly occurred in the long bone, ribs, and craniofacial bones. But the condition of fibrous dysplasia of the proximal femur accompanying hip osteoarthritis treated with total hip arthroplasty is rare. We describe a case of fibrous dysplasia of the proximal femur with hip osteoarthritis treated with total hip arthroplasty.

**Key Word:** fibrous dysplasia, Osteoarthritis, total hip arthroplasty

Date of Submission: 02-03-2020

Date of Acceptance: 17-03-2020

### I. Introduction

Fibrous dysplasia (FD) is a rare benign bone tumor and non-neoplastic fibro-osseous lesion of the bone, accounting for approximately 5% to 7% of benign bone tumors. [1]The gene involved in pathogenesis of FD is located at 20q13.2-13.3 that encodes the  $\alpha$  subunit of stimulatory G protein ( $G_{s\alpha}$ ). [2]FD can present in one bone (monostotic) or multiple bones (polyostotic) and rarely be associated with some conditions such as McCune-Albright syndrome. [1]It may occur in any bone but is most common in the proximal femur, tibia, ribs, and skull. It affects slightly more males than females. Most patients with FD are asymptomatic. However fibrous dysplasia may be painful or cause swelling. It can cause repeated pathologic fractures or severe bone deformity, such as the "shepherd's crook" varus deformity of the proximal femur. Osteoarthritis (OA) is a degenerative condition as a result of mechanical overload in a weight bearing joint. [3]OA of hip is a common disease that is one of the top 15 contributors of global disability. [4] It is prevalent in 10% of people above 65, where 50% of these cases are symptomatic [5].

To our knowledge, OA of the hip was found in 13% of patients with FD of the proximal femur. [6] Although total hip arthroplasty (THA) is the ultimate treatment for end-stage hip osteoarthritis, which has obtained a satisfactory effect, the abnormal length of bone and the shape of medullary cavity caused by the lesion that on account of FD greatly increase the difficulty of the THA operation. In order to treat FD of proximal femur combined with OA of hip, we used Zimmer's Wagner SL Distal fixation of long-handled prosthesis system, which resolved the deformity of proximal femur and showed an excellent short-term outcome. We aimed to provide any consideration that include the design and modus of THA operation for these patients who are diagnosed FD accompanying OA. The purpose is to present the detailed design, perioperative management and evaluate short-term clinical outcomes of this novel therapeutic method.

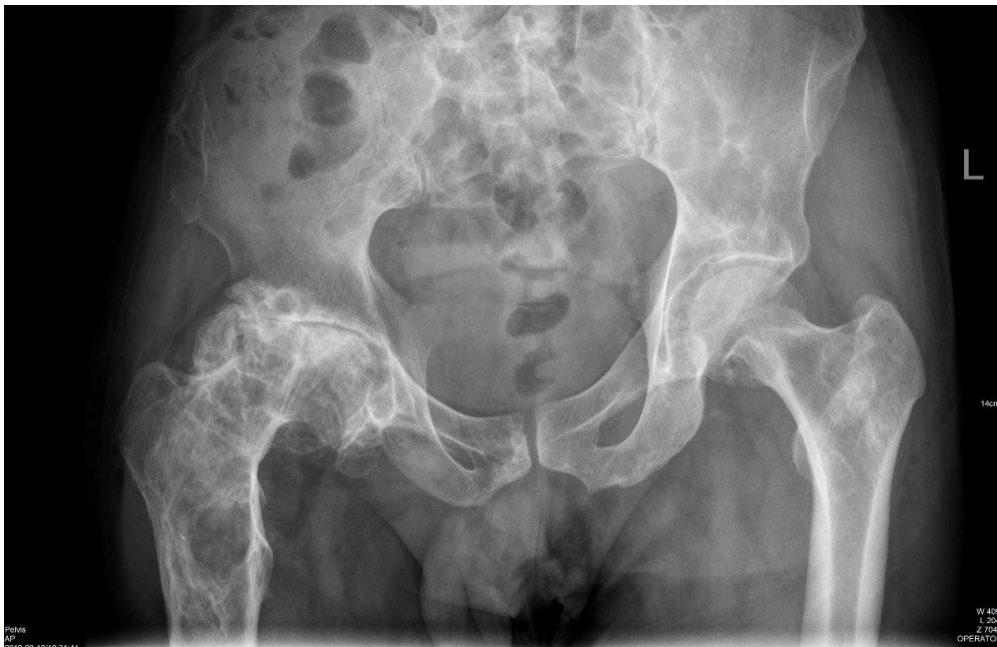### II. Case Report:

A 53-year-old man presented to the orthopedic clinic of our institution with a severe and progressive mechanical pain localized to his right hip, which has a ten years' history with right hip pain. At age 43, the patient occurred firstly intermittent pain in his right hip that was mild and tolerable. In the subsequent ten decades, the right hip pain presented a reduplicative and progressive pain and tardily impaired the quality of his daily life. And

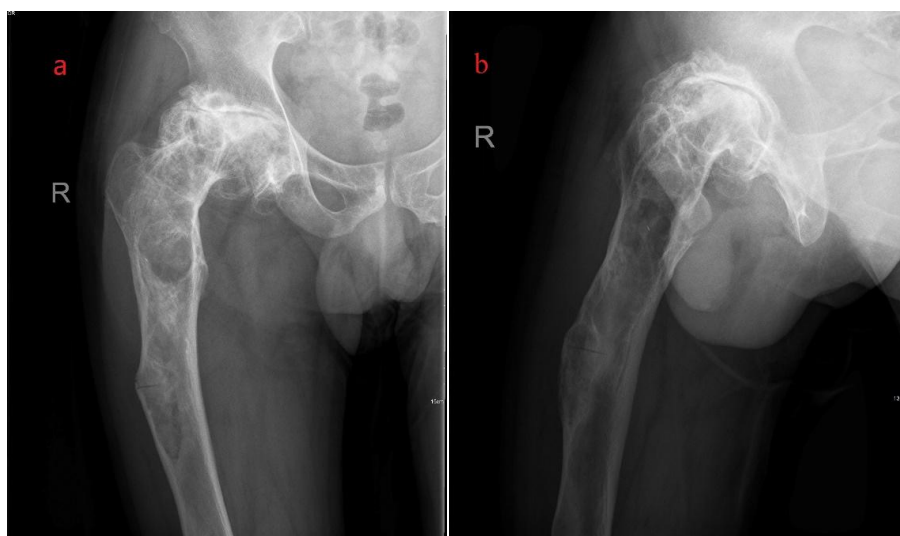
*Fibrous Dysplasia of the Proximal Femur with Hip Osteoarthritis Treated with Total Hip Arthroplasty..*

at age 53, he not only occurred severe and insupportable pain that aggravate after activity, but accompanied limited motion.His medical history was otherwise unremarkable. The physical sigh appeared the right hip pain without high skin temperature and completely restricted motion. The Patrick sign is positive and other positive signs was not found or drawn out. The plain radiographs were performed and demonstrated a slightly distended appearance in the proximal of the bilateral femur and left ilium with nonuniform bone density.(Figure 1, 2a and 2b) In addition, there had a transparent fracture line in the proximal of right femur and narrow right hip joint space. (Figure 1)

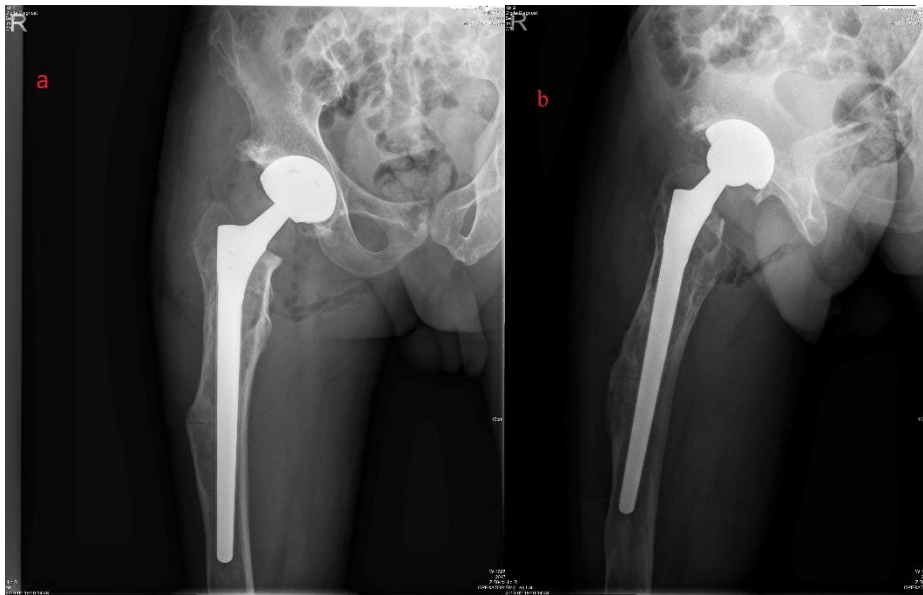
Four days after admission, the patient underwent a surgery of right total hip arthroplasty.The procedure was performed under a general anesthetic condition. We carried out the posterolateral approach of the hip and the skin, subcutaneous tissue and iliotibial band were cut layer by layer. Then we exposed hip articular capsule and incise it along the neck of the femur after separated surrounding muscle groups and protect ischiatic nerve. Then femoral neck osteotomy was performed 1cm above the medial flat trochanter to remove the femoral head and part of the femoral neck and the 48mm diameter metal acetabular cup was selected to imbedding into acetabulum for the purpose of maintaining proper abduction and rake angle. Finally, the artificial prosthetic joint (provided by Zimmer) was imbedded after expanding and drilling the medullary cavity. And the plain radiographs after the right THA demonstrated the location and angle of artificial joint was fine. (Figure 3a and 3b). The patient had been maintaining a good quality of daily life during the half year's follow-up.



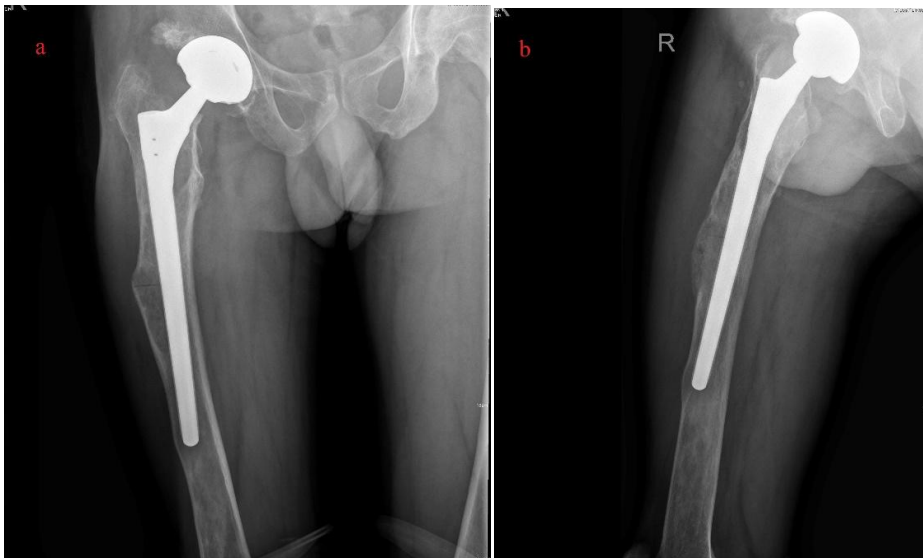**Fig. 1** An AP radiograph of the pelvis



**Fig. 2** Plain film before the surgery(a) Plain film AP view. (b) Plain film lateral view.



**Fig. 3** Plain film after the surgery. (a) Plain film AP view. (b) Plain film lateralview.



**Fig. 3** Plain film after half years' follow up. (a) Plain film AP view. (b) Plain film lateralview.

### III. Discussion:

Fibrous dysplasia is a benign fibro-osseous lesion that can occur in either monostotic or polyostotic forms, which accounting for approximately 5% to 7% of benign bone tumors.[1], [7]Kim, H.S. et al [6] found that the incidence of hip OA is 13% in patients with FD of the proximal femur. Deformity of the proximal femur in fibrous dysplasia leads to deviation of the mechanical axis of the hip, which may lead to the development of secondary osteoarthritis (OA).

In our case the patient, we provided the artificial prosthetic joint (provide by Zimmer) was imbedded after expanding and drilling the medullary cavity. The plain radiographs were performed and demonstrated a slightly distended appearance in the proximal of the bilateral femur and left ilium with nonuniform bone density. The patient had been maintaining a good quality of daily life during the half year's follow-up. Now the treatment of FD is limited to maintenance of maximum bone density via diet, exercise, and therapeutic medications. It will be recommended a surgical intervene when the bowing deformities and fractures occur. Our case existed an apparent deformity and transparent fracture line of the proximal femur, who also accompanying OA of hip. We found that can resolve the deformity of proximal femur and showed an excellent short-term outcome by using Zimmer's Wagner SL Distal fixation of long-handled prosthesis system. Furthermore, there had a huge difficult of THA surgery in this case because of the abnormal medullary space. Therefore, we must consider the possibility of femur lateral osteotomy and bone grafting and maybe adopt combination of prostheses. The current conventional

treatment methods (drugs and surgical indications), as well as the specific surgical options, are difficult to perform in our case, but the results are good, and the subsequent follow-up shows good functional recovery. Certainly, the long term follow-up result need to further evaluation and more cases.

#### **IV. Conclusion**

Fibrous dysplasia is a rare benign bone neoplasm that occurs most frequently in the long bones. Clinicians should primarily be able to distinguish themselves from other bony lesions. Surgery should be delayed to completion of the growth spurt. Therefore patient should be noted until the surgery is performed and regular follow-up should be performed. It is preferred to use most frequently conservative therapy such as modeling and recontouring. Another option for surgical management is radical excision and reconstruction.

#### **References:**

- [1]. DiCaprio, M.R. and W.F. Enneking, *Fibrous dysplasia. Pathophysiology, evaluation, and treatment.* J Bone Joint Surg Am, 2005. **87**(8): p. 1848-64.
- [2]. Riddle, N.D. and M.M. Bui, *Fibrous dysplasia.* Arch Pathol Lab Med, 2013. **137**(1): p. 134-8.
- [3]. Murphy, N.J., J.P. Eyles, and D.J. Hunter, *Hip Osteoarthritis: Etiopathogenesis and Implications for Management.* Adv Ther, 2016. **33**(11): p. 1921-1946.
- [4]. Cross, M., et al., *The global burden of hip and knee osteoarthritis: estimates from the global burden of disease 2010 study.* Ann Rheum Dis, 2014. **73**(7): p. 1323-30.
- [5]. Nuesch, E., et al., *All cause and disease specific mortality in patients with knee or hip osteoarthritis: population based cohort study.* Bmj, 2011. **342**: p. d1165.
- [6]. Kim, H.S., S.B. Im, and I. Han, *Osteoarthritis of the hip in fibrous dysplasia of the proximal femur.* Bone Joint J, 2015. **97-b**(7): p. 1007-11.
- [7]. Fletcher, C.D., K.K. Unni, and F. Mertens, *Pathology and genetics of tumours of soft tissue and bone.* Vol. 4. 2002: Iarc.

Qiang Zheng\* M.D, PhD, etal. "Fibrous Dysplasia of the Proximal Femur with Hip Osteoarthritis Treated with Total Hip Arthroplasty: A Case Report and Literature Review." *IOSR Journal of Dental and Medical Sciences (IOSR-JDMS)*, 19(3), 2020, pp. 15-18.