

Correction of class II malocclusion with molar distalization and fixed appliance treatment- A case report

Dr. Priya mol M G¹, Dr. Madhu S², Dr.Kannan Vadakkepurayil³

Abstract: A 11 year old male patient presented with class II malocclusion on a class I skeletal base, deep bite and minor space deficiency in the maxillary arch. A non extraction treatment was planned by using pendulum appliance in conjunction with anterior bite plane to correct the deep bite and distalize molars bilaterally. Within the duration of 4 months a total of 4mm space was created distal to maxillary right & left premolar. The treatment was completed with fixed appliance therapy.

Key Words: Molar distalization, Stainless steel wire(SS), Nickel Titanium archwire (Ni Ti), Titanium-molybdenum alloy (TMA) or Beta titanium

Date of Submission: 10-06-2020

Date of Acceptance: 27-06-2020

I. Introduction

Mild to moderate space deficiency can be successfully corrected by using expansion appliances, extraction and proximal slicing. Most traditional approaches to molar distalization include extraoral traction, Wilson distalizing arches, removable spring appliances, and intermaxillary elastics with sliding jigs, which require considerable patient compliance to be successful. More recently, the subjectivity and problems of predicting patient behavior have led many clinicians to devise appliances that minimized reliance on the patient and that are under the control of the clinician¹.

Pendulum is a fixed orthodontic appliance, developed by **James J. Hilgers** in 1992, that use forces to distalize the upper 1st molars to create space for eruption of impacted teeth or allowing correction of Class 2 malocclusion. This appliance is a fixed type of distalizing appliance that does not depend on the compliance of each patient to work. Components of the appliance are

- Nance Acrylic Button
- TMA Springs (0.032 in) Wire component includes closed helix, small horizontal loop and
- a wire connecting to bands on 1st molar and 2nd premolar

The TMA springs are used to deliver a light, continuous force to the upper first molars without affecting the palatal button. The appliance produces a broad pendulum of force from the mid palate to the upper molars.²

In this case, pendulum appliance with anterior bite plane was planned for molar distalization and deep bite correction respectively. Followed by fixed appliance treatment has been considered for the final teeth alignment in the maxillary arch.

II. Case Report

A 11 year old male patient reported to the Dept. of Pedodontics & Preventive dentistry with chief complaints of retruded upper front teeth. His facial form was mesoprosopic and symmetric (Figure 1). Clinical examination revealed lip incompetency with incisor display, mild retroclination of maxillary incisors and deep bite (Figure:2). He had an end on molar relation on left side and class II molar relation on right side, insufficient space for erupting right and left maxillary canines.(Figure :3)

The lower arch was normal in alignment, all teeth were erupted, no dental abnormalities was found.

Patient's photographs and a diagnostic casts were made on the initial visit. The patient was instructed to take lateral cephalogramme and orthopantomograph on the 2nd appointment (Figure 4).

Panoramic radiogram showed nollas stage 7 of maxillary and mandibular second molar. Cephalometric analysis indicated Skeletal Class I base, created by the combination of an orthognathic maxilla and a horizontal mandibular growth pattern.

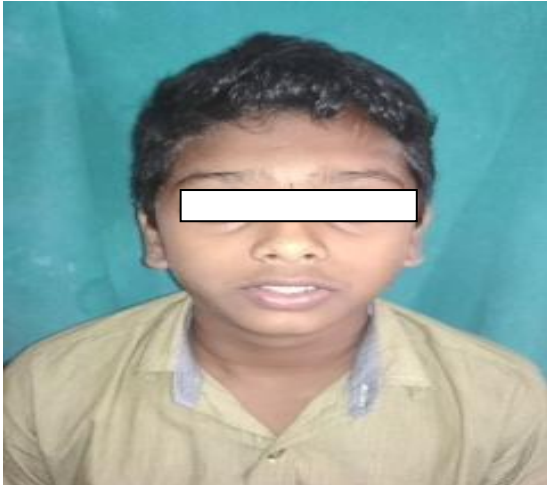

Figure: 1 Extra oral Frontal view

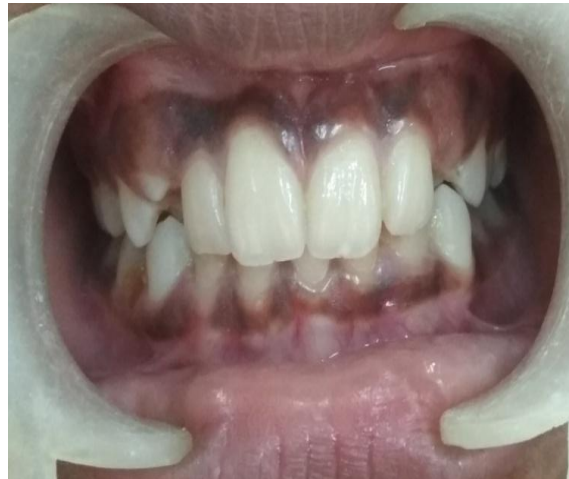

Figure :2 Intra oral Frontal view

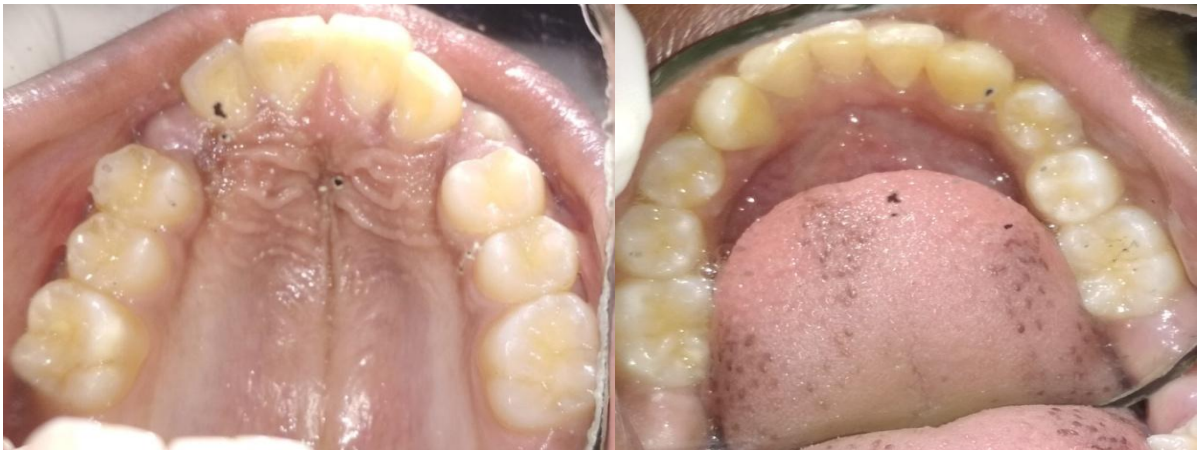

Figure:3 intra oral view(maxillary & mandibular arch)

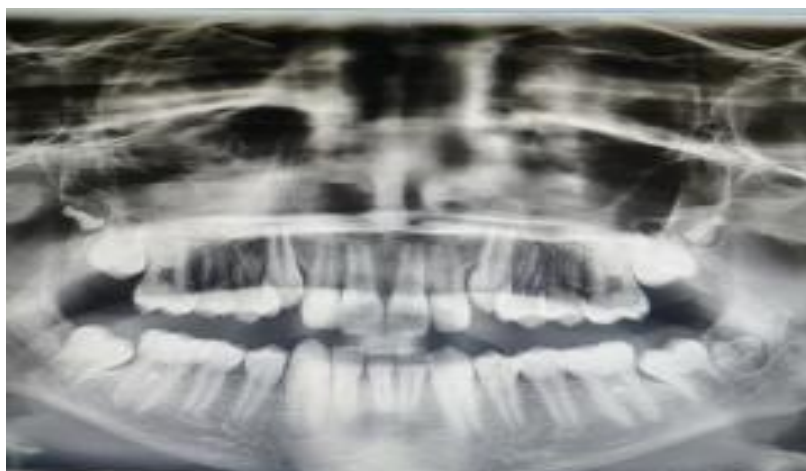


Figure: 4 Orthopantomograph

During the beginning of treatment, right and left maxillary canines were in Nolla's stage 8, only a portion of incisal tip had been ruptured through the oral mucosa and it was slightly labial in their eruption path. Hence, radiographs and diagnostic cast was used for calculating the required space and space availability. The resultant analysis has shown a space deficiency of 7 mm in the maxillary arch to accommodate the erupting canines.

Treatment objectives

- To create space in the right and left canine region
- To correct deep bite
- To correct end on molar relation on left side & class II on right side
- To align all the teeth in maxillary arch

Treatment plan

It was planned at a two step procedure

- **1st step**

Distalization of maxillary right & left molar was planned using pendulum appliance. Also a nance palatal button was incorporated into the appliance to correct the deep bite at the same time.

- **2nd step**

Once space created on the canine region and deep bite has been corrected ,fixed appliance treatment was planned for alignment.

Treatment procedure

Molar band with soldered buccal and palatal tube, a removable spring along with labially extended nance palatal button and premolar band, these were the two parts of the appliance used for the present case(Figure:5). In the third visit, the right & left maxillary molars were banded and bonded. The fabricated pendulum appliance was taken into the oral cavity, premolar band was cemented on the first premolar just before the posterior portion of the appliance inserted into the molar tube soldered into the banded maxillary molars.

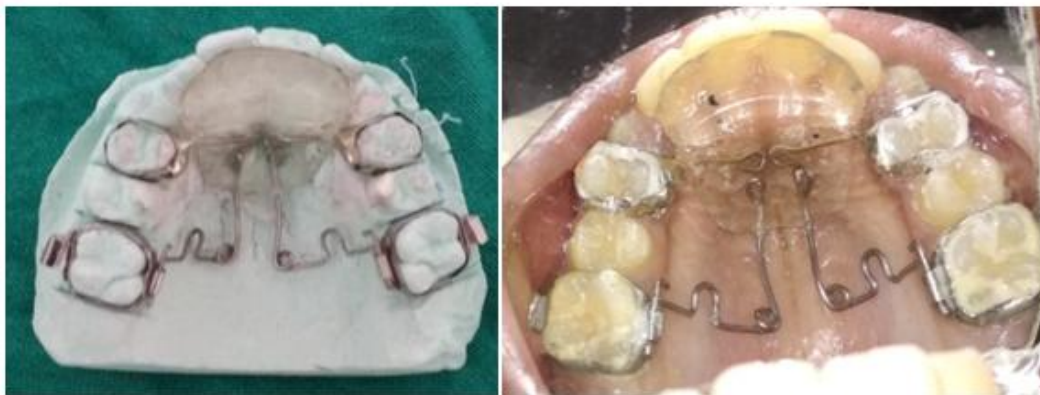

Figure 5: Pendulum appliance

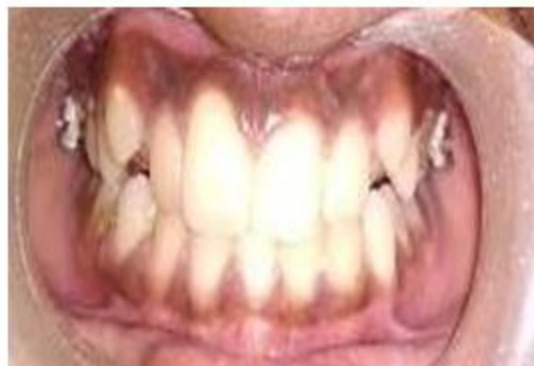

Figure: 6 (Frontal view at 4 month)

The patient was recalled every 3 weeks to activate the helices. At the end of 4th month sufficient space was regained and the left maxillary canine was started to erupt into the space gained (Figure:6). The right maxillary canine has been started to erupt labially, which shows 3mm space deficiency. In order to overcome this problem, we have planned a second stage treatment for space creation in the right maxillary canine region and their subsequent alignment all around the dental arch.

Correction of class II malocclusion with molar distalization and fixed appliance treatment- A case ..

During the second stage pendulum appliance was removed. Brackets were placed on the etched & bonded tooth surface except for right maxillary canine. Initially, 0.014 Ni Ti was placed for the tooth alignment 1 month later all teeth has been aligned properly (Figure:7). Later, round stainless steel wire placed along with open coil spring (Figure:8).

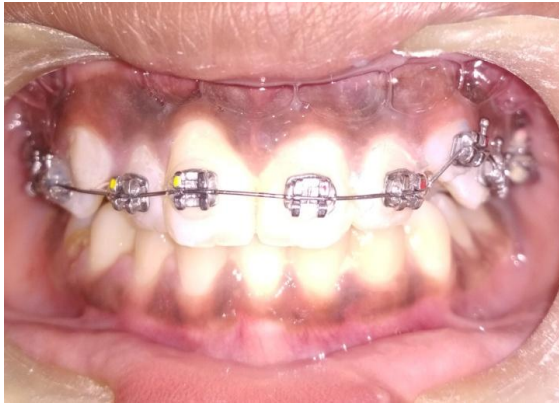

Figure: 7 (0.014 Ni Ti)

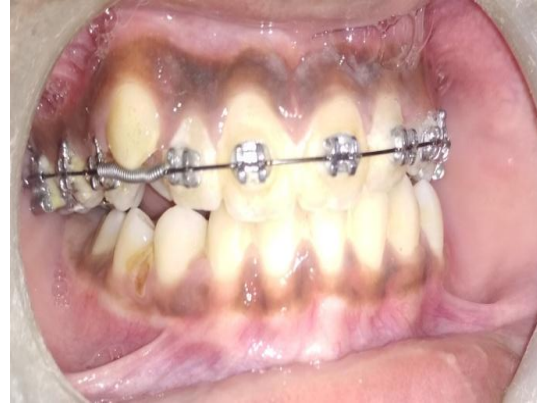

Figure : 8 (Open coil spring in round stainless steel wire)

A premolar bracket was bonded on the palatal aspect of right first premolar .Ligature wire was passively attached from the bracket and tied to the molar tube to prevent mesial rotation of premolar (Figure: 9)

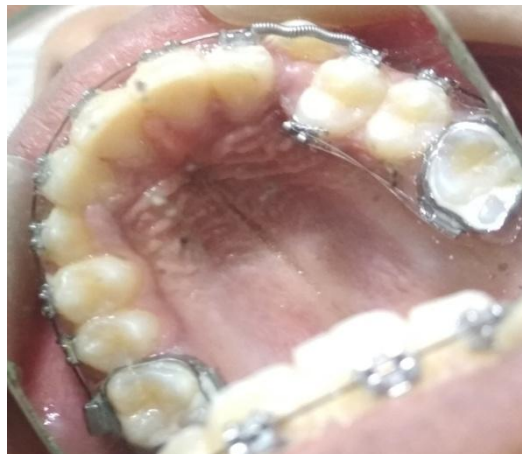

Figure: 9 Palatal view of space creation on right canine region

One month later, on recall visit sufficient space was created for the erupting 13. Round wire and open coil spring was removed , a bracket was attached on the labial surface of 13.The 0.014 Ni Ti wire has been placed for the alignment of 13.Patient was recalled after I month on examination it has been aligned to the correct occlusal level. The 0.014 Ni Ti wire was replaced with round 0.014 and subsequently,0.018 SS wire.

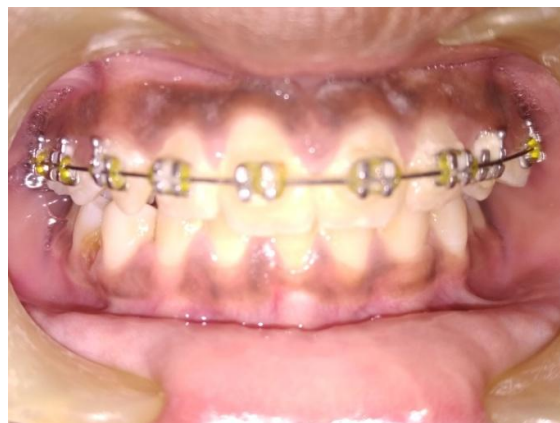

Figure: 10 (Final alignment with round SS wire)

Instructed the patient to revisit every 3 weeks interval to check the integrity of brackets and to measure the oral hygiene. On 12th recall visits, all teeth were in good alignment, deep bite was corrected. Brackets, arch wire and molar tubes were removed, scaling was done and an upper impression was made for retainer. Patient was recalled after 3 days for the insertion of retainer (Figure: 11).

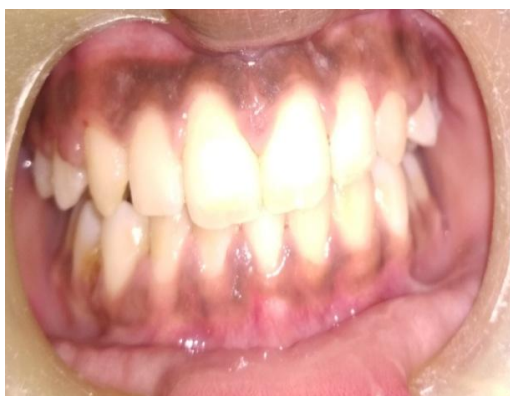

Figure 10: post operative view

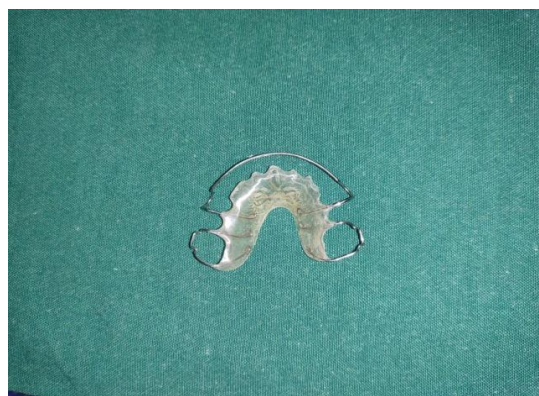

Figure 11: Retainer

III. Discussion

Patient co-operation and good diagnosis is very important while planning pendulum appliance. It is usually indicated to correct class II malocclusion or end on molar relation on a skeletal class I base with a normal mandible, to relieve mild to moderate crowding before the eruption of upper 2nd molar, to correct midline discrepancy. Distal movement of the molars appear to be most efficient before the upper second molars have erupted. Influence of second molar on the distal movement of the first molar is remain as a controversy.

Pendulum appliance provide a force range from 100-250 grams to produce a broad, swinging arc (or pendulum) of force from the midline of palate to the upper first molars. Bodily movements are not possible with pendulum appliance, distal tipping of root followed by uprighting is the resultant effect. Previous studies have showed that the pendulum appliance produces a molar distalization between 3.14 and 6.1 mm.

Ghosh and Nanda¹ evaluated the intra-oral maxillary molar distalization using pendulum appliances. They reported that molar distalization is at the expense of moderate anchorage loss causing proclination of the upper incisors and a wedging bite opening tendency when the appliance is tooth born. Therefore, in the current case report, we decided to use the pendulum appliance with palatal coverage to minimise such an effect

The anterior acrylic portion of the appliance can be kept in place with occlusally bonded rest or soldered to bands on first or second bicuspid. In this case, the nance palatal button has been slightly modified like an anterior bite plane in order to relieve the deep bite at the same time. Springs are incorporated parallel to the mid sagittal plane. The U loop is incorporated into the spring, to which necessary adjustments can be made to correct the crossbite produced by the molar, as it distalize.

Pendulum appliance is activated by bending the helix 90 degree outward, just before cementation of the band is done on the premolars, 30 degree is lost during insertion of appliance, which produces 60 degree activation after insertion.

If the loop of the helix is not activated properly this may lead to unwanted rotation of the molar. Food accumulation under the palatal acrylic plate may cause tissue irritation in the rughae area, these are considered to be the most common disadvantages of the pendulum appliance. Periodic follow up and necessary adjustments are required for the successful treatment outcome

IV. Conclusion

Pendulum appliance is a non invasive appliance which has been effectively employed to establish space gaining (upto 3-4mm) through molar distalization. Minimal patient co-operation is needed to provide successful treatment outcome. In this case report the patient had a total of 7mm space deficiency, 4mm of space was achieved distal to the second premolar within 4 months. When compared to extraction correction, it offer better patient compliance, lesser treatment duration, the need for frequent visit for bracket displacement is reduced especially in child patient. The remaining 4mm of space creation and final alignment had been accomplished with fixed appliance treatment.

References

- [1]. Paranna S, Shetty P, Anandakrishna L, Rawat A. Distalization of Maxillary First Permanent Molar by Pendulum Appliance in Mixed Dentition Period. *International journal of clinical pediatric dentistry*. 2017 Jul;10(3):299.
- [2]. Kaur S, Soni S, Garg V, Maninderdeep K, Singh R. Pendulum appliance and its modifications-A review. *Int. J. Curr. Res. Med. Sci*. 2018;4(3):1-9.
- [3]. Dr. Shruti Gupta, Dr. Kamlesh Garg, Dr. Sumit Jain, Dr. Ankita Sinha and Dr. Shikha Singh. 2018 Pendulum appliance for correction of minor crowding with Class II div 1 subdivision malocclusion *International Journal of Current Research* 10, (02) ,65608-65613.
- [4]. Ghosh J, Nanda RS. Evaluation of an intraoral maxillary molar distalization technique. *American Journal of Orthodontics and Dentofacial Orthopedics*. 1996 Dec 1;110(6):639-46.

Dr. Priya mol M G, et. al. "Correction of class II malocclusion with molar distalization and fixed appliance treatment- A case report." *IOSR Journal of Dental and Medical Sciences (IOSR-JDMS)*, 19(6), 2020, pp. 62-67.