

Best vitelliform macular dystrophy

Karmoun S* and Amhoud K* and Tamym B* and Elhassan A* and
Aboulanouar A* and Berraho A

Service d'ophtalmologie B, Hôpital des spécialités de Rabat, Morocco

*Corresponding author: KARMOUN SOUHAILA, Service d'ophtalmologie B, Hôpital des spécialités de Rabat, Morocco

Abstract:

First described by Adams in 1883, but named for Dr. Friedrich Best, Best vitelliform macular dystrophy, or Best disease, is a hereditary retinal dystrophy involving the retinal pigment epithelium (RPE), and leads to a characteristic bilateral yellow "egg-yolk" appearance of the macula. This disease tends to present itself in childhood or early adulthood and usually portends a good visual prognosis. BVMD is the most common autosomal dominant macular dystrophy [1] [2]. BVMD is inherited in an autosomal dominant fashion, but shows incomplete penetration and variable expressivity; this variability occurs both between families and within families [3]. The appearance of the vitelliform lesion usually occurs in the ages of 3-15 years old, but can be seen in the later decades of life.

Date of Submission: 12-06-2020

Date of Acceptance: 29-06-2020

I. Introduction

Best vitelliform dystrophy is an inherited retinal disease involving the retinal pigment epithelium (RPE), leading to a characteristic bilateral yellow "egg yolk" appearance in the macula. The causative gene (BEST 1/VMD2) encodes the trans-membrane protein bestrophin 1, causing abnormal chloride channel conductance, disrupting fluid transport across the RPE, and affecting RPE metabolism.

II. Case Report :

A 50-year-old patient presented with a central visual field depression in both of eyes since 2 months. He complained of a recent onset of centrally scattered scotomas, accompanied by decreased visual acuity in both of eyes. He reported no other ocular or systemic symptoms or complications. Visual acuity was 4/10 which cannot be improved in both of eyes. The anterior Biomicroscopy revealed a cortico-nuclear cataract. The fundus examination revealed the existence of "scrambled egg appearance", it corresponds to an inhomogeneous dispersion of the yolk material, in the macula in both of eyes. The vitreous is transparent, the examination of the retinal periphery was normal.

The OCT of both of eyes, performed, shows an hypo-reflectivity in the resorption zones of material, giving way to an optically empty zone and an hyper-reflectivity at the residual material (figure 1, figure 2). In pseudo-hypopion, the upper part, which corresponds to the resorbed vitelliform material, results in an hypo-reflective zone with an optically empty cavity above the pigment epithelium. The lower part of the pseudo-hypopion, which corresponds to the sedimentation of the vitelliform material, results in OCT by an hyper-reflective filling of this space below the pigment epithelium .

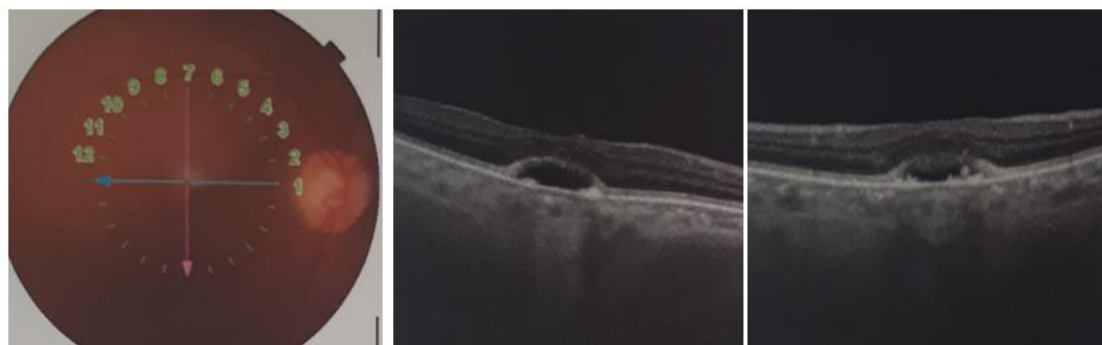


Figure 1 : The OCT right eye : shows an hypo-reflectivity in the resorption zones of material, giving way to an optically empty zone and an hyper-reflectivity at the residual material

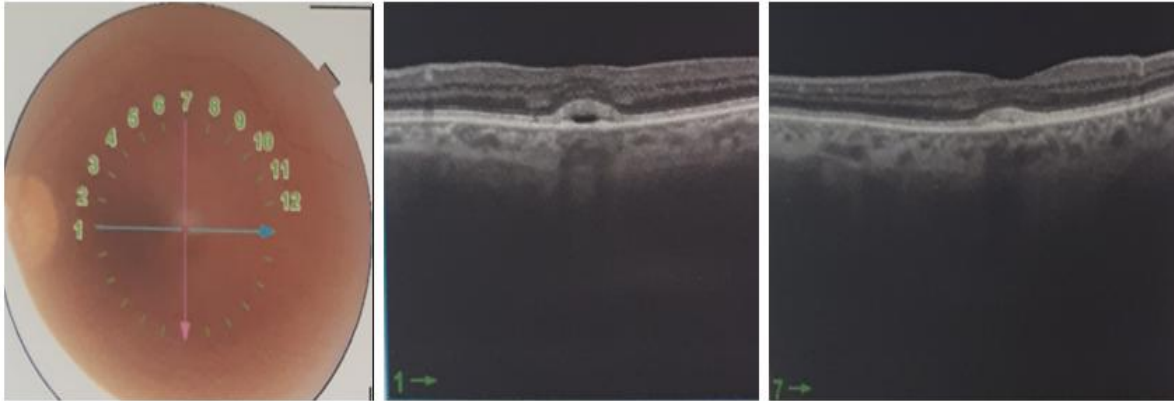


Figure 2 : The OCT left eye shows an hypo-reflectivity in the resorption zones of material, giving way to an optically empty zone and an hyper-reflectivity at the residual material

III. Discussion :

Best's disease is a rare, incurable, autosomal dominant, slowly developing vitelliform (yolk-like) macular dystrophy associated with central visual disturbance and loss. The disease is limited to macular anomalies, excluding systemic associations. There is no gender predisposition [4].

Best disease is classically a bilateral process but may be asymmetric. Abnormal chloride channel function in the RPE leads to the eventual buildup of lipofuscin between the outer retina and the RPE, causing a yellow vitelliform lesion in the macula [5]. The disease evolves over five clinical stages. In the previtelliform stage, there are subtle RPE changes and minimal changes in vision. The vitelliform stage is marked by the classic "egg yolk" appearance and is followed by the pseudohypopyon stage with layering of the lipofuscin. Then the vitellidisruptive or "scrambled egg" stage occurs and is followed by atrophy and focal scar in the final stage. Often, visual acuity is minimally affected, especially in the early stages of the disease. Patients may note gradual vision loss or metamorphopsia as the disease progresses. Rarely, the disease can be complicated by secondary choroidal neovascularization (CNV), which can cause rapid significant vision loss [6].

OCT demonstrates varying findings as the disease progresses. In the preclinical or previtelliform stage, OCT demonstrates thickening and increased hyper-reflectivity at the level of the photoreceptor outer segments. In the vitelliform stage, OCT reveals hyper-reflective dome-shaped material in the subretinal space, as well as persistent thickening of the photoreceptor outer segments. In the pseudohypopyon stage, the retina is elevated, with a clear space between the neurosensory retina and the RPE. In the vitelli-disruptive stage, there may be hyper-reflective sub-retinal mounds at the level of the RPE, with either underlying shadowing or increased hyper-reflectivity of the underlying choroid and associated thinning of the outer retinal layers. In the atrophic stage, OCT shows overall thinning of the neurosensory retina and absent or thin ellipsoid zone or photoreceptor complex [7,8].

In the case in question, the OCT confirmed a Best macular dystrophy in the pseudo-hypopyon stage.

Currently, treatments for Best's disease are limited. Cystic lesions may subside after administration of oral acetazolamide. Subfoveal choroidal neovascularization (CNV), which may be detected through close monitoring of the disease in its later stages, should be treated promptly to preserve visual acuity.

For our patient no treatment has been started, the patient benefits from close monitoring to detect any complications related to his disease.

IV. Conclusion

Best's disease is a complex and potentially beguiling condition that raises diagnostic challenges and defies a cookbook approach to management. Treatments are also not very promising.

References

- [1]. Schachat A.P., Wilisison CP., Hinton DR., Satta SR., Wiedemann P. *Ryan's Retina* 6th edition, Elsevier (2018)
- [2]. Chowers I. et al. Adult-onset foveomacular vitelliform dystrophy: A fresh perspective. *Prog Retin Eye Res.* 2015 Jul;47:64-85. doi: 10.1016/j.preteyeres.2015.02.001
- [3]. Johnson AA et al. Bestrophin 1 and Retinal Disease. *Prog Retin Eye Res.* 2017 May ;58: 45–69. doi:10.1016/j.preteyeres.2017.01.006
- [4]. Boon CJ, Theelen T, Hoefsloot EH, et al. Clinical and molecular genetic analysis of best vitelliform macular dystrophy. *Retina.* 2009;29(6):835–847
- [5]. O'Gorman S, Flaherty WA, Fishman GA, Berson EL. Histopathologic findings in Best's vitelliform macular dystrophy. *Arch Ophthalmol.* 1988;106(9):1261–1268.
- [6]. Booi JC, Boon CJF, van Schooneveld MJ, et al. Course of visual decline in relation to the best1 genotype in vitelliform macular dystrophy. *Ophthalmology.* 2010;117(7):1415–1422.

- [7]. Ferrara DC, Costa RA, Tsang S, Calucci D, Jorge R, Freund KB. Multimodal fundus imaging in Best vitelliform macular dystrophy. *Graefes Arch Clin Exp Ophthalmol.* 2010;248(10):1377–1386.
- [8]. Querques G, Zerbib J, Georges A, et al. Multimodal analysis of the progression of Best vitelliform macular dystrophy. *Mol Vis.* 2014;20:575–592.

KARMOUN SOUHAILA, et. al. " Best vitelliform macular dystrophy." *IOSR Journal of Dental and Medical Sciences (IOSR-JDMS)*, 19(6), 2020, pp. 43-45.