

“Anatomy of Apical-third of Root Canal”

Dr. Aji Markose

Dept Of Conservative Dentistry, Vivekanandha Dental College
Tiruchengode, Namakkal (dt), Tamilnadu- 637205

Abstract: The portion of pulp tissue from the root canal orifice to apical foramen is the root canal (radicular pulp). It may be sectioned as coronal, middle and apical third. The root canal begins as a funnel shaped orifice, generally at the level or slightly apical to the cervical line and ends at the apical foramen. Accessory/Lateral canals are branching of main root canal.

Key Words: Apical Constriction, Apical Foramen, Apical delta, Cementodentinal Junction, Tooth Apex

Date of Submission: 01-06-2020

Date of Acceptance: 16-06-2020

I. Introduction

The Knowledge of anatomy of apical-third of root canal is mandatory to carry out successful endodontic procedures. The root apex visualizes the junction where dentin ends & the cementum/periodontal tissue begins. Following anatomic & histological landmarks are seen in the apical part of root canal.

II. Terminologies

Anatomic Apex: It is defined as the tip or the end of the root determined morphologically.

Radiographic Apex: It is defined as the tip or the end of the root determined radiographically.

Apical foramen (Major Diameter): It is an aperture at or near the apex of a tooth through which the blood vessels & nerves of the pulp enter and exit the pulp cavity.

Apical Constriction (Minor diameter): It is the apical part of root canal with the narrowest diameter short of apical foramen or radiographic apex.

Accessory canal: They are lateral branching of the main root canal generally occurring in the apical third or furcation area of a root.

Lateral canal: They are accessory canal that branches to the lateral surface of the root and may be visible on a radiograph.

Accessory Foramina: They are openings of the accessory & lateral canals in the root surface.

Apical Delta: It is a triangular area of root surrounded by main canal, accessory canals & periradicular tissues.

Cementodentinal Junction: It is the region where the dentin and cementum are united. It is a histologic landmark.

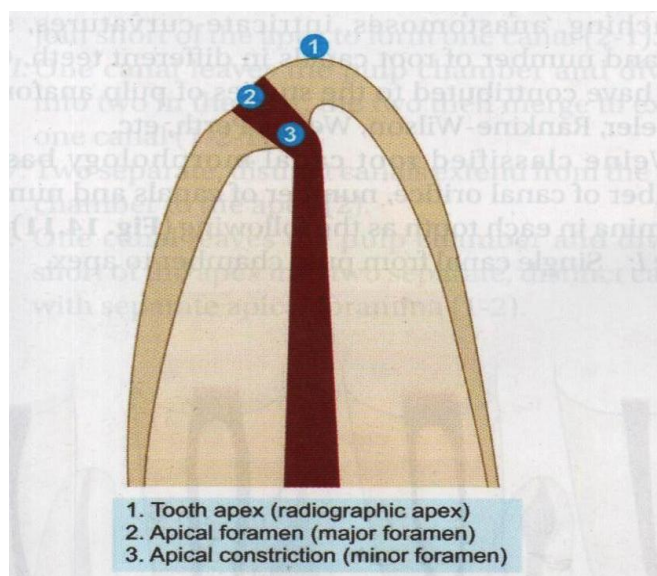


Fig.1 Diagram showing root apex

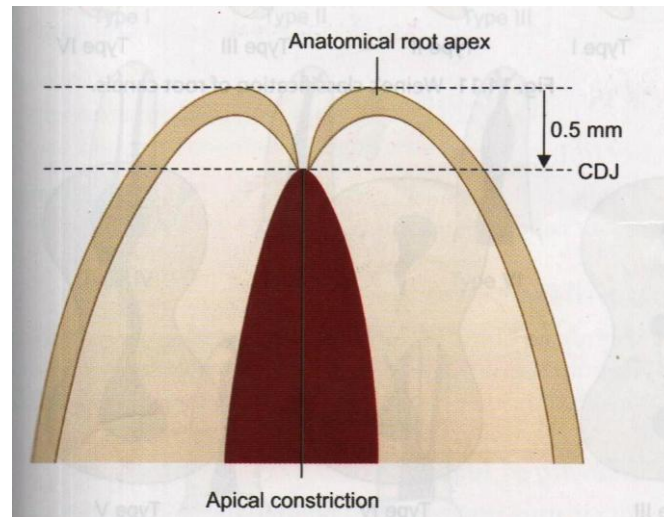


Fig.2 Position of C.D.J

III. Apical Constriction

The apical constriction is the apical portion of the root canal system having the narrowest diameter, usually referred to as the “*apical stop*”. It generally lies 0.5mm to 1.5 mm short of the apical foramen. The apical constriction is the junction where the pulpal tissue terminates & the periodontal tissue begins. The minor diameter widens apically to major diameter (apical foramen). Violation of this area by root canal instruments lead to postoperative discomfort & also delayed healing. The root canal instrumentation & obturation should be up to this constriction as it would serve as “apical dentin matrix”. Dummer et al described the configuration of apical constriction as of the following types.

- * Type A. Tapering single constriction.
- * Type B. Tapering constriction with the narrowest portion near the actual apex.
- * Type C. Constriction followed by another constriction (multiconstrictions)
- * Type D. Long parallel constriction

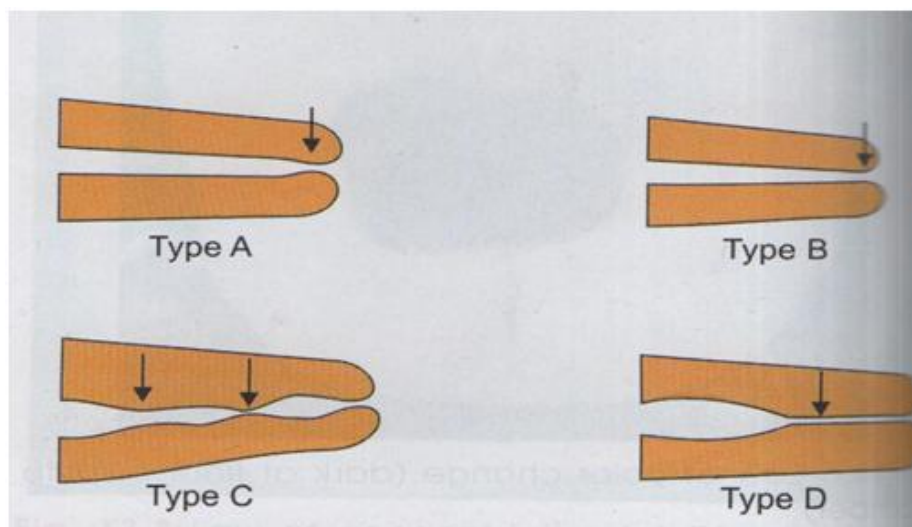


Fig.3 Shapes of Apical Constriction

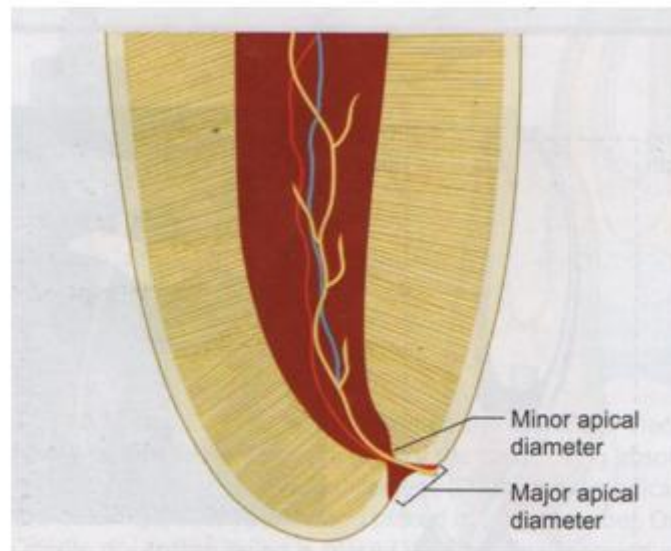


Fig.4 Major and Minor apical diameter

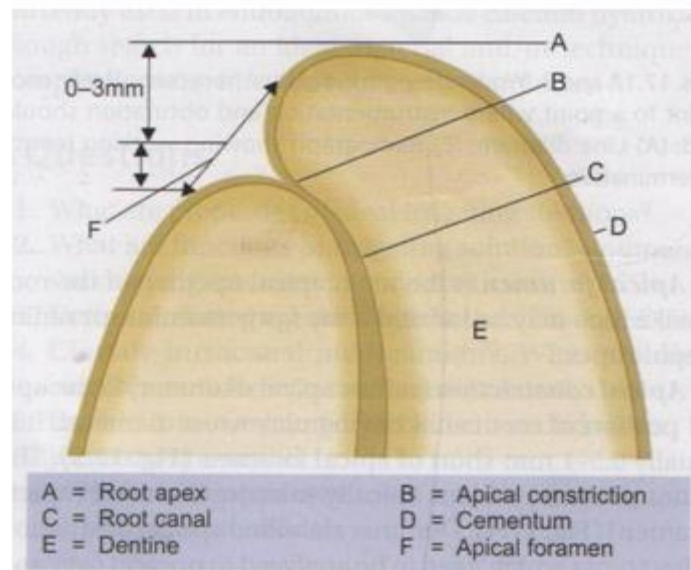


Fig.5 Anatomy of root apex

IV. Apical Foramen

Generally the apical foramen do not exit at the apex (mostly 0.5 - 1.0 mm offset from centre), may be mesial, distal, lingual or labial. In young incompletely developed tooth, the apical foramen is funnel shaped, with the wider portion extending outward known as “Blunder buss apex”. At that stage, the mouth of the funnel is filled with periodontal tissue that is later replaced by dentin & Cementum. As the root develops the apical foramen becomes narrower & farther from the apex. The space between the apical constriction & apical foramen takes a hyperbolic shape that resembles a “morning glory” flower. The mean distance between major & minor diameter (apical foramen & apical constriction) has been found to be .5 mm in Young teeth & .65 mm in older teeth.

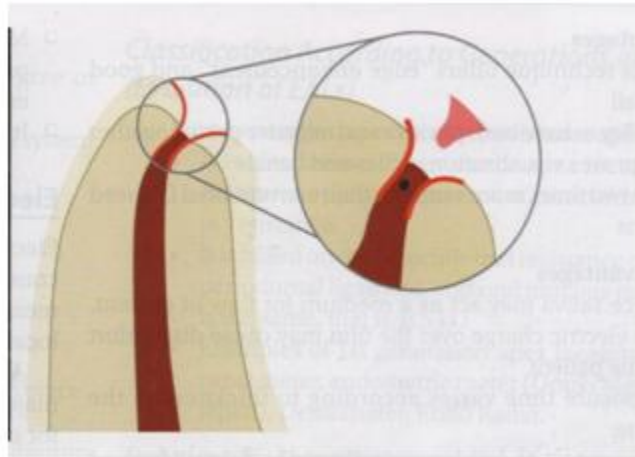


Fig.6 Morning glory appearance of apical third

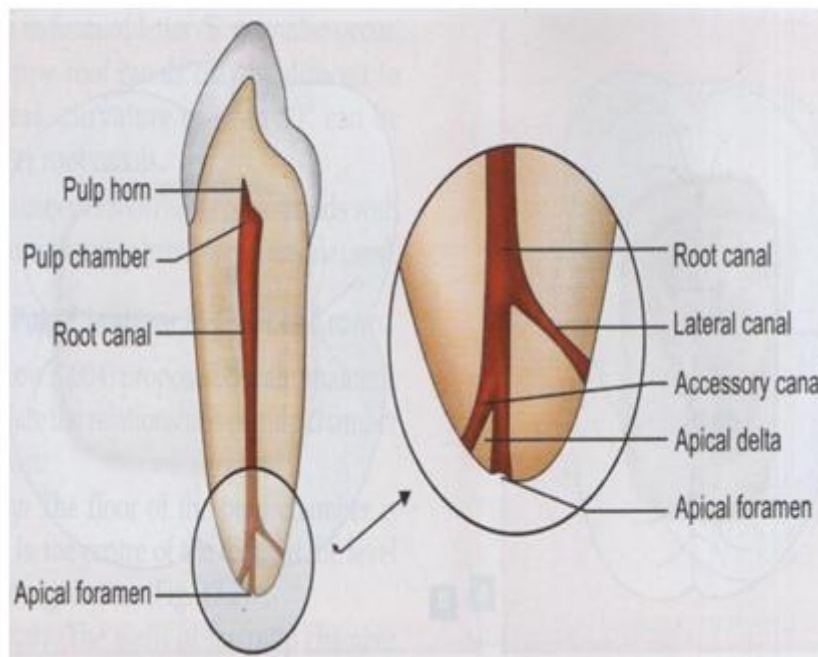


Fig.7 Apical third of Canal

The following features govern the configuration of the foramen:

- * As age increases, the center of the foramen deviates more & more from the vertex of apical center because of increase in thickness of the apical cementum.
- * The diameter of the foramen increases with age because of the apposition of new layers of cementum. The average diameter is somewhat larger buccolingually than mesiodistally.
- * The funnel shape of the Canal is accentuated in the older teeth because of widening of the foramen & narrowing of the canal
- * The average thickness of the apical cementum is 0.5mm in the younger age group & 0.67 mm in the older age group.

V. Cementodentinal Junction

It is the meeting point of dentin & cementum, where the pulp tissue ends & periodontal tissue begins. Due to the deposition of cementum, the location & diameter of the cementodentinal junction differ considerably. The exact position of the cementodentinal junction can only be determined histologically, but for clinical purpose, it is accepted that it almost coincides with the apical constriction. The location may not be the same as apical constriction area; on an average 1.0 mm short of apical foramen. The diameter of canal at cementodentinal junction vary considerably in different teeth.

VI. Kutlers Study

The apical foramen does not normally exit at the anatomic apex. It deviates by 0.5-3mm. This variation is more marked due to continuous deposition of cementum in older patients.

The distance of the minor diameter of the foramen from the cemental surface is at an average of 0.5mm in young teeth and 0.75mm in mature teeth.

VII. Variations in Apical third

Different Locations of Apical foramen

Apical Foramen may exit on mesial, distal, buccal or lingual surface of the root. It may also lie 2-3 mm away from the anatomic apex

Accessory & Lateral Canals

These are lateral branches of the main canal that form a communication between the pulp & periodontium. They can be seen anywhere from furcation to apex but tend to be more common in apical third of posterior teeth.

Open Apex

It occurs when there is periapical pathology before completion of root development as a result of trauma or injury causing pulpal exposure. In this, canal is wider at apex than at cervical area. It is also referred to as blunderbuss canal. In vital teeth with open apex, treatment is apexogenesis and in nonvital teeth, it is apexification

VIII. Conclusion

* Apical constriction acts as a natural stop for filling materials. Root canal treatment of apical part is difficult because of presence of accessory & lateral canals, pulp stones, varying amount of irregular secondary dentin & areas of resorption.

* Most of the curvatures occur in the apical third, so one has to be very careful during canal preparation.

* Size & shape of foramen should always be maintained. Apical 3 mm of root is generally resected during endodontic surgery in order to eliminate canal aberrations.

Declaration

I hereby declare that I am (author) responsible for the study & contents of the following manuscripts.

Bibliography

- [1]. Textbook of Endodontics, 4th Edition, Nisha Garg, Amit Garg
- [2]. Essentials of Endodontics, 2nd Edition, Vimal.K. Sikri
- [3]. Grossmans Endodontic Practice, 13th Edition
- [4]. Endodontics Principles & Practice, 5th Edition, Mahmoud Torabinejad, Richard E. Walton, Ashraf F. Foud
- [5]. Tikku AP, Pandey PW, Shukla I. Intricate internal anatomy of teeth & its clinical significance in endodontics: A review. Endodontology 2012;24:160-9
- [6]. Alothmani OS, Chandler NP & Friedlander LT. The anatomy of the root apex: a review & clinical considerations in endodontics. Saudi Endod J.: 2013; 3: 1-9
- [7]. Arora S and Tewari S. The morphology of the apical Foramen in posterior teeth in a North Indian Population. Int.Endod.J.: 2009; 42:930-939
- [8]. Carrotte P. Endodontics: Part 4. Morphology of the root canal system. Br. Dent.J.:2004; 197: 379-383
- [9]. Dummer PM, McGinn JH and Rees DG. The position & topography of the apical canal constriction and apical foramen. Int. Endod. J.: 1984; 17: 192-198
- [10]. Kartal N, Ozcelik B and Cimilli H. Root canal morphology of maxillary premolars, J.Endod.: 1998; 24:417- 419
- [11]. Kasahara E, Yasuda E, Yamamoto A and Anzai M. Root canal system of the maxillary central incisor. J. Endod.:1990; 16: 158-161
- [12]. Martos J, Lubian C, Silveria LF, de Castro LA & Ferrer Luque CM. Morphologic analysis of the root apex in human teeth. J Endod.: 2010; 36: 664-667

Dr. Aji Markose, et. al. “Anatomy of Apical-third of Root Canal.” *IOSR Journal of Dental and Medical Sciences (IOSR-JDMS)*, 19(6), 2020, pp. 53-57.