

Xanthogranulomatous Oophoritis – A Rare Entity

Bidhan C Nayak¹, Saptarshi Bhattacharya², Goutam Dey³,
Kabyashree Jana⁴

¹ (Senior Resident, Department of Pathology, Chhatna Superspeciality Hospital, Chhatna, Bankura, WB, India)

² (Senior Resident, Department of Pathology, Bankura Sammilani Medical College, Bankura, WB, India)

³ (Demonstrator, Department of Pathology, Deben Mahata Government Medical College and Hospital, Purulia, WB, India)

⁴ (Medical Officer, Department of Pathology, Raghunathpur Super speciality Hospital, Raghunathpur, Purulia, WB, India)

Abstract

Xanthogranulomatous oophoritis is a rare, non-neoplastic, chronic process, by which the affected organ is infiltrated by foamy histiocytes with multinucleated giant cells, fibroblast, plasma cells, lymphocytes and neutrophils, occasionally with areas of necrosis. It is often misdiagnosed as ovarian neoplasm that often leads to hysterectomy. Therefore, a very careful evaluation is important to diagnose the disease, and it becomes an important clinical entity. Very few cases of xanthogranulomatous oophoritis have been reported. We report a case of xanthogranulomatous oophoritis in a 33 years old female who presented with bleeding per vagina and abdominal pain.

Keywords: Xanthogranulomatous, oophoritis, foamy histiocytes, giant cells.

Date of Submission: 10-07-2021

Date of Acceptance: 26-07-2021

I. Introduction

Xanthogranulomatous inflammation is a chronic inflammation that involves various organs.^[1] It is an unusual type of inflammation that leads to tissue destruction by inflammatory cells composed of lipid containing foamy macrophages, plasma cells, lymphocytes, neutrophils and giant cells.^[2] The most commonly affected organs are the kidney and gallbladder, followed by anorectal area, bone, stomach, testis.^[3] Only a few cases involving the ovary have been reported till date.^[2] It presents as abdominal pain and bleeding per vagina. On clinical examination a mass in the pelvic cavity noted and mimic a neoplastic lesion clinically. Histopathological examination reveals xanthogranulomatous oophoritis.

II. Case Report

A 33 years old female presented with the chief complaints of abdominal pain and bleeding per vagina. On per vaginal examination a firm right adnexal mass palpated. Her blood investigations revealed normocytic normochromic anaemia, slightly raised total leucocyte count (12700/ μ l) with raised ESR (40 mm at 1st hour). CA 125 and CEA were within normal limit. Ultrasonography of abdomen and pelvis showed a thick-walled mass measuring (10 \times 8.5 \times 7) cm. Computed tomography of abdomen performed which showed a right adnexal mass which was cystic with enhancing irregular walls and multiple septations. An exploratory laparotomy was done followed by right sided salpingo-oophorectomy.

Grossly the tubo-ovarian mass had a white capsule measuring 12 cm in diameter and fallopian tube measuring in 5cm in length. On cut section, multiloculated cyst with solid areas noted. Thickness of the cyst wall was 1cm. Inner surface of the cyst was brownish.

On microscopic examination, ovarian stroma was found to be almost completely replaced by sheets of foamy histiocytes, admixed with lymphoplasmacytic infiltrate [Figure – 1] along with numerous multinucleated giant cells [Figure – 2]. No evidence of granuloma or malignancy seen in the sections studied.

The follow-up was uneventful and the patient was discharged in good health conditions.

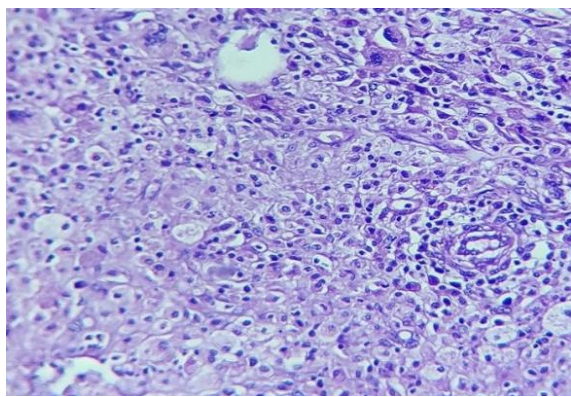


Figure 1. Ovarian stroma almost completely replaced by foamy histiocytes with lymphoplasmacytic infiltrate and multinucleated giant cells. (H and E, x40)

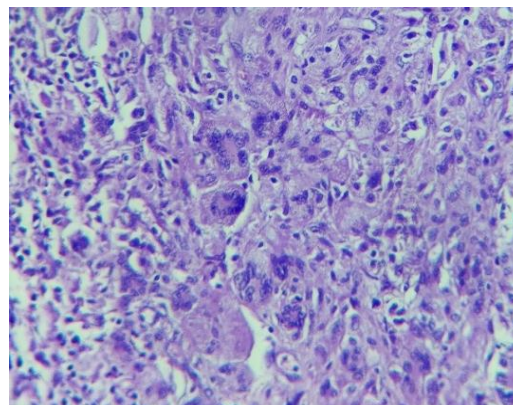


Figure 2. Numerous multinucleated giant cells with lymphocytes. (H and E, x40)

III. Discussion

Xanthogranulomatous oophoritis is a very rare form of chronic oophoritis.^[4] However, there are documented cases of involvement of vagina, cervix, fallopian tube and ovary.^[5] Previously, cases of xanthogranulomatous oophoritis have been reported in females of 23-72 years of age. However, a case of two years old female with xanthogranulomatous oophoritis is reported.^[1,6]

The pathogenesis of xanthogranulomatous oophoritis is unclear and many theories of etiopathogenesis have been postulated, such as theory of infection, endometriosis, intrauterine contraceptive device and drug induced. Amongst these theories, the most accepted theory is of infection, which is supported by clinical evidence of infection and growth of bacteria such as *Escherichia coli*, *Bacteroides fragilis* and *Proteus vulgaris* from the affected tissue culture.^[1] Punia et al., described xanthogranulomatous oophoritis and salpingitis as a late sequelae of inadequately treated pelvic inflammatory disease caused by *Staphylococcus* spp.^[7] Shukla et al. have reported a case of xanthogranulomatous oophoritis associated with primary infertility and endometriosis.^[2]

A number of reported cases in the past were misdiagnosed as ovarian cancers.^[8] Hence gynaecologists need to be aware of this entity and be able to differentiate it from endometrial, ovarian or tubal malignancy.

The gross examination of the affected ovary may show replacement by a well circumscribed, solid, yellowish, lobulated mass along with cystic changes.^[9]

Microscopically, it is characterized by a massive infiltration by lipid laden histiocytes known as Xanthoma cells and mixed with inflammatory infiltrates. Presence of foam cells makes malakoplakia an important differential diagnosis as suggested by Walther et al., which is then distinguished from xanthogranulomatous oophoritis by the presence of basophilic Michaelis-Gutmann bodies, which are absent in the latter.^[10] Immunohistochemical stains CD 68, CD 3 and CD 20 are helpful in diagnosis.^[4,11,12]

Differential diagnosis of xanthogranulomatous oophoritis includes tuberculosis and fungal infection which can be ruled out by culture and special stains for the causative organisms.^[13]

Secondary lymphoma/leukemia, when lymphocytes are scattered focally, malignant small round cell tumour with stromal leutinization when lymphocytes are distributed diffusely and have a paucity of foam cells, sclerosing tumour when areas of fibrosis are noted can mimic this condition and can be misdiagnosed as tumour.^[8] Frozen section can be performed in order to rule out malignancy.^[14]

IV. Conclusion

Xanthogranulomatous oophoritis is a rare entity, which can often be a diagnostic challenge for the clinician as clinico-radiological presentation often mimics malignancy. The pathologists need to be aware of this entity and careful histopathological evaluation is important.

Second, most of the patients using intra uterine contraceptive devices and those of pelvic inflammatory disease and endometriosis need close follow up, so that they are diagnosed early and radical surgery is avoided.

References

- [1]. Gray Y, Libbey NP. Xanthogranulomatous salpingitis and oophoritis: a case report and review of the literature. *Arch Pathol Lab Med.* 2001;125: p. 260-3.
- [2]. Shukla S, Pujani M, Singh SK. Xanthogranulomatous oophoritis associated with primary infertility and endometriosis. *Indian J Pathol Microbiol.* 2010; 53: p. 197-8.
- [3]. Bindu SM, Mahajan MS. Xanthogranuloma- tous oophoritis: A case report with review of literature. *Int J Health Allied Sci .* 2014;3:p.187-9.

- [4]. Raj JA, Jagadeesha M, Naveen S, Ramachandra U. Xanthogranulomatous oophoritis: pathologic findings with clinical correlation. *J Indian Med Assoc.* 2012;110:p.653-4
- [5]. D. Shilpa, S. Kalpana, B. Sachin, G. Alka, and N. Ramteerthkar. "Xanthogranulomatous oophoritis : case report." *Indian Journal of Basic & Applied Medical Research.* 2013; 2(7) : p. 745-749.
- [6]. Tanwar H, Joshi A, Wagaskar V, Kini S, Bachhav M. Xanthogranulomatous Salpingoophoritis: The Youngest Documented Case Report. *Case Rep Obstet Gynecol.* 2015
- [7]. Punia RS, Aggarwal R, Amanjit, Mohan H. Xanthogranulomatous oophoritis and salpingitis: late sequelae of inadequately treated staphylococcal PID. *Indian J Pathol Microbiol.* 2003;p.46:80.
- [8]. Kalloli M, Bafna UD, Mukherjee G, Devi UK, Gurubasavangouda, Rathod PS. A Rare Xanthogranulomatous oophoritis presenting as ovarian cancer. *Online J Health Allied Sci.* 2012;11:p.1-2.
- [9]. Naik M, Madiwale C, Vaideeswar P. Xanthogranulomatous oophoritis - A case report. *Indian J Pathol Microbiol* 1999;42:p.89-91
- [10]. Kishore SH, Rajshri OP, Dravid NV. Xanthogranulomatous oophoritis mimicking as an ovarian neoplasm. *J Case Reports.* 2014;4:p.100-3.
- [11]. Mahesh KU, Potekar RM, Yelikar BR, Pande P. Xanthogranulomatous oophoritis-masquerading as ovarian neoplasm. *Asian J Pharm and Sci.* 2012;2:p.308-9.
- [12]. Zhang XS, Dong HY, Zhang LL, Desouki MM, Zhao C. Xanthogranulomatous inflammation of the female genital tract: report of three cases. *J Cancer.* 2012;3: p.100-6
- [13]. Rawal G, Zaheer S, Dhawan I. Xanthogranulomatous Oophoritis Mimicking an Ovarian Neoplasm: A Rare Case Report. *Journal of Mid-Life Health.* 2018; 9(1): p. 41-43.
- [14]. Khan B, Aziz AB, Ahmed R. Case of Xanthogranulomatous Oophoritis. *J Ayub Med Coll Abbottabad.* 2017;29: p.162-4.

Bidhan C Nayak, et. al. "Xanthogranulomatous Oophoritis – A Rare Entity." *IOSR Journal of Dental and Medical Sciences (IOSR-JDMS)*, 20(07), 2021, pp. 35-37