

## A Multivariate Analysis of the Factors Affecting the Visual Outcome and Complications Following Scleral Fixated Intraocular Lens Implantation

Dr Anandalakshmi R, Dr. Pratheeba.M, Dr. Kalpana.P

<sup>1,2,3</sup>(Kancheepuram District Headquarters Hospital & DNB Training Institute)

**Abstract:** Cataract extraction is the most common intraocular surgery done worldwide<sup>1</sup>. The complication rate of cataract surgery is 1-2%. The most common intraocular complication is posterior capsular rent<sup>2</sup>. In cases of PCR, the surgeon can implant ACIOL, SFIOL or iris claw lenses. These special IOL implantations help to rehabilitate patients with postsurgical aphakia & cataracts with no posterior capsular support.

**AIM:** This study aims to determine the factors affecting the visual outcome and complications following scleral fixated intraocular lens implantation.

**MATERIALS AND METHODS:** In this prospective study totally 50 patients were included. After detailed preoperative evaluation, anterior vitrectomy with ab externo two point scleral fixated intraocular lens implantation was done by a single surgeon. Detailed post-operative evaluation was done. All these patients were followed up at 1, 4, 6 weeks and later followed up at 12 months. During follow-up visits various factors including preoperative, intraoperative and postoperative factors affecting the visual outcome and complications in this study group were analysed in detail.

**RESULTS:** The mean age of presentation in our study is 61.54 years. 58% of patients were between 45-65 yrs. In this study out of 50 patients 32(64%) were males and 18(36%) were females. 70% of cases were postsurgical aphakia at presentation. Most the patients presented within 2 to 6 months of duration of trauma or cataract surgery and SFIOL implantation. 11(22%) patients had visual acuity of 6/60 to 4/60 and 39(78%) patients had visual acuity of  $\leq 3/60$  at presentation. Most common preoperative complication factors were chronic uveitis(36%) and dislocated or subluxated lens(12%). In this study 60% of patients were operated within 60 minutes and 10% were operated for more than 90 minutes. Post operative iritis in 16(32%) patients, was the most common complication noticed during the post operative period in our study, followed by striate keratopathy and vitritis in 8(16%) and 6(12%) patients respectively. The post operative visual acuity at 1 week was between 6/18-6/36 in 46% of cases, 6/60 -4/60 in 46% of cases and  $\leq 3/60$  in 8% of cases. At 6 weeks majority (46%) had 6/6- 6/12 visual acuity and the remaining had 6/18-6/36 in 32% of cases and 6/60 - 4/60 in 22% cases. In our study 62% of patients had visual acuity of  $\geq 6/18$ . In the primary SFIOL group the success rate was 40% and 71% in the secondary SFIOL group. Post operative refraction was between -2.5 DS to 0 in 74% of patients in our study.

**CONCLUSION:** SFIOL plays an important role in the visual rehabilitation of patients with no capsular support. The statistically significant factors associated with poor visual outcome were preoperative factors like chronic uveitis and trauma, intraoperative factors like prolonged duration of surgery and post-operative complications like iritis and striate keratopathy. Visual outcome following secondary SFIOL implantation is better than primary SFIOL implantation. The final visual outcome depends on preoperative, intraoperative and postoperative factors.

**Keywords:** Aphakia, Cataract, Intraocular lens, scleral fixation

Date of Submission: 24-06-2021

Date of Acceptance: 07-07-2021

### I. Introduction

Cataract is the leading cause of reversible blindness throughout the world<sup>1</sup>. Cataractogenesis can be due to old age, trauma, congenital, infectious and metabolic causes<sup>2</sup>. It is estimated that in India alone people undergo 64 lakh cataract surgeries every year. Following uneventful cataract surgery, intraocular lens is usually implanted in the capsular bag. Patients with inadequate capsular support following cataract surgery, trauma or collagen vascular diseases can be visually rehabilitated with aphakic spectacles, contact lenses, anterior chamber intraocular lenses, iris fixated lenses and scleral fixated intraocular lenses. These intraocular lenses can be implanted as a primary or as a secondary procedure.

Since the discovery of the scleral fixated intraocular lenses by Parry<sup>3</sup> in 1950, various changes and various techniques have emerged for its fixation. Placement of the IOL in the posterior chamber, reduces the

risk of bullous keratopathy, damage to anterior chamber angle structures, damage to corneal endothelium, pupillary block glaucoma, and pseudophakodonesis<sup>4</sup>. In addition positioning the lens closer to the rotational centre of the eye, may reduce the centrifugal forces on the lens and stabilize the ocular contents, decrease the magnification associated with contact lenses, optical aberrations associated with aphakic spectacles and imparts superior optical properties to the eye<sup>5</sup>. Hence in this study, we aimed to determine the factors affecting the visual outcome following vitrectomy & scleral fixated intraocular lens implantation in post surgical aphakia, post traumatic cataract, subluxation of lens, anterior lens dislocation, spontaneous subluxation, anterior lens dislocation in collagen vascular diseases and pseudoexfoliation.

## **II. Aims & Objectives**

The primary objective was to determine the factors affecting the visual outcome following vitrectomy & scleral fixated intraocular lens implantation in post surgical aphakia, post traumatic cataract, subluxation of lens, anterior lens dislocation and spontaneous subluxation or anterior lens dislocation in collagen vascular diseases or pseudoexfoliation.

The secondary objective was to study about the various factors during SFIOL implantation. Preoperative factors like corneal opacity, striate keratopathy, chronic uveitis, cystoid macular edema, type of cataract surgery done, mode of injury, duration between trauma/cataract surgery and SFIOL implantation and associated systemic diseases. Intraoperative factors like duration of surgery, complications during SFIOL implantation. Postoperative complications like striate keratopathy, iritis, corneal decompensation (<500 cells/cu.mm), IOL malposition, cystoid macular edema (OCT thickness >250 $\mu$ ), retinal detachment, rise of IOP, endophthalmitis, vitritis. Measurement of refraction at the end of 6 weeks.

## **III. Materials And Methods**

This prospective study was conducted in Kancheepuram District Headquarters Hospital & DNB Training Institute from December 2013 to January 2020 for a period of 6 years. All patients with postsurgical aphakia, posttraumatic cataract, posttraumatic subluxation/ anterior dislocation, spontaneous subluxated or anteriorly dislocated lenses, patients with endothelial cell count >1200 cells/cu.mm were included in the study.

Patients with endothelial cell count less than 1200 cells/cu.mm, retinal detachment, vision not improving with aphakic correction, macular disorder, previous intraocular surgery other than cataract surgery and corneal tear suturing were excluded from the study.

## **IV. Methodology**

In this study totally 50 patients were included based on the inclusion criteria. Pre-operative evaluation in these patients include visual acuity by Snellen's chart, applanation tonometry, Slit lamp biomicroscopy, B-Scan Ultrasonography, A-Scan Biometry, Keratometry, Indirect ophthalmoscopy, Specular Microscopy, Blood sugar, Optical coherence Tomography.

1. Anterior vitrectomy with ab externo two point scleral fixated intraocular lens implantation was done with Aurolab single piece SFIOL (with overall diameter of 13 mm and optic diameter of 6 mm with single eyelet at each haptic) and 10-0 polypropylene suture by a single surgeon.

2. Postoperatively patients were treated with topical eyedrops like 1% prednisolone acetate & 0.5% moxifloxacin 6 times/day tapered over 6 weeks, 0.5% ketorolac tromethamine 4 times/day for 1 week and Prednisolone tablets 1mg/kg in cases of vitritis which was tapered later.

3. Postoperative evaluation included-visual acuity by Snellen's chart, applanation tonometry, Slit lamp biomicroscopy, indirect ophthalmoscopy and specular microscopy, OCT,UBM.

4. During the follow up period of 1,4,6 weeks and late follow up at 12 months complications if any were treated, retinoscopic refraction was done and best glasses were prescribed. Success rate of the surgery was defined as vision  $\geq$ 6/18.

## **SCREENING & FOLLOW UP PROCEDURES**

Best corrected Snellen's visual acuity, IOP, Indirect ophthalmoscopic examination, Slit lamp biomicroscopy, A-Scan Biometry & Keratometry, B-scan ultrasonography, specular microscopy, OCT for macular thickness, X-ray orbit (if required), Blood sugar, specular microscopy,UBM, retinoscopic refraction. Follow up done at 1,2,4, 6 weeks and 12 months.

## **ASSESSMENT OF PARAMETERS**

a) Age, sex, Visual acuity better in which group.

b) Pre-operative factors were corneal opacity, striate keratopathy, chronic uveitis, cystoid macular edema, type of cataract surgery done, mode of injury, duration between trauma/cataract surgery and SFIOL implantation, associated systemic diseases. Intraoperative factors like duration of surgery, complications during

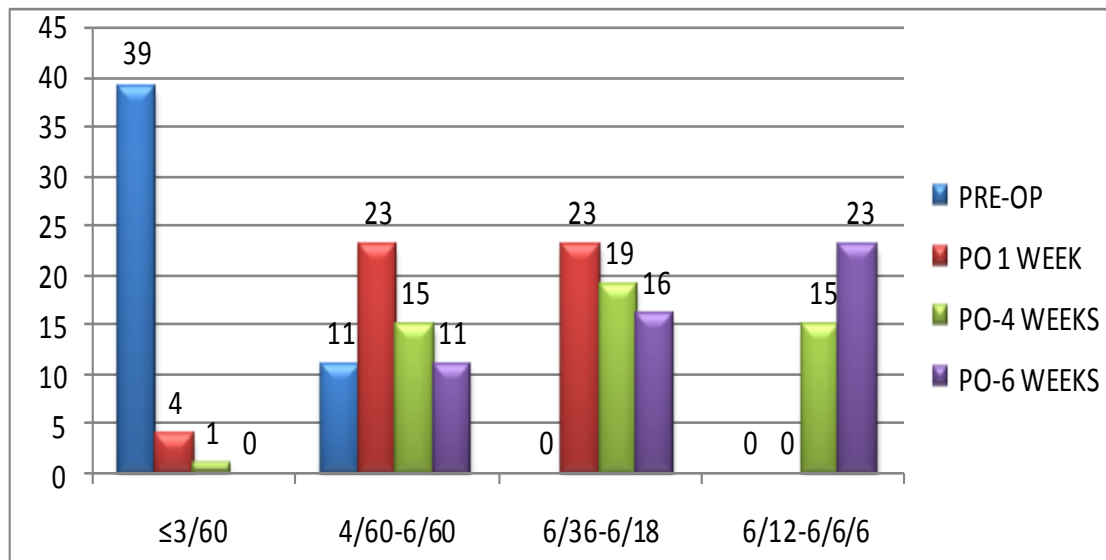
SFIOL implantation and postoperative complications like striate keratopathy, iritis, corneal decompensation(<500 cells),IOL malposition, cystoid macular edema(OCT thickness>250µ),retinal detachment, rise of IOP, endophthalmitis<sup>8</sup> were studied.

### V. Results

The mean age of presentation in our study was 61.54(SD-11.49 ) years. 58% of patients were between 45-65 yrs. In this study out of 50 patients, 32(64%) were males and 18(36%) were females. In this study both eyes were equally involved.70% of patients presented with post surgical aphakia, 12% with post traumatic subluxated lens, 6% with post traumatic cataract, 4% with post traumatic anterior dislocation of lens and 4% with spontaneous anterior dislocation or subluxation of lens in collagen vascular diseases,4% in spontaneous anterior dislocation or subluxation of lens in pseudoexfoliation . Preoperative visual acuity was measured in all patients. Out of these 50 patients 11(22%) patients had visual acuity of 6/60 to 4/60 and 39(78%) patients had visual acuity of ≤3/60. The most common slit lamp examination findings in preoperative evaluation was found to be iris pigment dispersion in 13(26%) patients, followed by uveitis in 6 patients(12%). Pre operative B Scan was normal in 43 patients & 7 patients had PVD .Preoperative fundus examination was normal in 47(94%) patients and 2 (4%) patients had hypertensive changes .Fundus could not be visualised in one of the patient due to corneal opacity. Specular microscopic examination was done for all patients. Mean endothelial count for pre-op and post-op patients was 2021(SD± 297) and 1647.04(SD±378.01) respectively.

The most common factors were chronic uveitis(38%) followed by spontaneous dislocation/subluxation of lens(8%) and hypertension(8%).The most common type of surgery in post surgical aphakics were SICS(58%) followed by ECCE (6%),phacoemulsification(2%) and PPV with lens removal (9%).Total number of patients presenting with history of trauma were 13(26%) and among them 10(77%) had blunt trauma and 3(23%) had sharp injury. Duration of trauma or cataract surgery and SFIOL implantation varied between minimum of 1 month to maximum of 25 years. But most the patients presented within 2 to 6 months duration. In this study 60% of patients were operated within 60 minutes and 10 were operated for more than 90 minutes. During post operative period, 24(48%) patients did not develop any complications. Post operative iritis in 16(32%) patients was the most common complication noticed during the post operative period in our study, followed by striate keratopathy and vitritis in 8(16%) and 06(12%) patients respectively. There was no post operative endophthalmitis, retinal detachment, IOL malposition and transient rise of IOP in any of the patients included in our study. The postoperative B scan findings were normal in 39(78%) patients and 7 patients had PVD and 4 patients had vitritis.

**Chart No 1: Comparison of visual acuity in pre-op and post-op period**



The success rate of our study was 62%.The refraction was more towards myopic side (0 to -2.5DS). In our study secondary IOL implantation was associated with significant visual outcome compared to primary SFIOL implantation with **p value of 0.031** which is statistically significant.

**Table No.1: MUTIVARIATE ANALYSIS OF PRE-OP FACTORS ANALYSED FOR IMPROVEMENT ( $\geq 6/18$ ) & DECREASE IN VISUAL OUTCOME ( $< 6/18$ )**

S.NO	PRE-OP FACTORS	NO. OF PATIENTS	p VALUE IMPROVED VISUAL OUTCOME	SIGNIFICANCE ( $< 0.05$ )	P VALUE FOR DECREASED VISUAL OUTCOME	SIGNIFICANCE ( $< 0.05$ )
1	No pre op factors	19	<b>0.001</b>	<b>Significant</b>	0.986	Not significant
2	Chronic uveitis	03	0.117	Not significant	<b>0.001</b>	<b>Significant</b>
3	Spontaneous dislocation of lens	04	0.275	Not significant	0.577	Not significant
4	Traumatic dislocation of lens	02	0.687	Not significant	0.721	Not significant
5	Diabetes	03	0.393	Not significant	0.864	Not significant
6	Hypertension	04	0.182	Not significant	0.975	Not significant
7	Type of cataract surgery	35	0.073	Not significant	0.330	Not significant
8	history of injury	13	0.057	Not significant	<b>0.003</b>	<b>Significant</b>
9	Duration of trauma/cataract surgery and SFIOL implantation $< 4$ months	30	0.436	Not significant	0.187	Not significant

Above table shows the mutivariate regression analysis of pre-operative factors for significant improvement in vision ( $\geq 6/18$ ). Visual outcome was significantly improved  $\geq 6/18$  in patients those who did not have any of the pre-op factors (**p value of 0.001**). Presence of chronic uveitis and history of injury to the eye were significantly associated with poor visual outcome with **p value of 0.001 ( $< 0.05$ )** and **0.003 ( $< 0.05$ )** respectively after 6 weeks of SFIOL implantation. Other factors like DM, hypertension, type of cataract surgery, traumatic or spontaneous dislocation of lens and duration between trauma / cataract surgery and SFIOL implantation were not significantly associated with poor visual outcome.

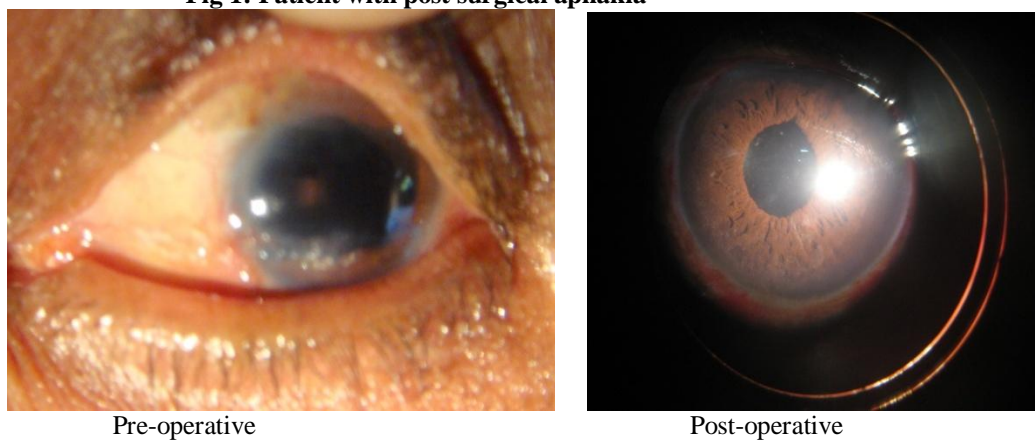
**Table No. 2: MUTIVARIATE ANALYSIS OF POST-OP FACTORS ANALYSED FOR IMPROVEMENT ( $\geq 6/18$ ) & DECREASE IN VISUAL OUTCOME ( $< 6/18$ )**

S.NO	Post-Op Factors	No Of Patients	p Value improved visual Outcome	Significance ( $< 0.05$ )	p value For Decrease In Visual Outcome	Significance ( $< 0.05$ )
1	No post –op complications	24	<b>0.001</b>	<b>Significant</b>	0.120	Not significant
2	Striate keratopathy	08	0.518	Not significant	<b>0.049</b>	<b>Significant</b>
3	Iritis	16	0.187	Not significant	<b>0.001</b>	<b>Significant</b>
4	CME	02	0.999	Not significant	0.065	Not significant
5	Suture irritation	01	1.000	Not significant	0.429	Not significant
6	Transient IOP rise	01	1.000	Not significant	0.197	Not significant
7	Vitritis	06	0.300	Not significant	0.519	Not significant
8	Pseudo phacodonesis	02	1.000	Not significant	0.258	Not significant

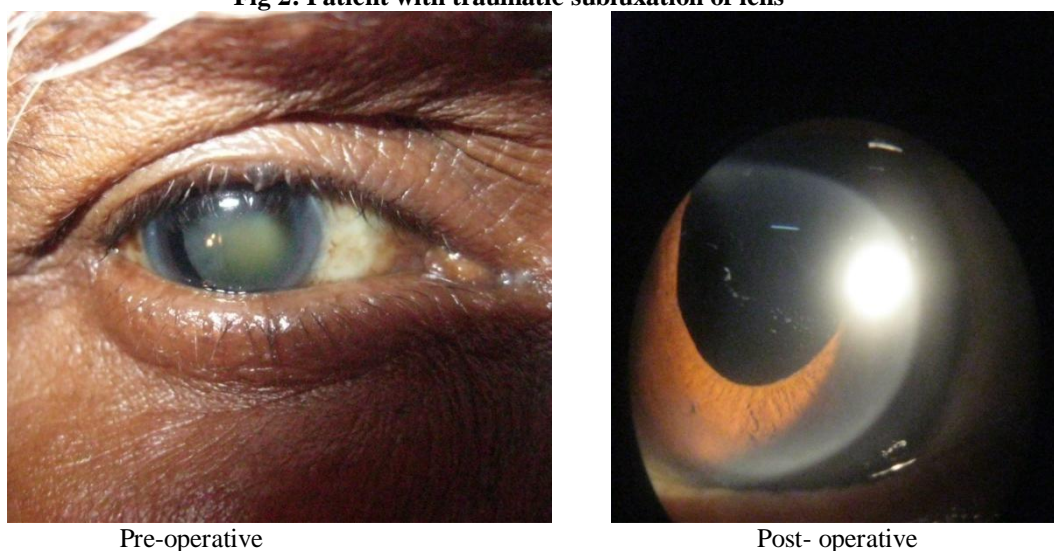
In patients with no post op complications there was significant visual improvement after 6 weeks of SFIOL implantation. Presence of other post-op factors were not significantly associated with improvement in visual outcome in this study. In intra-op factors prolonged duration of surgery  $> 60$  min (p value 0.010) was associated with poor visual outcome in this study. Presence of post complications like striate keratopathy and iritis were significantly associated with poor visual outcome ( $< 6/18$ ) with p value of 0.049(0.05) and 0.001(0.05) respectively. All other factors like corneal decompensation, IOL malposition, suture irritation,

transient rise of IOP, vitritis and pseudo phacodonesis were not significantly associated with poor visual outcome in this study.

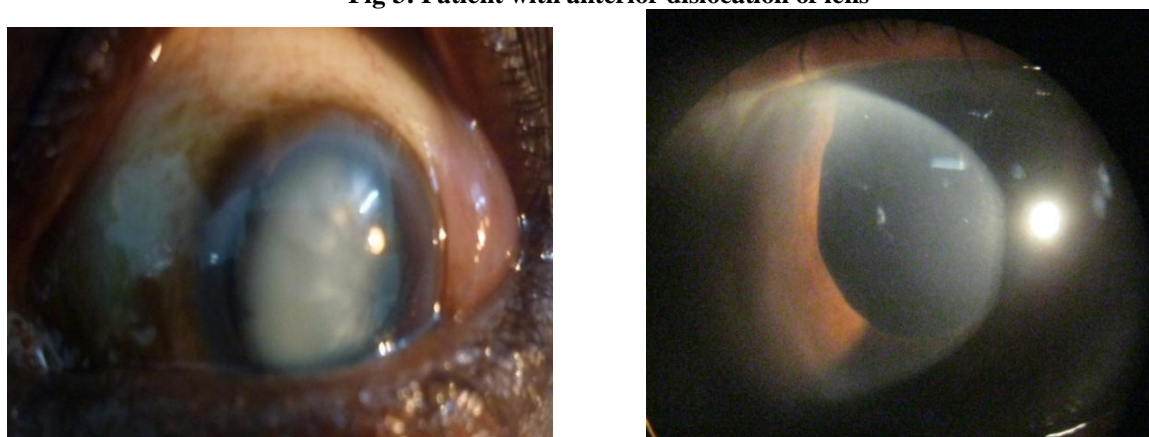
**Fig 1: Patient with post surgical aphakia**



**Fig 2: Patient with traumatic subluxation of lens**



**Fig 3: Patient with anterior dislocation of lens**



## **VI. Discussion**

SFIOL is a safe and effective option for visual rehabilitation of patients with inadequate capsular support following cataract surgery, subluxation or anterior dislocation of lens following trauma, collagen vascular diseases or pseudoexfoliation.

50 eyes of 50 patients were selected for scleral fixated intraocular lens implantation. The mean age of the patients was 61.54 years(25-80). In Kwong et al<sup>6</sup> study the mean age of the patients was 76.7 years( 57-98).This can be attributed to the fact that in Japan there are more number of elderly people compared to India. In our study there were 32 males and 18 females. This can be possibly explained by the fact that males are at higher risk of occupational injury and being the earning member of the family they report earlier for visual rehabilitation.

Regarding laterality both the eyes were almost equally affected (26-right eyes, 24 left eyes).The mean follow-up period in our study was 12 months. In Lee et al<sup>7</sup> study the follow-up period was 19.2 months. The most common diagnosis at presentation was post surgical aphakia(70%) followed by post traumatic anterior subluxation of lens(12%).There were no studies which have included all the above inclusion criteria for SFIOL implantation.

The preoperative factors which were statistically significant in terms of post operative visual outcome were chronic uveitis (p value-0.001) and history of trauma/injury (p value -0.003). On literature search it is found that there are no articles to support the effect of pre-operative factors on visual outcome. The mean duration between trauma/cataract surgery and SFIOL implantation was 18.03 months( range 1month to 300 months). In Naresh K Yadav et al<sup>8</sup> study the mean interval was 9.6 months. In our study though majority of our patients (60%) presented within 4 months, 3 patients presented years after cataract surgery.

In post surgical aphakia group the majority of patients(58%) had undergone SICS. In Lee et al<sup>7</sup> study the majority of patients(68%) had undergone ECCE, as the study was done in 1997 when ECCE was more commonly practised. In the trauma group blunt injury was the most common mode of injury in our study. In our study 15 patients (30%) had undergone primary SFIOL implantation and 35(70%) had undergone secondary SFIOL implantation. All the post surgical aphakia patients had undergone secondary procedure and all the traumatic patients had undergone primary procedure. In Lee et al study<sup>7</sup> there were 30(54.5%) in the primary group and 25(45.5%) in secondary SFIOL group. In majority of the patients(78%) the pre-operative visual acuity was  $\leq 3/60$  and between 4/60 and 6/60 in 22% of cases. The mean duration of SFIOL implantation was 56.80 min (SD $\pm$ 27.23 min) and the increased duration of surgery was statistically significant (0.001) in terms of poor visual outcome after SFIOL implantation in our study. In Kwong et al<sup>6</sup> study the mean duration was 65min (SD $\pm$ 24.12 min).

The post operative period was uneventful in 48% of the patients . The most common post -operative complications were iritis (32%) and followed by striate keratopathy (16%) and vitritis(12%) . Among these iritis (p value 0.001) and striate keratopathy(p value 0.049) were statistically significant in terms of poor visual outcome. The other complications were cystoid macular edema(4%), IOL decentration(4%), corneal decompensation(2%) and suture irritation(2%). In Lee et al study<sup>7</sup> corneal edema was the only statistically significant (p value 0.027) post operative complication affecting the visual outcome. The other complications were increased IOP (36.6%), hyphaema(26.6), vitreous haemorrhage(26.6%), pupil deformation (56.7%), cystoid macular edema (6.7%), IOL decentration(3.3%) and corneal decompensation(3.3%).The mean pre-op endothelial count was 2021(SD $\pm$ 297.0) and the mean post-operative endothelial count was 1647.04(SD $\pm$ 378.01). In Dadeya S et al<sup>9</sup> study the mean post-operative endothelial count was 1723 $\pm$ 363.

The post operative visual acuity at 1 week was between 6/18-6/36 in 46% of cases,6/60 -4/60 in 46% of cases  $\leq 3/60$  in 8% of cases. At 6 weeks majority (46%) had 6/6- 6/12 visual acuity and the remaining had visual acuity between 6/18-6/36 in 32% of cases and 6/60 - 4/60 in 22% cases. The improvement in visual acuity at 6 weeks is due to the treatment of complications. The success of surgery was defined as visual acuity  $\geq 6/18$ . In our study 62% of patients have visual acuity of  $\geq 6/18$ . In the primary SFIOL group the success rate was 40% and 71% in the secondary SFIOL group. So from our study it is found that the visual acuity in the secondary group is statistically significant(p value 0.031). In Sanjeev kumar et al<sup>10</sup> study, the success rate was ( $\geq 6/18$ ) 100% in secondary implantation and 83.33% in primary implantation. This could be explained by small sample size in this study(10 patients). In Lee et al study<sup>7</sup> the success rate was 56.6% in primary and 76% in secondary group. This can be attributed to the fact that there is increased risk of post-operative inflammation in primary group as compared to presumably healthier group of eyes preselected in the secondary group.

Furthermore, the skilled and meticulous surgical technique may not be ideally performed under stressful situation associated with posterior capsular rupture. Post operative refraction was between -2.5 to 0 in 74% of patients in our study. In a study by Donaldson et al<sup>11</sup> the refraction was -1.32 & +2.12 DS and was more towards myopic side for SFIOL.

## **VII. Conclusion**

In our study, males were predominantly affected. The age group 45-75 years formed the core group to get operated. Majority of the patients presented with post surgical aphakia.

The statistically significant factors associated with poor visual outcome were preoperative factors like chronic uveitis and trauma, intraoperative factors like prolonged duration of surgery and post-operative complications like iritis and striate keratopathy.

Results in this study revealed that the visual outcome following the secondary SFIOL implantation is better than primary SFIOL implantation which can be attributed to the increased rate of inflammation in the primary procedure. The success rate of the surgery was 62% .The post operative refraction is mostly towards myopic side in this study.

The final visual outcome depends on the preoperative, intraoperative and postoperative factors. So emphasis must be laid on thorough preoperative evaluation of the patient, meticulous surgical technique and treatment of the postoperative complications.

### References

- [1]. Snell RS,Lemp M.A : Clinical anatomy of the Eye,Second edition,1989; 119-194.
- [2]. American Academy of Ophthalmology - Lens and cataract 2011 - 2102;142-156.
- [3]. Jack J Kanski, Clinical Ophthalmology, Seventh Edition;269-311.
- [4]. Albert Jacobiec's Principles and Practice of Ophthalmology, III Edition, vol 1 ; 1291 -1527.
- [5]. Drews R.C. The Barraquer experience with intraocular lenses,1982; 89:386-393.
- [6]. Kwong YY, Yuen HK, Lam RF, Lee VY, Rao SK, Ophthalmology 2007 Jan;114(1):80-85.
- [7]. Lee VY, Yuen HK, Kwok AK. Comparison of outcomes of primary and secondary implantation of scleral fixated posterior chamber intraocular lens. Br J Ophthalmol 2003;87:1459–62.
- [8]. Naresh K Yadav,A truly knotless technique for SFIOL implantation :two year results, Indian J Ophthal 2012;60:147-148.
- [9]. Dadeya S, Kamlesh, Kumari Sodhi P. Anterior chamber versus scleral fixation long-term comparative evaluation. Eur J Ophthalmol 2003;13:627–33.
- [10]. Dr.Sanjeev Kumar, Dr.C.Shiv Kumar, Dr.Ramkrishnan,Dr Sandeep Bochu,AIOC 2010,105-107.
- [11]. Donaldson KE, Gorscak JJ, Budenz DL, et al. Anterior chamber and sutured posterior chamber intraocular lenses in eyes with poor capsular support. J Cataract Refract Surg 2005;31:903–9.

Dr Anandalakshmi R, et. al. "A Multivariate Analysis of the Factors Affecting the Visual Outcome and Complications Following Scleral Fixated Intraocular Lens Implantation." *IOSR Journal of Dental and Medical Sciences (IOSR-JDMS)*, 20(07), 2021, pp. 14-20.