

Prosthodontic Management of Edentulous Patients with Different Types of Residual Ridge Resorption

Natasha Stavreva^{1*}

¹Department of Prosthodontics, Faculty of Dentistry Skopje, "Ss. Cyril and Methodius" University in Skopje, Macedonia

*Corresponding author: Natasha Stavreva

Abstract

Residual ridge resorption is a complex biophysical process and a common occurrence following extraction of teeth. It is the most dramatic during the first year after tooth loss followed by a slower but more progressive rate of resorption thereafter. Bone resorption also is a chronic, progressive and irreversible process that occurs in all patients. Residual ridge reduction is one of the main causes of loss of denture stability and retention especially in mandibular complete dentures. Extreme resorption of the maxillary and mandibular ridges also, results in sunken appearance of cheeks, unstable and non-retentive dentures with associated pain and discomfort. Therefore, poses a clinical challenge towards the fabrication of a successful removable prosthesis. There are some of etiological factors that may cause resorbed ridge such as anatomical, prosthodontics, metabolic and systemic factors. The present article highlights the surgical and non-surgical interventions followed by prosthodontic management of different types of residual ridge resorption.

Key words: edentulous, residual ridge resorption, prosthodontic management

Date of Submission: 28-07-2021

Date of Acceptance: 12-08-2021

I. Introduction

Residual ridge resorption is a complex biophysical process and a common occurrence following extraction of teeth. It is the most dramatic during the first year after tooth loss followed by a slower but more progressive rate of resorption thereafter. Bone resorption also is a chronic, progressive and irreversible process that occurs in all patients. [1]

The success of the complete denture relies on the fulfillment of the three basic properties which are retention, stability, and support. Mandibular dentures usually faced more difficulties in achieving these three properties than maxillary dentures, [2] because, the mandible ridge has a lesser residual ridge for retention and support [3] and has greater resorption rate than the maxilla. According to some studies by Atwood and Tallgren show that mandibular bone resorption is four times greater than in the maxilla. [4,5]

Residual ridge reduction is one of the main causes of loss of denture stability and retention especially in mandibular complete dentures. Extreme resorption of the maxillary and mandibular ridges also, results in sunken appearance of cheeks, unstable and non-retentive dentures with associated pain and discomfort. Therefore, poses a clinical challenge towards the fabrication of a successful removable prosthesis. [6]

A classification of the edentulous jaws has been developed based on a randomised cross-sectional study from by Cawood et al, 1988, Arising from these morphological studies of edentulous jaws they found that the basal bone does not change shape significantly, unless subjected to harmful local effects such as the overloading of ill-fitting dentures. Moreover the alveolar bone changes shape significantly in both the horizontal and vertical axes following a predictable pattern. [7] Cawood and Hawell classify the residual ridge to basic six classes:

Class I - dentate.

Class II -immediately post extraction.

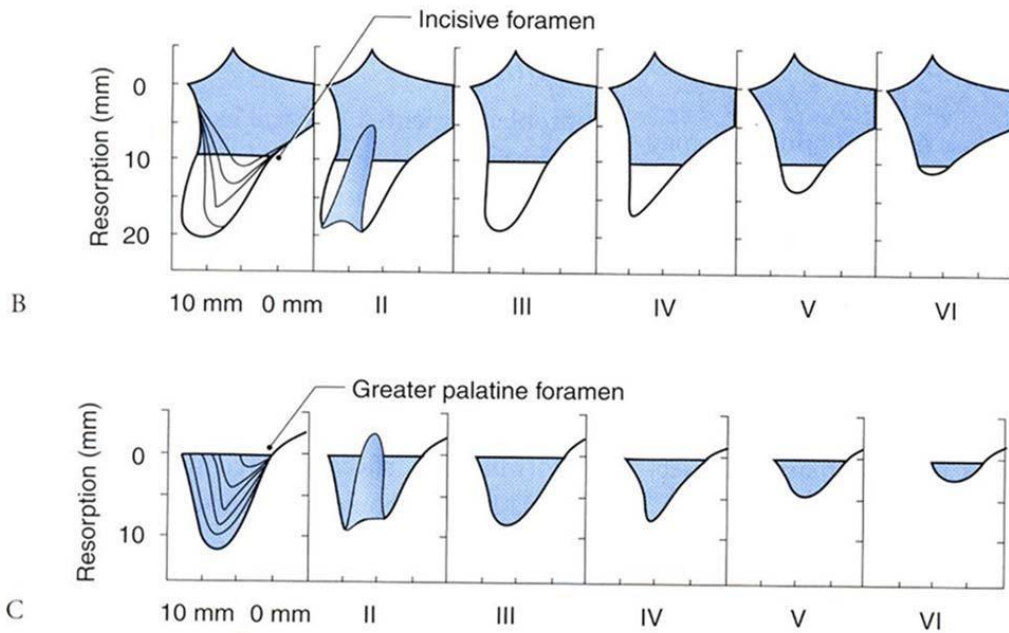
Class III- well-rounded ridge form, adequate in height and width.

Class IV - knife-edge ridge form, adequate in height and inadequate in width.

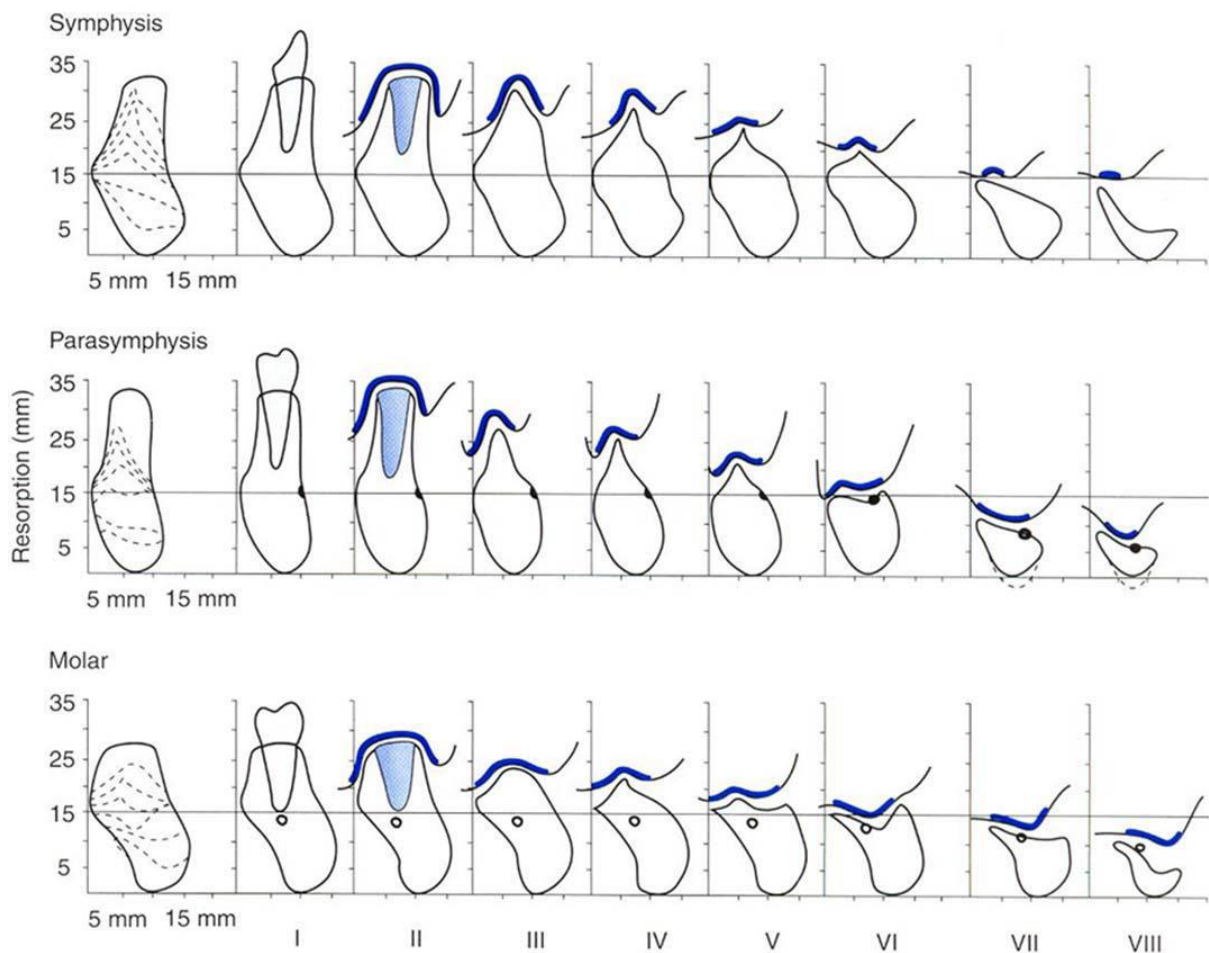
Class V flat ridge form, inadequate in height and width.

Class VI - depressed ridge form, with some basilar loss evident.

Moreover they found that the Pattern of bone loss varies with sites. Anterior mandible - bone loss is vertical and horizontal (from the labial aspect). Posterior mandible - bone loss is mainly vertical. Anterior maxilla - bone loss is both vertical and horizontal (from the labial aspect). Posterior maxilla - bone loss is both vertical and horizontal (from the buccal aspect). [4]



Maxillary horizontal measurements (A). Classification of resorption of maxillary alveolar ridge: anterior (B) and posterior (C). Adapted from Cawood JI, Howell RA.⁷



Modified Cawood and Howell classification of resorption. The thicker line illustrates the amount of attached mucosa, which decreases with progressive resorption. Adapted from Cawood JI, Howell RA.⁷

ETIOLOGICAL FACTORS

The anatomical factor: The shape and size of the alveolar ridge has great effect as the well-formed broad ridges show less resorption than narrow thin ridge as the force received per unit area will be less in the former. Moreover the types of the bone show great effect on the rate of bone resorption. [8]

Metabolic and systemic factors: has great effect on the rate of bone resorption which include Age, race, present of systematic illnesses such as osteoporosis, nutritional status especially calcium and vitamin D, and the amount of time the patient has been edentulous. [9]

Bone resorption rate: They are much higher In postmenopausal older women, due to inadequate of formation of new bone tissue are associated with estrogen deficiency. [10] Although in those cases the rate of bone resorption can be control by treat the causes by drugs that increase bone mineral density as Bisphosphonates, RANKL inhibitors, SERMs-selective, estrogen receptor modulators, hormone replacement therapy and calcitonin. [11] Moreover the light weight bearing exercise tends to eliminate the negative effects of bone resorption. [12]

Periodontal disease: It refers to the inflammatory processes that occur in the tissues surrounding the teeth in response to bacterial accumulations, or dental plaque, on the teeth. The bacterial accumulations cause an inflammatory response from the body. The chronic and progressive bacterial infection of the gums leads to alveolar bone destruction and loss of tissue attachment to the teeth. [13]

Prosthodontic: The remodeling of bone is influenced by the force that applied on it which may result of habits factor like parafunctions habit such bruxism and misuse of prosthesis such as Intensive denture wearing, unstable occlusal conditions, Immediate denture treatment and use of improper designed denture. [9]

PROSTHODONTIC MANAGEMENT OF RESIDUAL RIDGE RESORPTION

The prosthodontic management of patient with severe residual ridge resorption can be either with or without surgical intervention.

I – Prosthesis with surgical intervention

- **Implant supported surgical procedure** is a reliable protocol in the management of complete edentulism obtaining maximum retention and stability.
- **Distraction osteogenesis (DO)** is a method of generating new bone following a corticotomy or an osteotomy and gradual distraction. The method is based on the tension-stress principle proposed by Ilizarov. [14] The gradual bone distraction creates mechanical stimulation which induces biological responses and consequently bone regeneration. This is accomplished by a cascade of biological processes which may include differentiation of pluripotential cells, angiogenesis, osteogenesis, and bone mineralization. [15]
- **Bone grafting surgical procedure** is a surgical procedure that replaces missing bone with material from patient's own body, an artificial, synthetic, or natural substitute. Bone grafting is possible because bone tissue has the ability to regenerate completely if provided the space into which it has to grow. As natural bone grows, it generally replaces the graft material completely, resulting in a fully integrated region of new bone.

II – Prosthesis without surgical intervention

As the residual ridges resorb, the tissues become unsupported and displaceable. So it's need to modify a When use of conventional impression techniques will result in a distorted impression. Therefore, the impression technique needs to be modified.

- **Window technique.** Zafarulla Khan described a technique where a window was cut in the custom tray where the unsupported area was present. A preliminary impression is taken using alginate loaded in a stock tray. The impression is then poured and a customized tray is constructed on the model. The customized tray is close fitting and has a hole or "window" over the area corresponding to the flabby ridge. An impression is taken in zinc oxide eugenol or low viscosity silicone (mucodisplacive in a close-fitting tray). Once this has set, it is left in place and low or medium viscosity silicone (mucostatic) is injected over the flabby ridge and allowed to set and removed as one impression. The impression is removed as one, cast and the denture constructed on the resulting mode.
- **Controlled lateral pressure technique.** This technique was advocated by many authors for use with a fibrous (unemployed) posterior mandibular ridge. [16-18] They describe a technique in which tracing compound (green stick) is used to record the denture bearing area using a correctly extended special tray. A heated instrument is then used to remove the green stick related to the fibrous crestal tissues and the tray is perforated in this region. Light bodied silicone impression material is then syringed onto the buccal and lingual aspects of the greenstick and the impression gently inserted. The excess material is extruded through the perforations and theoretically the fibrous ridge will assume a resting central position having been subjected to even lateral pressures.

- **Selective perforation tray.** It has been suggested that if the degree of mucosal displacement is minimal, then this modified conventional technique may be considered. [19] Preliminary impressions are taken in stock trays using low-viscosity alginate after appropriate border correction. A spaced special tray is fabricated from the primary cast for use with a low viscosity impression material, such as impression plaster, low-viscosity silicone or alginate. Pressures on the unsupported, displaceable soft tissue can be minimized further by the use of perforations in the tray overlying these areas.
- **Palatal splinting using a two-party tray system.** In 1964 Osborne described an impression technique involving two overlying impression trays used for recording maxillary arches with displaceable anterior ridges. [20] The aim of this technique is to maintain the contour of the easy displaceable tissue while the rest of the denture bearing area is recorded. A primary model is constructed using the fitting surface contour of a previous denture. From this a palatal tray is fabricated with wax being used to create space on the palatal aspect of the mobile area and extending to the ridge crest around the arch. In this acrylic resin palatal tray, a low viscosity zinc oxide paste impression is taken of the palate. An upward force is maintained until it is apparent that the mobile ridge is just beginning to have pressure applied to it. Once this has set, a second special tray impression is made completely encompassing the first tray. It should be inserted from in front, backwards, and the presence of the supporting zinc oxide should prevent backwards displacement of the mobile ridge. A neat modification of this approach was described by Devlin in 1985, in which a locating rod is positioned in the center of the palatal tray, but proclined to allow the second special tray impression to be guided in an oblique upward and backward direction to an envelope the palatal tray. The palatal tray accurately locates the second part special tray using a stop, thereby allowing for a pre-planned even thickness of impression material.
- **Flaming technique.** This technique aims to displace but not distort the flabby ridge as if in function. A preliminary impression is taken in a mucostatic impression material (eg. Impression plaster or alginate) and cast in stone. A spaced customized tray for an impression compound impression is then constructed on this model. The tray is loaded with impression compound and an impression taken of the preliminary model of the patient's mouth. This reduces the risk of displacing the flabby ridge. The impression is tried in the mouth and should be quite retentive. The impression is removed and warmed all over except for the flabby ridge area. The impression is retaken in the mouth, the flabby ridge is compressed but not distorted as the other portions of the impression compound (which are warm) sink into the tissues. The impression is removed inspected and re-tried in the mouth to check that it is stable. If any instability occurs then the impression should be reheated and re-taken. A wash impression may be taken in impression paste over the impression compound to obtain maximum details.

II. Conclusion

Flabby ridges pose a prosthodontic challenge for the achievement of stable and retentive dental prostheses. When considering conventional prosthodontics, there a variety of options, surgical and non-surgical, completed with prosthodontic restorations, available to address the problems caused by the unsupported tissue during denture construction. The main aim is always a satisfied patient and dentist.

References

- [1]. Carlsson GE. Clinical Morbidity and Sequelae of Treatment with Complete Dentures. *J Prosthet Dent.* 1998; 79: 17-23.
- [2]. Yadav B , Jayna M, Yada H, Suri S , Phogat S , Madan R. Comparison of Different Final Impression Techniques for Management of Resorbed Mandibular Ridge: *Case Reports in Dentistry*, 2014;214: 6 : 25373.
- [3]. Tinker A. Ageing in the United Kingdom-what does this mean for dentistry? *Br Dent J.* 2003; 194:369-372.
- [4]. Atwood DA, Coy WA. Clinical Cephalometric and Densitometric Study of Reduction of Residual Ridges. *J Prosthet Dent.* 1971;26: 280-95.
- [5]. Tallgren A. The Continuing Reduction of the Residual Alveolar Ridges in Complete Denture Wearers: A Mixed-Longitudinal Study Covering 25 years. *J Prosthet Dent.* 1972; 27: 120-32.
- [6]. Krishna P, Mehra D, Prasad A. Prosthodontic Management Of Compromised Ridges and Situations. *INDIA, NUJHS*, 2014; 4: 2249-7110
- [7]. J. L Cawood and R. A. Howell." A classification of the edentulous jaws. *Int. J. Oral Maxillofac. Surg.* 1988; 17:232-236
- [8]. Atwood D.A., 1971. "Reduction of residual ridges : A major oral disease entity". *J. Prosthet. Dent.*, 26 : 266-279
- [9]. Carlsson GE. Responses of Jaw Bone to Pressure. *Gerodontology.* 2004;21:65-70.
- [10]. Feng X McDonald, Jay M. Disorders of Bone Remodeling". *Annual Review of Pathology.* 2011; 01:1553-4006.
- [11]. Russell G, Mueller G, Shipman C, Croucher P. "Clinical Disorders of Bone Resorption"*N. ovartis Foundation Symposium.* 2001;232: 251-267;
- [12]. Shanb AA, Youssef EF. The impact of adding weight-bearing exercise versus nonweight bearing programs to the medical treatment of elderly patients with osteoporosi . *Journal of Family and Community Medicine.* 2014;21 (3): 176-181.
- [13]. Kirby A C, Meghji S, Nair S P, White P, Reddi K, Nishihara T, Nakashimi K, Willis A C, Sim R, Wilson M, Henderson B. The potent bone-resorbing mediator of *Actinobacillus actinomycetemcomitans* is homologous to the molecular chaperone GroEL. *J Clin Invest.* 1995; 96:1185-1194.
- [14]. Ilizarov GA. The tension-stress effect on the genesis and growth of tissues. Part I. The influence of stability of fixation and soft-tissue preservation. *Clin Orthop Relat Res.* 1989;238:249-81.
- [15]. Derek D'Souza ProsthodonticsIndia Residual Ridge Resorption – Revisited Prosthodontic rehabilitation of resorbed ridges - Conventional complete dentures
- [16]. Mc Cord JF, Grant AA. A clinical guide to complete denture prosthodontics. Quintessence, London, 1993: 57-60

- [17]. Grant AA, Heath JR, McCord JF. Complete prosthodontics: problems, diagnosis and management. Wolfe, London, 1994: 90-92
- [18]. Allen PF, McCarthy S. Complete dentures: from planning to problem solving. Quintessence, London, 2003: 48-51
- [19]. Lamb DJ. Problems and solutions in complete denture prosthodontics. Quintessence, London, 1993: 57-60
- [20]. Osborne J. Two impression methods for mobile fibrous ridges. Br. Dent J 1964; 117: 392-394

Natasha Stavreva. "Prosthodontic Management of Edentulous Patients with Different Types of Residual Ridge Resorption." *IOSR Journal of Dental and Medical Sciences (IOSR-JDMS)*, 20(08), 2021, pp. 33-37.