

Acute Uncomplicated Appendicitis At The Brazzaville University Hospital: Epidemiological, Diagnostic, Therapeutic And Prognostic Aspects.

Elion Ossibi Pierlesky^{1,2}, BhodehoMedi Monwongui¹,
Note Madzele Murielle Etiennette Julie^{1,2}, MotoulaLatouNoé Henschel^{1,2},
Service Yanguedet Moïse¹, AlimaKoyaCédric Du Bonheur¹,
Avala Prude Pertinie¹, TsouassaWaNgonoGiresse Bienvenu¹,
NzakaMoukala Carmich¹, MassambaMiabaou Didace^{1,2}.

¹: Digestive Surgery Department, Brazzaville University Hospital

²: Faculty of Health Sciences, Marien N'GOUABI University

Abstract

Objective: To study the epidemiological, diagnostic, therapeutic and prognostic aspects of patients treated for acute uncomplicated appendicitis at the University Hospital of Brazzaville.

Patients and Methods: This was a descriptive study with retrospective data collection from January 2019 to December 2022 at the digestive surgery department of the Brazzaville University Hospital. Adult patients treated for acute uncomplicated appendicitis were included. Our parameters of interest were epidemiological, diagnostic, therapeutic and evolutionary.

Results: During the study period, 231 cases of acute uncomplicated appendicitis were treated, representing a hospital incidence of 5.93% and 21.15% of abdominal emergencies. The mean age of the patients was 38 ± 13.69 years, with extremes ranging from 17 to 79 years. The most common age group was 17 to 27 years. Females predominated (53%). All patients presented with right iliac fossa pain associated with fever (79.66%) and vomiting and/or nausea (47%). The mean consultation time was 24.41 ± 11.80 hours, with extremes of 2 hours and 72 hours. 35% of patients had undergone abdominal ultrasound, which revealed acute uncomplicated appendicitis.

All patients underwent emergency surgery with a mean time to surgery of 4.66 ± 14.43 hours. Laparotomy using the Mac Burney approach was performed in 224 patients (96.97%) and laparoscopy in 7 patients (3.03%). The appendix was phlegmonous in the majority of cases. Postoperative management was uncomplicated in 96% of cases and complications were dominated by parietal suppuration.

Conclusion: Acute uncomplicated appendicitis remains rare in our context.

Keywords: Acute appendicitis, phlegmoneous, laparotomy, laparoscopy.

Date of Submission: 06-11-2023

Date of Acceptance: 16-11-2023

I. Introduction

Acute inflammation of the vermiform appendix, acute appendicitis is the most common abdominal emergency. It is a classic pathology in digestive surgery, occurring at any age, with a peak in frequency between the ages of 10 and 20 [2]. Diagnosis is essentially clinical. New imaging techniques (ultrasound and CT scans) have become the gold standard for diagnosing the disease [3]. The average annual incidence of appendectomy in France was 163/100,000 inhabitants in 2006 [1]. In North America and the UK, almost 400,000 appendectomies are performed each year [2].

In black Africa, according to studies, acute appendicitis accounted for 42.3% of abdominal emergencies [3] in the Central African Republic, 38.9% of surgical emergencies [4] in Niger and 40.54% in Mali [5].

In Congo Brazzaville, few studies have been carried out on this subject. In 2020, one study reported a frequency of 12.2% of atypical appendicitis [6].

The aim of this study was to examine the epidemiological, clinical and therapeutic aspects of acute uncomplicated appendicitis at Brazzaville University Hospital.

II. Patients and method

This was a descriptive study with retrospective data collection that took place in the digestive surgery department of the Brazzaville University Hospital.

It was spread over a 4-year period from 1 January 2019 to 31 December 2022. We included in this study all adult patients managed for acute uncomplicated appendicitis.

We did not include patients with incomplete records.

The variables studied were epidemiological, diagnostic, therapeutic and evolutionary.

Data were collected on a pre-established survey form and analysed using Excel 2016 software.

III. Results

Epidemiological aspects

During the study period, 3892 patients were admitted to the digestive surgery department, including 1093 cases of abdominal emergencies and 231 cases of acute uncomplicated appendicitis, representing a hospital frequency of 5.93% and 21.15% of all abdominal emergencies.

The mean age of the patients was 38 ± 13.69 years, with extremes ranging from 17 to 79 years. The median age was 30 years. The most common age group was 17 to 27 (Figure 1). Females predominated (53%), with a sex ratio of 0.89.

Unemployed patients and students accounted for 34.63% and 22.52% respectively [Table 1].

Diagnostic aspects

All patients consulted for pain in the right iliac fossa, associated with fever (79.66%) and vomiting and/or nausea (47%).

The average consultation time was 24.41 ± 11.80 hours, with extremes of 2 hours and 72 hours.

Patients with co-morbidities accounted for 43%: arterial hypertension and diabetes.

Physical examination revealed pain on palpation of the right iliac fossa in all patients. Blumberg's sign was present in 51% of cases.

Biologically, hyperleukocytosis was present in 41% of cases, with CRP elevated in the majority of patients.

An unprepared abdominal X-ray showed a stercolith in 31% of patients (Figure 2).

35% of patients had undergone abdominal ultrasound, which revealed acute uncomplicated appendicitis in 86% of cases (Figure 3).

Therapeutic aspects

All patients underwent emergency surgery. The mean time to surgery was 4.66 ± 14.43 hours, with extremes ranging from 2 hours to 36 hours.

The approach was laparotomy (224 patients or 96.97%) via a McBurney incision (figure 4) and laparoscopy (7 patients or 3.03%).

Intraoperatively, the appendix was in the right iliac position in the majority of cases. It was phlegmonous (Figure 5) in 76% of cases. Appendectomy (Figure 6) was performed in all patients.

Evolutionary aspects

The post-operative course was straightforward in 96% of cases. Complications were dominated by parietal suppuration.

The average hospital stay was 5.47 ± 10.05 days, with extremes ranging from 4 to 10 days.

IV. Discussion

Our frequency of 21.15% of all abdominal emergencies is lower than those of other authors in the Central African Republic [3], Niger [4] and Mali [5].

This difference may be explained by the fact that patients consulted late, at an advanced stage of the disease, presented to the emergency department with complications, in particular peritonitis (localised or generalised).

The mean age of patients (38 ± 13.69 years) in our study is higher than those of Sogoba G et al [5] and K. Keita et al [7] in Mali, who reported mean ages of 26.92 and 26.22 years respectively; it is similar to that of YONG JL in 2006 [8] in China, who reported a mean age of 34.3 years. Contrary to the data in the literature [9, 10, 11], the female sex was the most represented in our series. This may be explained by the delay in consultation and self-medication in males, who often come for consultation at the stage of complications. However, gender is not a risk factor for acute appendicitis.

All our patients had been seen for pain in the right iliac fossa. According to the literature, acute uncomplicated appendicitis is revealed by abdominal pain located preferentially in the right iliac fossa, as was the case in our study. It may begin in the epigastric or periumbilical region before moving secondarily to the

right iliac fossa [12, 13]. The diagnosis of acute uncomplicated appendicitis is essentially clinical [14, 15]. Physical examination will reveal pain or tenderness on palpation of the right iliac fossa, with Blumberg's sign and sometimes Rovsing's sign.

Biological tests help to guide the diagnosis. An emergency blood count may reveal an overall hyperleukocytosis of neutrophils.

Radiologically, ultrasound [16] is the first-line examination in cases of appendicular syndrome, to confirm the diagnosis or, if necessary, to investigate a differential diagnosis. In the case of appendicitis, there is :

- an increase in the size of the appendix, measured at more than 6mm in diameter; - lack of compressibility of the appendix ;
- a change in its contents: fluid retention, sometimes stercolith ;
- thickening and/or interruption of the wall, parietal dedifferentiation.

In women, it can be used to rule out gynaecological, urinary or intestinal diseases.

Sometimes the appendix is barely visible. When in doubt, an abdominal CT scan is the gold standard. In our series, ultrasound was requested in 35% of our patients. We did not request a CT scan in any of our patients.

Acute appendicitis is a surgical emergency, and treatment consists of removal of the vermiform appendix. This surgical treatment is often preceded by medical treatment [17].

The currently recommended approach is laparoscopy, which was performed in only 7 of our patients. This low frequency can be explained by the unavailability of laparoscopic equipment in emergencies. The majority of our patients were operated on using a Mac Burney approach, which is the preferred route and its minimally invasive nature argues in its favour [17].

Our data are identical to those in the literature, which in the majority of cases find an appendix in the right iliac or laterocacral position intraoperatively [5, 17]. The phlegmonous appendix was the most common, accounting for 76%. This higher rate than that of other authors [18,19] could be explained by the delay in consultation in our study, as several patients consulted 48 hours after the onset of symptoms.

Post-operative management was straightforward in the majority of cases in our study. Morbidity was 4%, dominated by parietal suppuration, which is consistent with the results of Farhouat P et al [17] and Villazon I D et al [20]. In the West, this rate is between 0.1 and 0.25% [21, 22].

The average hospital stay was 5.47 ± 10.05 days, in line with the literature [3, 23].

V. Conclusion

Acute uncomplicated appendicitis, which is a genuine surgical emergency, remains uncommon in our setting. Appendicitis is most common in young adult women. The most common anatomopathological form is phlegmonous appendicitis. Treatment consists of appendectomy, the majority of which is performed using a Mac Burney approach, although laparoscopy remains the preferred approach. Efforts must be made to standardise this approach.

Conflicts of interest: The authors declare that they have no conflicts of interest.

Authors' contributions: All the authors have contributed to this article and have read and approved the final version of this manuscript.

References

- [1]. Crombe A. Abdomino-Pelvic Ultrasound In Suspected Acute Appendicitis: Prospective Evaluation In Adults. *Ann Chir*2000; 125: 57-61.
- [2]. AmeerFarooq, François Roule Au Fournier, Carl Brown. Treatment Of Appendicitis With Antibiotics Alone *CMAJ* 2021; 193(32): 1277 – 1278
- [3]. Zoguéréh DD, Xavier Lemaitre. Acute Appendicitis At The National Center University Hospital Of Bangui, Central African Republic: Epidemiological, Clinical, Para-Clinical And Therapeutic Aspects 2001; 11(5): 117-25.
- [4]. Harouna YD, Amadou S, Gazi M, Gamatie Y, Abdou I, Omar GS Et Al. Appendicitis In Niger: Current Prognosis. *Bull Soc Pathol Exot* 2000; 93(5): 314-16.
- [5]. Sogoba G, Katilé D, Traoré LI, Sangaré S, Kanté D, Cissé SM, Sangaré D3. Clinical Presentation And Management Of Acute Appendicitis At Hôpital Fousseyni Daou (Kayes). *HealthSci. Dis: 2021* ; 22 (7) : 102-106
- [6]. M Service Yanguedet GB Tsouassa Wa Ngono, DS Nzoulouto Et Al. Atypical Adult Appendicitis At Brazzaville University Hospital *Jaccr Africa* 2020; 4(4): 9-17
- [7]. K. Keita, A. Diarra, S. Keita, O. Coulibally, A. Koné, S. Coulibaly Et Al. Acute Appendicitis At The BSS Kati University Hospital: Experience Of The Service In 120 Cases (Mali). *Jaccr Africa* 2021 ; 5(1) : 157 – 162.
- [8]. JAMY L YONG, WAILUNDROIT, CHUNG Yau Lo, CHI Ming Lam. Comparative Study Of Routine Laparoscopic Versus Open Appendectomy. *JLS* 2006; 10(2): 188-192.
- [9]. Abbasi N, Patenaude V, Abenhaim HA. Management And Outcomes Of Acute Appendicitis In Pregnancy-Population- Based Study Of Over 7000 Cases. *BJOG* 2014 ; 12: 1509 - 1514
- [10]. Lefrancois M, Lefevre JH, Chafai N, Et Al. Management Of Acute Appendicitis In Ambulatory Surgery: Is It Possible? How To Select Patients ? *Ann Surg* 2015 ; 26: 1167-1172

[11]. Findlay JM, Kafsi JE, Hammer C, Gilmour J, Gillies RS, Maynard ND. Nonoperative Management Of Appendicitis In Adults: A Systematic Review And Meta-Analysis Of Randomized Controlled Trials. *J Am Coll Surg* 2016 ; 223

[12]. Andersson RE. Meta-Analysis Of The Clinical And Laboratory Diagnosis Of Appendicitis. *Br J Surg* 2004 ; 91:28-37.

[13]. CHAVDA SK, HASSAN S, MOGOHA GA. Appendicitis At Kenyatta National Hospital, Nairobi. *East Afr Med J.* 2005; 82(10): 526-530

[14]. Eriksson S, Granström L, Carlström A. The Diagnostic Value Of Repetitive Preoperative Analyses Of C-Reactive Protein And Total Leucocyte Count In Patients With Suspected Acute Appendicitis. *Scand J Gastroenterol* 1994;29:1145-1149.

[15]. Carr NJ. The Pathology Of Acute Appendicitis. *Ann Diagn Pathol* 2000; 4:46-58.

[16]. F. Bretagnol, M. Zappa, Y. Panis. Role Of Imaging In The Diagnosis Of Acute Appendicitis 2009 ; 146(5) : 8 – 11.

[17]. Farthouat P, Fall O, Oougemy M, Sow A, Million A, Dieng D, Diouf MB. Appendectomy In The Tropics: Prospective Study At Hospital Principal In DAKAR. *Med Trop* 2005; 65(6): 549-553.

[18]. Harouna YD, Amadou S, Gazi M, Gamatie Y, Abdou I, Omar GS Et Al. Appendicitis In Niger: Current Prognosis. *Bull Soc Pathol Exot* 2000 ; 93(5) : 314-16.

[19]. Munteanu R, Copaescu C, Litescu M, Turcu F, Iosifescu R, Timisescu L, Ginghina O, Dragomirescu. Laparoscopic Appendectomy- Considerations In About 1000 Cases. *Chirurgia (BUCUR)* 2005;100: 541-549.

[20]. Villazon D O, Espinosa Jaramillo A, Cardenas castaneda O, Valdes Castaneda A. Appendectomy By Minimally Invasive Surgery. *Rev Gastroenterol Mex* 2004;69:58-64

[21]. Lattre J. F. Acute Appendicitis And Its Complications Diagnosis, Treatment. *Impact Internat* 1997 ; 356.

[22]. Cacioppo J C. The Consequences Of Current Constraints On Surgical Treatment Of Appendicitis. *The Am J Of Surg* 1989;157:276-81.

[23]. Cothren CC, Moore EE, Johnson JL, Moore JB, Ciesia DJ, Burch JM. Can We Afford To Do Laparoscopic Appendectomy In An Academic Hospital?. *Am J Surg* 2005;190: 950-954.

List of figures

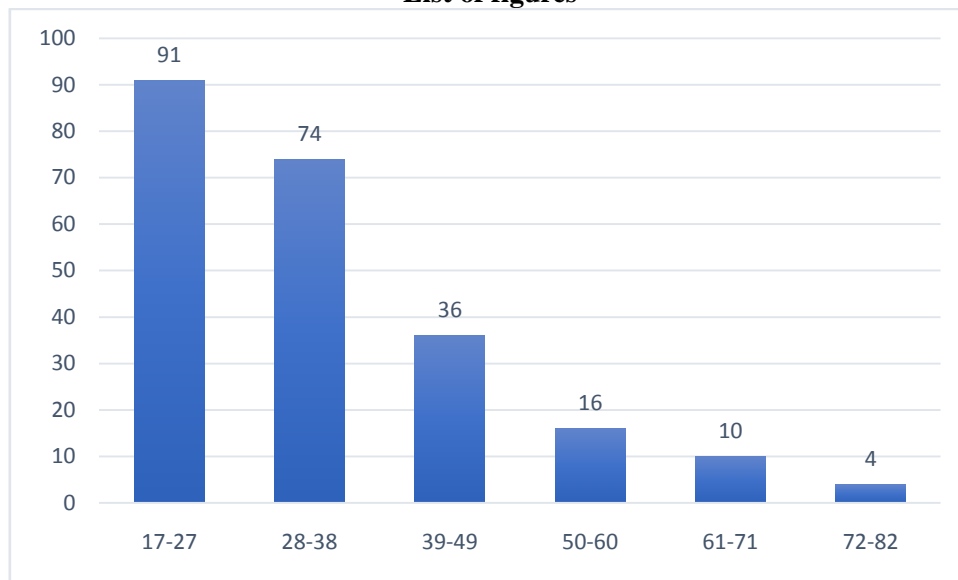


Figure 1: Breakdown of patients by age group

Table 1: Breakdown of patients by profession

Profession	Effectif	Pourcentage (%)
Sans emploi	80	34,63
Élève/étudiant	52	22,52
Secteur public	50	21,64
Secteur privé	49	21,21
TOTAL	231	100

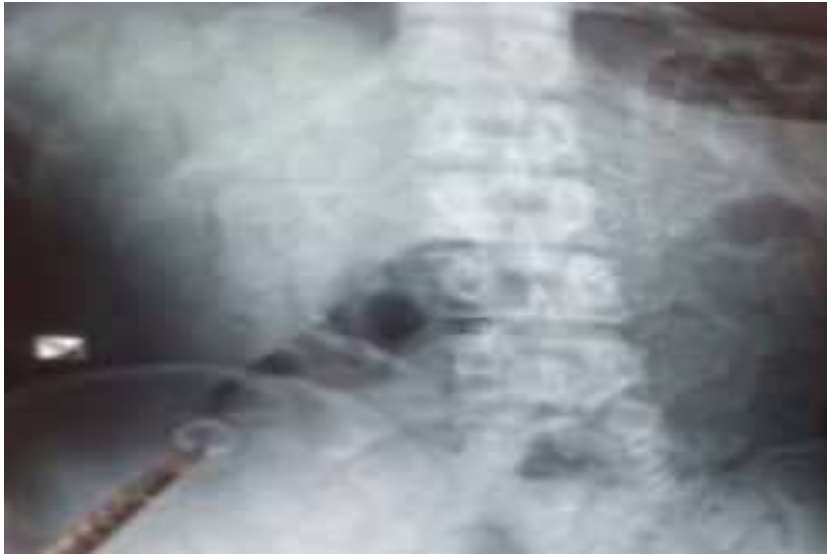

Figure 2: X-ray image showing stercolitis.

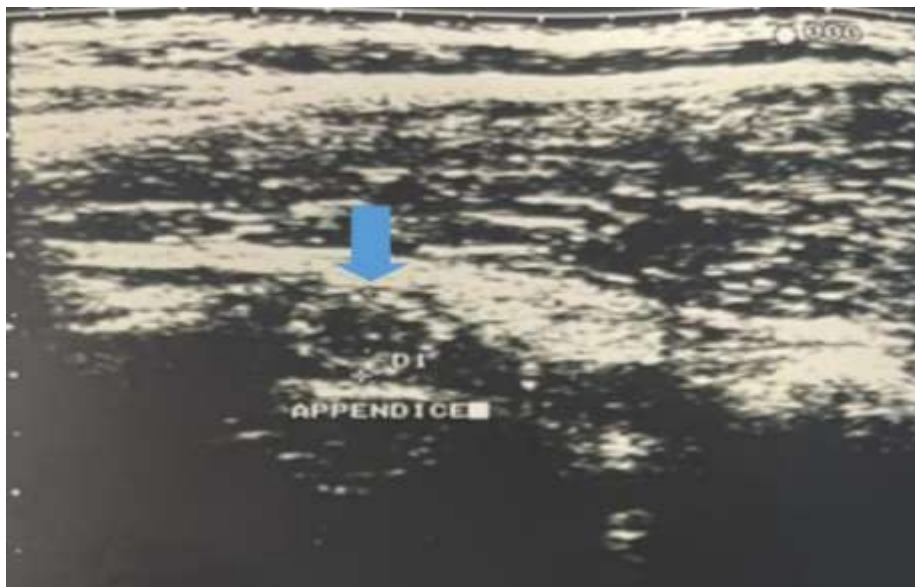


Figure 3: ultrasound image of an enlarged appendix (blue arrow)



Figure 4: image showing Mac Burney approach

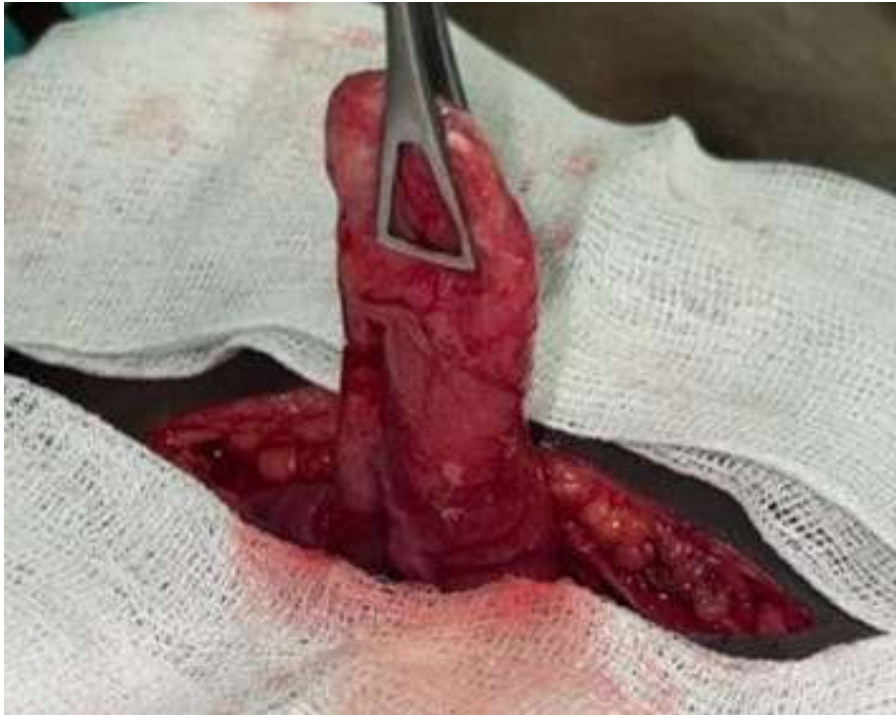

Figure 5: Intraoperative image of the phlegmonous appendix

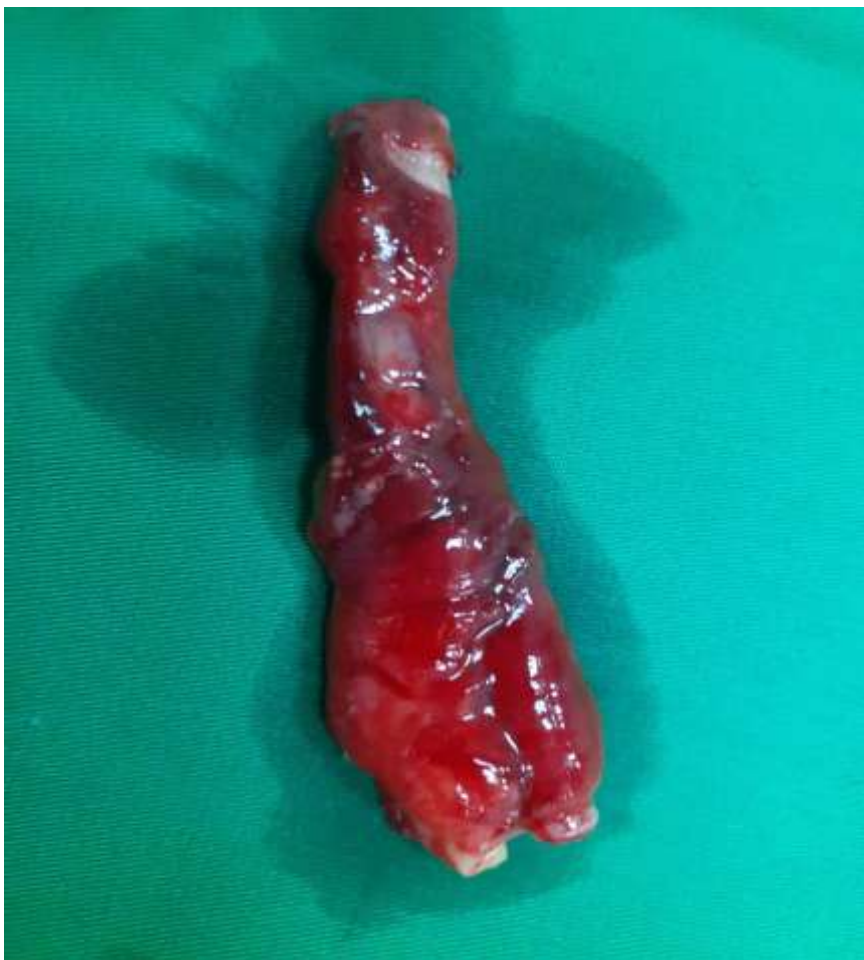

Figure 6: image showing appendectomy specimen